





## Classic Kaposi Sarcoma Presenting with Diffuse Lesions and Secondary Malignancy

 Hanife USTA ATMACA<sup>a</sup>,  
 Feray AKBAŞ<sup>a</sup>,  
 Ezgi GÜNDOĞAR<sup>a</sup>,  
 Mehmet Emin PİŞKINPAŞA<sup>a</sup>

<sup>a</sup>Clinic of Internal Medicine,  
 İstanbul Training and Research Hospital,  
 İstanbul, TURKEY

Received: 03 Apr 2019

Received in revised form: 13 May 2019

Accepted: 13 May 2019

Available online: 16 May 2019

Correspondence:

Hanife USTA ATMACA  
 İstanbul Training and Research Hospital,  
 Clinic of Internal Medicine,  
 İstanbul, TURKEY  
 hanifeusta@yahoo.com

*This study was presented as a poster of the  
 24<sup>th</sup> Education Course of the Faculty of  
 Medicine of Hacettepe University Faculty of  
 Medicine, 01-02 March 2019, Ankara, Turkey.*

**ABSTRACT** Classic Kaposi Sarcoma (CKS) is a vascular neoplasm, which is the most common subtype of sarcoma in our country. The prognosis is usually good. Generally it involves lower extremities, visceral involvement is rarely seen. Secondary malignancy might accompany the disease. Mortality occurs due to accompanying diseases. Here, a geriatric patient who was admitted with upper gastrointestinal bleeding and had diffuse CKS lesions on lower extremities and invasive adenocarcinoma of the stomach is presented. The 94 year-old female patient was presented with hematemesis and melena. She was cachectic, and in poor general condition and had diffuse maculopapular purple lesions on both lower extremities and foot dorsum. The pathological examination revealed Kaposi Sarcoma (KS). Human herpes virus-8 (HHV-8) was negative. A fragile mass was found in gastric corpus in the endoscopy which was performed after recurrent gastrointestinal bleeding. The pathological diagnosis was invasive adenocarcinoma. Despite the ongoing treatment, the bleeding continued and patient's general condition worsened and she died on the 7<sup>th</sup> day of admission. Kaposi sarcoma must be kept in mind when typical skin lesions accompany a malignancy.

**Keywords:** Classic Kaposi sarcoma; adenocarcinoma; malignancy

Kaposi Sarcoma was first described by Moriz Kaposi (Hungarian dermatologist) in 1872.<sup>1</sup> It is a slow-growing tumor that is originated from vascular endothelium and perivascular soft tissue proliferation. It is usually multifocal but generally involves the skin. The neoplasm is a raising concern after 1980s, after it started to appear in Acquired Immune-Deficiency Syndrome (AIDS) patients as epidemics.

There are 4 clinical types: Classic type (common in elderly men in Mid-Asia and Mediterranean), African type (endemic type commonly seen in middle-aged/elderly men), AIDS-related type and iatrogenic type (immunosuppressive drug-related e.g. renal allograft recipients).<sup>2</sup> Classic Kaposi Sarcoma (CKS) which is not related to Human Immune Deficiency Virus (HIV) infection is usually seen in the elderly men in east Europe and Mediterranean countries.<sup>3</sup>

Here; a geriatric patient who was admitted to our hospital with upper gastrointestinal (GI) bleeding and diffuse reddish purple papular lesions and plaques on lower extremities and was diagnosed with a secondary malignancy, is presented.

## CASE REPORT

A 92-year-old female patient was admitted to our clinic with brown vomiting and black defecation which started 24 hours prior to admission. She was in poor general condition, was cachectic and could hardly answer the questions. Her blood pressure was 90/60 mmHg and heart rate was 100/min. Turgor and tonus were significantly decreased. There was no organomegaly. She had multiple scattered violet maculopapular lesions on both lower extremities and foot dorsum and lesions did not blanch with pressure. Fourth finger of left hand had similar lesions, too (Figure 1, 2, 3, 4).

She was admitted to internal medicine clinic with upper GI bleeding. Her laboratory values on admission were as: Hemoglobin 9 gr/dl (N:12-16), Hematocrit (Hct) %28 (N:36-47), MCV 79 fl (N:80-97), urea 133 mg/dl (N:17-43) and creatinine 1.09 mg/dl (N: 0.51-0.95), anti-HIV:(-), anti-HHV-8:(-), HBsAg (-), antiHCV(-). Supportive treatment was started for GI bleeding. Multiple biopsies were taken from the lesions on the legs and arms after the patient was clinically stabilized.

After a partial improvement in her general condition, she had abundant hematemesis on the 3<sup>rd</sup> day after admission. Emergent gastroscopy revealed a fragile mass in corpus. The mass was reported as invasive adenocarcinoma in pathological examination. Active hemorrhage recurred and supportive treatment was continued. On the 7<sup>th</sup> day, the patient died from rapidly progressive clinical deterioration and respiratory failure. Informed written consent was obtained from relatives of the patient outlined in this case.

## DISCUSSION

Kaposi sarcoma is a vascular tumor with a good prognosis. Lesions usually present as reddish purple colored macules, nodules or plaques on lower extremities and rarely on hands. Lesions slowly spread to proximal parts and grow to form bigger plaques and nodules.<sup>4</sup> It is rarely seen in upper extremities and in extreme cases in only visceral organs without skin involvement.<sup>5,6</sup>

In this case, the lesions were generally in lower extremities and also on the hands to a lesser extent. The patient declared that she had those lesions for a long time but her hospital visit was de-

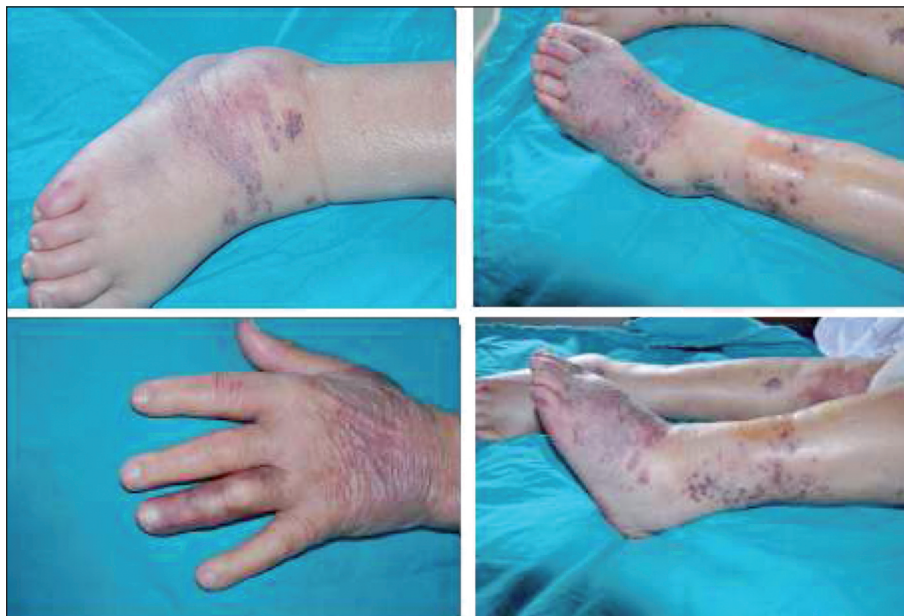

FIGURE 1-4: Multiple scattered violet maculopapular lesions on both lower extremities, foot dorsum and left hand of patient with Kaposi sarcoma.

laid because of her disability and the lesions progressed during this time.

Prolonged disease can cause chronic venous stasis and lymphedema and in elderly patients and these might be misdiagnosed as peripheral vascular disease. Benign vascular lesions like bacillary angiomatosis, angiosarcoma and hemangioma should be considered in differential diagnosis.

Mucosal membranes are rarely involved in CKS but visceral involvement is common.<sup>7,8</sup> Liver, heart, lymph nodes, spleen, lung and bone marrow involvements are reported in different cases.<sup>9</sup> Gastrointestinal system involvement, especially gastric involvement is also reported and it often causes GI bleeding.<sup>9</sup> In our case, gastric adenocarcinoma accompanied the disease and it caused recurrent GI bleeding.

Other malignancies, especially lymphoproliferative diseases can accompany KS and this might be a sign of diverse immunological state in CKS. Non-insulin-dependent diabetes mellitus is also reported as a frequent co-morbidity in KS.<sup>10,11</sup>

Classic Kaposi sarcoma is usually seen in Jewish elderly men with East Europe and Mediterranean origin. It is the most frequent type in our country. Its incidence varies in different populations.<sup>12</sup> Highest incidence is reported in Sardinian Island and Israel (29.2 in a million in men, 19.6 in a million in women).<sup>13</sup> Although we don't have exact epidemiological data, our country is among frequently seen countries, and it is more common in men and at 5<sup>th</sup>-8<sup>th</sup> decade.<sup>14</sup>

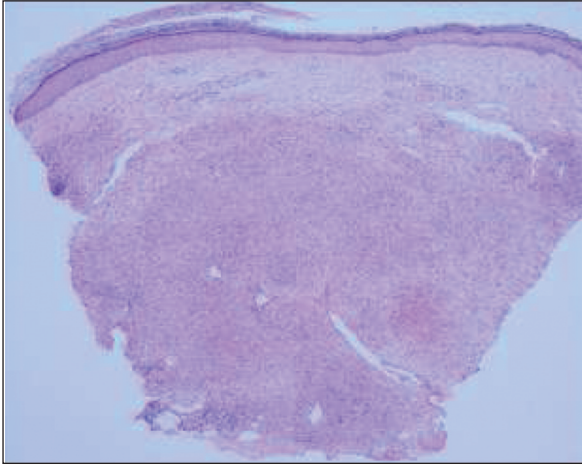
Pathogenesis of KS is not fully understood but all forms are known to be related with HHV-8. Still, only a small percentage of patients who are infected with HHV-8 develops CKS.<sup>15,16</sup> Globally, HHV-8 is seen in different geographic regions which is consistent with KS incidence. Socio-economic status, differences in sexual life choices, host and virus genotypes are considered to cause these geographic differences.<sup>17</sup> Our case was negative for HHV-8 in PCR analysis. It might be a false negative finding as well as exact lack of virus. In some occasions, low virus copy number or polymorphism in HHV-8 primary binding regions, technical errors

like fixation of materials or tissue sampling during biopsy stages, the disappearance of antigenic features of tissue; might prevent the detection of HHV-8 antigen immunohistochemically.<sup>16</sup>

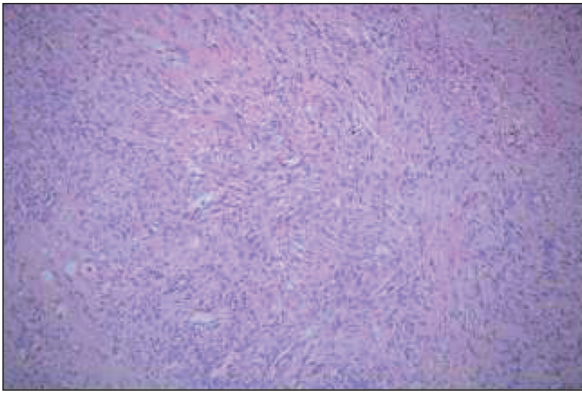
Biopsy is needed for the definitive diagnosis. Typical histological features are observed in standard microscopic evaluation. Also, HHV-8 DNA sequence can be detected by polymerase chain reaction from skin lesions and immunohistochemical staining of biopsy samples to detect the virus. There may be varying degrees of overlying epidermal changes which can range from prominent hyperkeratosis and acanthosis to frank ulceration. The dermal proliferation is comprised of a spindle cell proliferation of endothelial cells forming sinuous vascular spaces. These may be sparse in patch phase lesions, progressing to fascicles of spindle cells in nodular lesions. The spindle cells infiltrate through the collagen, forming slit like spaces, especially towards the periphery of the lesions. In plaque and nodular stage lesions there may be visible intra and extra cellular hyaline globules, thought are present gulped erythrocytes. Rarely, this may be seen in patch stage lesions. They stain PAS positive. The inflammatory infiltrate is predominantly lymphocytic with scattered plasma cells which is considered a sign for the diagnosis. Erythrocytes are seen within the slit like spaces and throughout the tumour.<sup>18,19</sup> Sometimes at the base and periphery of nodular Kaposi there may be large cavernous vessels. Those typical pathological findings were also present in our case (Figure 5, Figure 6).

Classic kaposi sarcoma recurrence is seen very often due to its multifocal nature. It is rarely mortal and mortality usually occurs due to co-morbidities in the elderly patients.<sup>20</sup> In our case, mortality occurred after GI bleeding, with worsening general condition and respiratory distress in the elderly patient.

The aim of treatment is to reduce the tumor size and the severity of symptoms and prevent the progression. In CKS; local (surgery, radiotherapy, in-lesion-injections-vinblastine-, cryotherapy), topical (9-cis-retinoic acid) and systemic treatments can be used alone or in combination. Classic Kaposi



**FIGURE 5:** Spindle cell tumoral infiltration in the dermis below subepidermal Grenz zone (Hematoxylin\_Eosin x40).



**FIGURE 6:** Tumor is formed by spindle cells forming criss-crossing bundles. Erythrocytes are seen between those bundles (Hematoxylin\_Eosin x200).

sarcoma is a radiosensitive tumor and 90% objective response and 70% full response can be obtained.<sup>19</sup> Palliation of pain, bleeding and edema is also 95% achievable.<sup>21-23</sup>

In conclusion; KS must be kept in mind in differential diagnosis when typical skin lesions accompany a malignancy even if the patient is negative for HHV-8 or HIV.

#### **Informed Consent**

Written informed consent was obtained from the patient's next of kin for publication of this case report and any accompanying images. A copy of the written consent is available for review by the Editor-in-Chief of this Journal.

#### **Source of Finance**

During this study, no financial or spiritual support was received neither from any pharmaceutical company that has a direct connection with the research subject, nor from a company that provides or produces medical instruments and materials which may negatively affect the evaluation process of this study.

#### **Conflict of Interest**

No conflicts of interest between the authors and / or family members of the scientific and medical committee members or members of the potential conflicts of interest, counseling, expertise, working conditions, share holding and similar situations in any firm.

#### **Authorship Contributions**

**Idea/Concept:** Hanife Usta Atmaca, Ezgi Gündoğar; **Design:** Hanife Usta Atmaca, Ezgi Gündoğar, Mehmet Emin Piskinpaşa, Feray Akbaş; **Control/Supervision:** Hanife Usta Atmaca, Feray Akbaş; **Data Collection and/or Processing:** Hanife Usta Atmaca, Ezgi Gündoğar; **Analysis and/or Interpretation:** Hanife Usta Atmaca, Ezgi Gündoğar, Feray Akbaş, Mehmet Emin Piskinpaşa; **Literature Review:** Feray Akbaş; **Writing the Article:** Hanife Usta Atmaca; **Critical Review:** Feray Akbaş; **References and Fundings:** Hanife Usta Atmaca, Feray Akbaş; **Materials:** Hanife Usta Atmaca.



## REFERENCES

- Kaposi M. [Idiopathisches multiples pigment sarkom der haut]. *Arch Derm Syph Berl*. 1872;4(2):265-73. [[Crossref](#)]
- Buonaguro FM, Tornesello ML, Buonaguro L, Satriano RA, Ruocco E, Castello G, et al. Kaposi's sarcoma: aetiopathogenesis, histology and clinical features. *J Eur Acad Dermatol Venereol*. 2003;17(2):138-54. [[Crossref](#)] [[PubMed](#)]
- Schwartz RA, Micali G, Nasca MR, Scuderi L. Kaposi sarcoma: a continuing conundrum. *J Am Acad Dermatol*. 2008;59(2):179-206. [[Crossref](#)] [[PubMed](#)]
- Fenig E, Brenner B, Rakowsky E, Lapidoth M, Katz A, Sulkes A. Classic Kaposi sarcoma: experience at Rabin Medical Center in Israel. *Am J Clin Oncol*. 1998;21(5):498-500. [[Crossref](#)] [[PubMed](#)]
- Babuucco O, Kargi E, Hoşnüter M, Doğan BG. [Atypical presentation of Kaposi's sarcoma in the external ear]. *Kulak Burun Bogaz İhtis Derg*. 2003;11(1):17-20.
- Selçuk H, Gür G, Bilezikçi B, Gürsoy M, Arıcan A, Boyacıoğlu S. [Kaposi's sarcoma of the stomach: two cases]. *Turk J Gastroenterol*. 2001;12(3):241-4.
- Wu XJ, Pu XM, Kang XJ, Halifu Y, An CX, Zhang DZ, et al. One hundred and five Kaposi sarcoma patients: a clinical study in Xinjiang, Northwest of China. *J Eur Acad Dermatol Venereol*. 2014;28(11):1545-52. [[Crossref](#)] [[PubMed](#)]
- Brenner B, Weissmann-Brenner A, Rakowsky E, Weltfreund S, Fenig E, Friedman-Birnbaum R, et al. Classical Kaposi sarcoma: prognostic factor analysis of 248 patients. *Cancer*. 2002;95(9):1982-7. [[Crossref](#)] [[PubMed](#)]
- Mohanna S, Ferruffino JC, Sanchez J, Bravo F, Gotuzzo E. Epidemiological and clinical characteristics of classic Kaposi's sarcoma in Peru. *J Am Acad Dermatol*. 2005;53(3):435-41. [[Crossref](#)] [[PubMed](#)]
- Iscovich J, Boffetta P, Winkelmann R, Brennan P. Classic Kaposi's sarcoma as a second primary neoplasm. *Int J Cancer*. 1999;80(2):178-82. [[Crossref](#)]
- Weissmann A, Linn S, Weltfreund S, Friedman-Birnbaum R. Epidemiological study of classic Kaposi's sarcoma: a retrospective review of 125 cases from Northern Israel. *J Eur Acad Dermatol Venereol*. 2000;14(2):91-5. [[Crossref](#)] [[PubMed](#)]
- Errihani H, Berrada N, Raissouni S, Rais F, Mrabti H, Rais G. Classic Kaposi's sarcoma in Morocco: clinico-epidemiological study at the National Institute of Oncology. *BMC Dermatol*. 2011;11:15. [[Crossref](#)] [[PubMed](#)] [[PMC](#)]
- Kaloterakis A, Stratigos J, Trichopoulos D, Karabinis A, Elemenoglou S. Mediterranean Kaposi's sarcoma: preliminary communication about 131 cases. *Bull Soc Pathol Exot Filiales*. 1984;77(4 Pt 2):570-1.
- Gün BD, Bahadır B, Ekem TE, Numanoğlu G, Gün MÖ, Gönülal E, et al. [Classic Kaposi's sarcoma: clinical and immunohistochemical features]. *Turkiye Klinikleri J Dermatol*. 2007;17(1):21-5.
- Su Ö, Onsun N, Arda H, Ümmetoğlu Ö, Pekdemir A. [Clinical features, presence of human herpesvirus-8 and treatment results in classic Kaposi sarcoma]. *Türkderm*. 2008;42:122-6.
- Dilnur P, Katano H, Wang ZH, Osakabe Y, Kudo M, Sata T, et al. Classic type of Kaposi's sarcoma and human herpesvirus 8 infection in Xinjiang, China. *Pathol Int*. 2001;51(11):845-52. [[Crossref](#)] [[PubMed](#)]
- Safai B. Kaposi's sarcoma: a review of the classical and epidemic forms. *Ann N Y Acad Sci*. 1984;437:373-82. [[Crossref](#)] [[PubMed](#)]
- Tiussi RM, Caus AL, Diniz LM, Lucas EA. Kaposi's sarcoma: clinical and pathological aspects in patients seen at the Hospital Universitário Cassiano Antônio Moraes-Vitória-Espírito Santo-Brazil. *An Bras Dermatol*. 2012;87(2):220-7. [[Crossref](#)] [[PubMed](#)]
- Safai B, Miké V, Giraldo G, Beth E, Good RA. Association of Kaposi's sarcoma with second primary malignancies. *Cancer*. 1980;45(6):1472-9. [[Crossref](#)]
- Becker G, Bottke D. Radiotherapy in the management of Kaposi's sarcoma. *Onkologie*. 2006;29(7):329-33. [[Crossref](#)] [[PubMed](#)]
- Brenner B, Rakowsky E, Katz A, Gutman H, Sulkes A, Schacter J, et al. Tailoring treatment for classical Kaposi's sarcoma: comprehensive clinical guidelines. *Int J Oncol*. 1999;14(6):1097-102. [[Crossref](#)] [[PubMed](#)]
- Zurrida S, Bartoli C, Nolé F, Agresti R, Del Prato I, Colleoni M, et al. Classic Kaposi's sarcoma: a review of 90 cases. *J Dermatol*. 1992;19(9):548-52. [[Crossref](#)] [[PubMed](#)]
- Di Lorenzo G, Kreuter A, Di Trollo R, Guarini A, Romano C, Montesarchio V, et al. Activity and safety of pegylated liposomal doxorubicin as first-line therapy in the treatment of non-visceral classic Kaposi's sarcoma: a multicenter study. *J Invest Dermatol*. 2008;128(6):1578-80. [[Crossref](#)] [[PubMed](#)]