

The Treatment of Large Periapical Lesions (Three Years Clinical Evaluation): A Case Report

GENİŞ ÇAPLI PERİAPİKAL LEZYONUN TEDAVİSİ (3 YILLIK TAKİP ÇALIŞMASI): OLGU SUNUMU

Sema ÇELENK*, Buket EROL AYNA*, Behiye SEZGİN BOLGÜL*, Fatma ATAKUL**

* Assis.Prof.Dr., Dicle University Dental Faculty, Department of Pedodontics,

** Prof.Dr., Dicle University Dental Faculty, Department of Pedodontics, DİYARBAKIR, TURKEY

Summary

Purpose: Nowadays, the treatment of large periapical lesions has been performed endodontically.

Case Report: This case report concerns with a 14 year-old girl who had a large periapical lesion in mandibular right and left central and lateral incisors. This study was undertaken to determine the clinical and radiographic success of Ca (OH)₂ and iodoform paste in healing of a large periapical lesion. The root canals were temporarily filled. The patient was recalled for evaluation at intervals of 3 months.

Conclusion: At the end of first year, the root canals were filled permanently. After 3 years follow-up, any symptoms and lesions was not observed in the patient.

Key Words: Endodontic treatment, periapical lesion

Türkiye Klinikleri J Dental Sci 2005, 11:69-72

Özet

Amaç: Günümüzde geniş çaplı periapikal lezyonların tedavisi endodontik olarak yapılmaktadır.

Olgu Sunumu: Bu olgu raporu, mandibulada sağ ve sol santral ve lateral kesici dişlerde geniş çaplı periapikal lezyona sahip 14 yaşındaki bir kız çocuğu ile ilgilidir. Bu çalışma, geniş çaplı bir periapikal lezyonun iyileşmesinde Ca (OH)₂ ve iyodoform pastının başarısını klinik ve radyolojik olarak tespit etmek amacıyla yapılmıştır. Kök kanalları bu patlarla geçici olarak dolduruldu. Hasta üç ay aralıklarla çağrıldı.

Sonuç: Birinci yılın sonunda lezyonun küçüldüğü gözlemlendi ve daimi kök kanal dolgusu yapıldı. Üçüncü yılın sonunda hastada hiçbir semptom ve lezyon gözlenmedi.

Anahtar Kelimeler: Endodontik tedavi, periapikal lezyon

The treatment of large periapical pathologies had been surgically performed in advance. However, it is reported that at present, such lesions have been treated endodontically, and healing of this periapical radiolucencies after nonsurgical endodontic therapy are mostly successful (1,2).

The most common etiologic reasons of periapical lesions are dental caries and trauma. Especially, if treatment is not performed in the early permanent teeth, the progression of caries rapidly increases. As a result, periodontal lesion and pulpal infection take place in the pulp (3).

In conservative treatment of periapical lesions, different canal irrigations and temporary root canal fillings have been generally used. Generally calcium hydroxide (Ca(OH)₂) therapy has been used for the treatment of infected root canals and periapical lesions. Furthermore, Ca(OH)₂ has been

advised as an intracanal medication in endodontic therapy to stimulate apexification, to repair perforations and to treat the root fractures and inflammatory root resorptions (4,5). Ca(OH)₂ is preferred because it induces hard tissue formation and exerts antibacterial and tissue dissolving actions (5). In treatment of periapical lesions, iodoform paste has also been recommended (6). It has been reported that healing and repairing occur when granulation tissue takes place the melt iodoform and Ca(OH)₂ paste (1). Moreover, paste with polyantibiotic in treatment of such lesions has been used (7). In conclusion, the studies shown that these materials used in the treatment of periapical lesions make happen the healing successfully. This study was undertaken to determine the clinical and radiographic success of Ca(OH)₂ and iodoform paste for inhealing of a large periapical lesion.

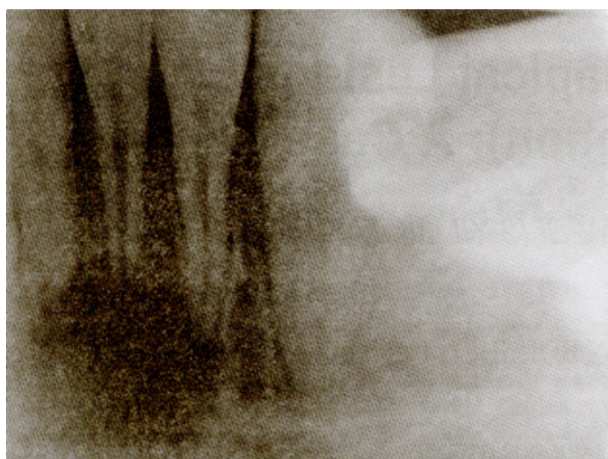


Figure 1. The radiographic diagnosis of case.

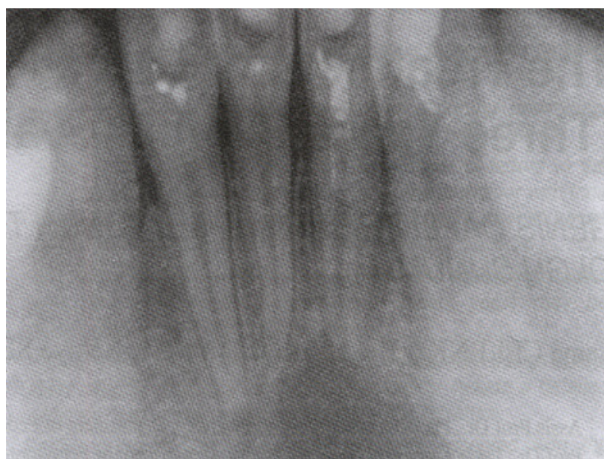

Figure 2. The radiographic evaluation of case (after 3 months).

Case Report

A 14-year-old girl was referred to Department of Pedodontics, Faculty of Dentistry, University of Dicle with a complaint of pain and swelling in mandibular incisors region. The patient had a history of trauma to the lower incisors a year ago. Her main complaint was a spontaneous pain localized only to the mandibular incisors, which increased when chewing. Her general state of health was normal. Clinical examination revealed that there was no response to electric or thermal pulp tests at mandibular right and left central and lateral incisors. Teeth diagnosed had intraoral fistula and sign tenderness to percussion. Radiographic examination demonstrated no evidence of a root fracture but revealed a periapical radiolucency included mandibular right and left central and lateral incisors (Figure 1). During the first visit, rubber dam was applied and access cavities were prepared, thus establishing exudates drainage from the root canals. After the determination of working length, chemomechanical instrumentation (No: 35 file), irrigation with 2.5% solution of sodium hypochlorite, and than drying with sterile paper points were applied. The root canals were filled with calcium hidroxide + iodoform (Vision,USP Germany-Güler Kimya, Turkey). The teeth were sealed with a cotton pellet covered with Cavit (ESPE D-82229 Germany). The patient was returned for recall evaluation at intervals of 3 months for replacement of paste and for

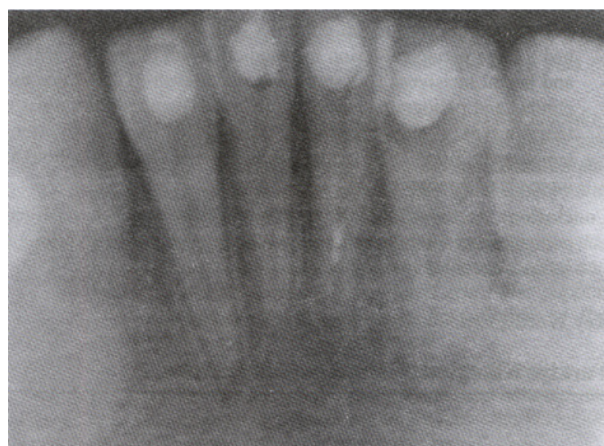


Figure 3. The radiographic evaluation of case at the end of 12 months.

radiographic evaluation (Figure 2). At the end of the 1 year, radiographic examination (with paralel tecniqe) have shown that periapical lesions were healing (Figure 3). The root canals were filled on the same visit with gutta-percha (ROEKO D-89122 Langenau-Germany) and Diaket sealer (ESPE Co. Seefeld Oberbayern, Germany) with a lateral condensation technique (Figure 4). After 3 years follow-up, any symptoms and lesions was not observed in the patient (Figure 5).

Discussion

Nowadays, in modern endodontic treatment, treatment of large periapical lesions without surgical process has been performed. Generally, there is a need for histopathological investigation since

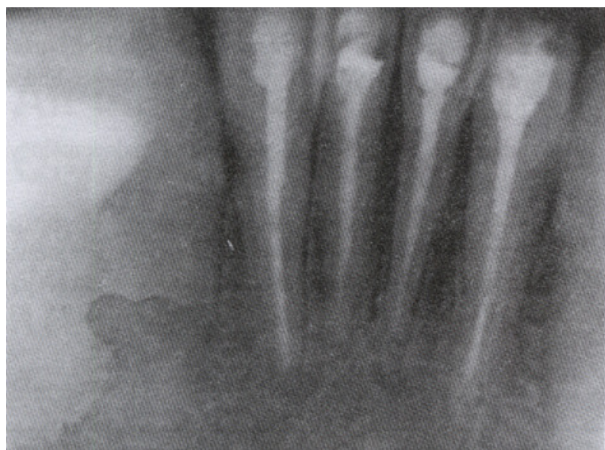

Figure 4. The root canals were filled with gutta percha and diaket sealer at the end of one year.

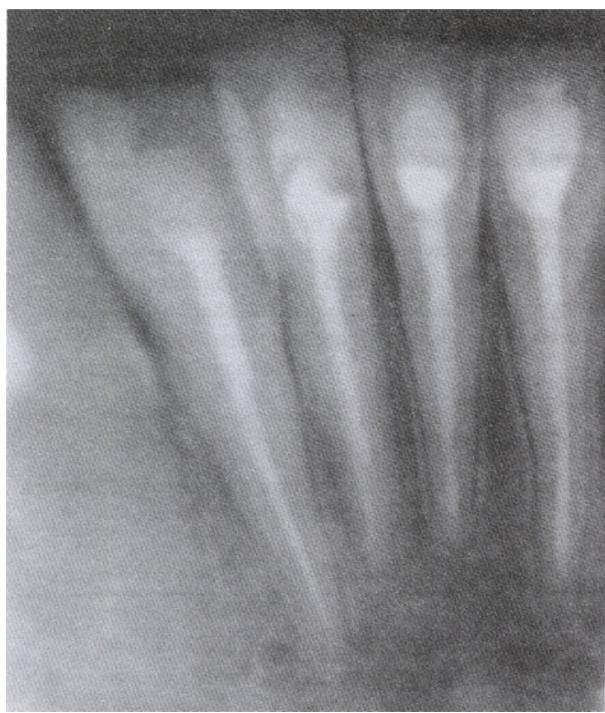

Figure 5. The radiographic evaluation of case at the end of 3 years.

radiography alone is not adequate in diagnosis of large periapical lesions (whether granuloma or cyst). However, distinct diagnosis is not important due to the same treatment of granuloma and cyste as an endodontically.

On the other hand, there are natural limits to the spectrum of cases where conservative treatment is applied. The method will be problematic or

contraindicated if the cyst is extraordinarily expansive. Conservative treatment should never be used in the suspicion of malignancy (8). Moreover, if the patient does not have the time for a relatively extended course of treatment, surgical intervention is indicated.

As a result, we decided that our patient could be treated endodontically in the end of clinical and radiographical evaluation.

When endodontic treatment is performed, radiographic evaluation of the periapical lesion is often used to determine the success of the treatment (9). Coolidge and Kesel (10) stated the time necessity for resolution of the treated “dental granuloma” varied from 6 months to several years, with recalcification occurring at 6 months in very young persons and up to 5 years in middle-aged adults. Since our patient was young, we also followed-up radiographic evidence of healing after 6 months and full healing observed at the end of the first year. Many researchers have been used mostly Ca(OH)_2 and iodoform paste in treatment of periapical lesions (5,6). However, we should point out once again that other agent(s) may also be used instead of these pastes.

In this study, we used combination of Ca(OH)_2 which has both antiseptical and anti-bacterial features and iodoform paste, too. After 3 months, taking into account the possibility of colouring caused by iodoform paste, we gradually reduced the quantity of iodoform in the following séances.

The information concerning the level of success and rates of post treatment healing after nonsurgical endodontic therapy of periapical radiolucencies is limited. Recently, the presence and the rate of certain immune cells and cytokines in the development of pulpal and periapical diseases have been mostly investigated (11).

Therefore, as a result we are in the opinion that much longer follows-up which demonstrate healing of periapical radiolucencies should be conducted after the nonsurgical endodontic treatment.

REFERENCES

1. Bayırlı G: Periapikal dokuların patolojisi ve tedavileri. İstanbul, İ.Ü. Basımevi, 1996, s.125-81
2. Hovland EJ: Medications and temporaries in endodontic treatment. Dent Clin North Am 36: 343,1992
3. Kettering JD, Torabinejad M, Jones SL: Spesificity of antiboides present in human periapical lesions. J Endod 17: 213, 1991
4. Milosevic A: Calcium hidroxide in restorative dentistry. J Dent 19: 3, 1991
5. Foreman AC, Barnes IE: A review of calcium hydroxide. Int Endod J 23: 283, 1990
6. Bayırlı G: Pratik endodonti. İstanbul, İ.Ü. Basımevi, 1990, s.188-241
7. Schroeder A: Endodontics-science and practice. Chicago, Quintessence Publishing Co Inc, 1981,p.235-9
8. Smulson MH, Hagen JC, Ellenz SJ: Pulpoperiapical pathology and immunologic considerations. In: Weine FS, ed. Endodontic Therapy. 5th ed. Saint Louis: Mosby, 1996, p.166-202
9. Walter K, George E, William K, Neil R: Healing of periapikal radiolucencies after nonsurgical endodontic therapy. Oral Surg Oral Med Oral Pathol Oral Radiol Endod 71: 620, 1991
10. Coolidge ED, Kesel RG: A textbook of endodontology. Philadephia, Lea-Febiger, 1956, p.289
11. George T, Huang J, Michael DO, Wingard M, Jin S, Chugal N: Effect of interleukin-6 defieny on the formation of periapical lesions after pulp exposure in mice. Oral Surg Oral Med Oral Pathol Oral Radiol Endod 92: 83, 2001

Received: 03.11.2004**Accepted:** 07.06.2005

Correspondence: Sema ÇELENK, MD
Dicle University, Dental Faculty,
Department of Pedodontics,
DİYARBAKIR, TURKEY
buketayna@hotmail.com