

Widespread Colonization of *Mucor circinelloides* in a Patient with Type 2 Diabetes and Colon Cancer: Case Report

Tip 2 Diyabeti ve Kolon Kanseri Olan Bir Hastada Yaygın *Mucor circinelloides* Kolonizasyonu

Merve AYDIN KARAN,^a
Özlem GÜZEL TUNÇCAN,^b
Ayşe KALKANCI,^c
Dilek ARMAN,^b
Semra KUŞTİMUR^c

^aDepartment of Medical Microbiology,
Erzincan University Faculty of Medicine,
Erzincan

Departments of

^bInfectious Diseases,

^cMedical Microbiology,
Gazi University Faculty of Medicine,
Ankara

Geliş Tarihi/Received: 15.01.2013

Kabul Tarihi/Accepted: 28.09.2013

Yazışma Adresi/Correspondence:

Merve AYDIN KARAN
Erzincan University Faculty of Medicine,
Department of Medical Microbiology,
Erzincan,
TÜRKİYE/TURKEY
mervegazi@yahoo.com.tr

ABSTRACT A case of widespread colonization with *Mucor circinelloides* in a diabetic patient who had a history of colon cancer was presented. A 49-year-old male patient, admitted to our hospital with the complaints of fever, cough, sputum. He was diagnosed to have pneumonia based on the clinical, radiological and laboratory findings and empirical antibiotic treatment was initiated. Potassium hydroxide mount of sputum yielded aseptate hyphae and mold grown in the sputum and stool culture. On the basis of microscopic features, the fungus was identified as *Mucor* spp. The isolate was confirmed as *Mucor circinelloides* by sequencing of the Internal transcribed spacer (ITS) regions of the rDNA gene. Thorax and paranasal sinus computed tomography findings were not compatible with fungal infection. The patient died on the 21st day of hospitalization and no autopsy was performed. As the patient was not compatible with systemic mucormycosis, he was accepted as a case of widespread colonization with *Mucor* spp.

Key Words: Sequence analysis, DNA; colonic neoplasms; mucor

ÖZET Kolon kanseri tanısı alan diabetik hastanın *Mucor circinelloides* ile yaygın kolonizasyon olgusu sunulmuştur. 49 yaşında erkek hasta, öksürük, ateş, balgam şikayetleriyle hastanemize başvurmuştur. Hastaya pnömoni tanısı klinik, radyolojik ve laboratuvar bulgularıyla konulmuştur. Balgamın potasyum hidroksit ile incelemesinde septasız hif görülmüş olup, balgam ve gaita kültüründe küf mantarı üremiştir. Küf mantarı mikroskopik morfolojisine göre *Mucor* spp. olarak teşhis edilmiştir. Etken, rDNA gen üzerindeki Internal transcribed spacer (ITS) bölgesinin dizi analizi ile *Mucor circinelloides* olarak tanımlanmıştır. Toraks ve paranasal sinus tomografi bulguları fungal enfeksiyon ile uyumlu bulunmamıştır. Yatışının 21. gününde hasta kaybedilmiş, otopsi yapılamamıştır. Hasta, sistemik mukormikoz ile uyumlu olmaması nedeniyle *Mucor* spp. ile yaygın kolonize olgu olarak kabul edilmiştir.

Anahtar Kelimeler: Dizi analizi, DNA; kolon tümörleri; mukor

Türkiye Klinikleri J Case Rep 2014;22(3):186-90

Zygomycosis (Mucormycosis) is a rare but highly invasive infection caused by fungi belonging to the order Mucorales, which includes the genera *Rhizopus*, *Mucor*, *Rhizomucor*, *Lichtheimia*, *Apophysomyces*, *Saksenaia*, *Cunninghamella*, *Cokeromyces* and *Syncephalastrum*.¹⁻³ It is associated with high mortality and debilitating morbidity. Though uncommon, its incidence appears to have increased in recent years.⁴ *Rhizopus* is the most common genus causing human infections in most case series, followed by genera such as *Mucor* and *Lichtheimia*, accounting for 70 to 80% of all zygomycosis cases.^{5,6} The other genera including, *Lichtheimia*,

Apophysomyces, *Saksenaea*, *Cunninghamella*, *Cokeromyces*, and *Syncephalastrum* have been reported rarely in the literature.^{7,8}

These ubiquitous, mainly thermotolerant moulds can be found in soil and decomposing organic matter.^{2,9} Their spores are transmitted by inhalation, ingestion, or percutaneously.^{10,11} Healthy people are rarely affected and immunocompromised patients are primarily under risk. The type, extent and severity of the disease depend on the host defences and different risk factors.² The risk factors for developing Zygomycosis include uncontrolled diabetes mellitus, ketoacidosis, severe burns, haematological malignancies (particularly during neutropenia), receiving chemotherapy, hyperalimentation, severe malnutrition, corticosteroid therapy, desferoxamine therapy for iron or aluminium overload and receipt of solid or haematopoietic stem cell transplant.^{2,12-14} The manifestations of disease have also evolved from primarily rhinocerebral, pulmonary and disseminated disease to include gastrointestinal, cutaneous/subcutaneous, allergic disease, and even asymptomatic colonization.^{7,15}

We describe a case of widespread colonization of respiratory and gastrointestinal tracts with *Mucor circinelloides* in a diabetic patient who had a history of colon cancer.

CASE REPORT

A 49-year-old male patient, who had been diagnosed with colon cancer in February 2011, was hospitalized at Department of Infectious Diseases of Gazi University Medical School in November 2011 for the treatment of pneumonia. He was diagnosed with type 2 diabetes mellitus in March 2011 and insulin treatment was initiated. The patient received the last dose of chemotherapy in October 2011. Ciprofloxacin and metronidazole were started for treating diarrhea which developed during pneumonia. He wasn't neutropenic. The leukocyte count was 19.730 cells/mm³ with 96% neutrophils.

On the 4th day after admission, he developed hypoxia and cough with sputum production. Fungal hypha was observed on the microscopic exam-

ination of the sputum material prepared by 10% of potassium hydroxide (Figure 1), as later confirmed by mycological culture. A fast-growing mold grew from the sputum material on Sabouraud dextrose agar. He developed abdominal cramps and diarrhoea. Stool examinations were performed and culture of the stool specimen showed heavy growth of mold. Repeated sputum and stool cultures revealed the morphologically same mold. Amphotericin B was added to the treatment regimen upon the mold growth in sputum and stool samples. Serum galactomannan antigen was measured by means of EIA (Platelia Aspergillus EIA; Bio-Rad) according to the manufacturer's instructions and was found to be negative.

Culture of both sputum and stool specimens at 30°C on Sabouraud dextrose agar yielded a fast-growing fungus that formed white cottony colonies up to 6 mm in height and which became greyish brown as sporulation occurred. The fungus grew well at 37°C but failed to grow at 40°C. Microscopic examination of the growth by lactophenol cotton blue staining showed the absence of stolons, apophysis and rhizoids. The sporangioophores were either tall or short and most were sympodially branched. The sporangia were globose, with finely roughened

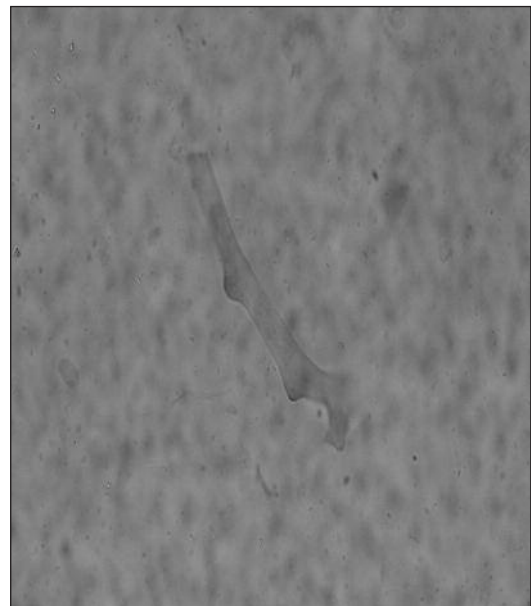


FIGURE 1: Microscopic examination of a sputum material revealed broad, irregular, nonseptate, fungal hyphae.

walls, ranged in size from 35 to 67 μm in diameter. Sporangiospores were hyaline and ellipsoidal to slightly asymmetrical or obovoidal, and measured 5.5 to 7 μm long and 3.5 to 5.5 μm wide (Figure 2). Due to the aforementioned characteristics, the fungus was tentatively identified as *Mucor* spp.

Computed tomography of the thorax demonstrated pulmonary lesions compatible with metastasis but incompatible with fungal infection. In addition, paranasal sinus computed tomography findings were not indicative of any invasive fungal disease. The source of fungal infection was not detected in this case.

On the 7th day of Amphotericin B therapy, the patient was intubated due to hypoxia and severe respiratory complaints. Linezolid treatment was added due to septic shock. The patient died on the 21st day of hospitalization and no autopsy was performed. These findings were not compatible with systemic mucormycosis. Therefore, the patient was accepted as a case of widespread colonization with *Mucor* spp.

DNA sequencing has been carried out retrospectively in order to confirm and identify the mold on species level. Genomic DNA was extracted from the mold colony isolated on SDA plates. DNA extraction was performed by the standard phenol-chloroform-isoamyl alcohol extraction method. Internal Transcribed Spacer (ITS) region of the ribosomal DNA (rDNA) were amplified using primers ITS1 (5'-TCC GTA GGT GAA CGT GCG G-3') and ITS4 (5'-TCC TCC GCT TAT TGA TAT GC-3'). PCR products were purified using ExoSAP-IT PCR-clean up kit (USB, USA) following the manufacturer's directions. Purified DNA fragments were quantified using NANO DROP[®] ND-1000 spectrophotometer (Thermo Fisher Scientific, USA). Both strands of amplified DNA were sequenced by the BigDye terminator cycle sequencing ready reaction kit, version 3.1 (Applied Biosystems, USA) with primers ITS1 and ITS4. Labeled DNA was repurified by Sephadex G-50 (Sigma, USA). The reaction products were analyzed on an ABI 310 Genetic Analyzer (Applied Biosystems, USA).

The assembled DNA sequences were examined using the Basic BLAST (nucleotide-nucleotide) software of the National Center for Biotechnology In-

formation web database (<http://www.blast.ncbi.nlm.nih.gov/Blast.cgi>). The DNA sequence of the 600-bp PCR product of the etiologic strain was 99% identical (423 of 424 bases) with the *Mucor circinelloides* reference strain (CNRMA 04.805, GenBank accession no. DQ118990.1) sequences deposited in GenBank. The genotypic identification was supported by thermotolerance, our isolate grew well at 37° C which is characteristic of *Mucor circinelloides*.

DISCUSSION

Zygomycosis (Mucormycosis) is an opportunistic and fulminant, fungal infection caused by a member of the class Zygomycetes.^{13,16} Although zygomycosis has historically been considered a rare disease, it has emerged as an increasingly important pathogen during the past decade.¹⁷ It is the third most common invasive fungal infection, following aspergillosis and candidiasis and mortality rate ranging from 23 to 100%.^{2,3,18} Patients with diabetes, malignancies, solid organ or bone marrow transplants, or iron overload and those receiving immunosuppressive agents, deferoxamine therapy are at highest risk for zygomycosis.¹³ Because of high mortality rate (75-95%, depending on the form of the zygomycosis) and the fact that these fungi display intrinsic resistance to the most widely

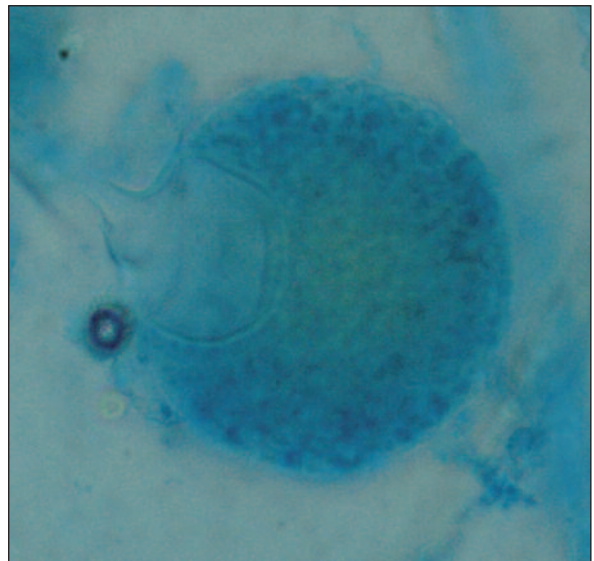


FIGURE 2: Microscopic features of the *Mucor circinelloides* on SDA after 6 days at 30°C, showing columella, sporangium and sporangiospores (lactophenol cotton blue mount preparation; original magnification, X40).

used antifungal drugs, accurate diagnosis in early phase of the infection is essential for a successful treatment of zygomycosis.⁹

Growth of Zygomycetes in culture may not represent clinically significant invasive disease.⁷ However, isolation of Zygomycetes from a sterile site or repeated positive cultures of the fungi from a nonsterile site is considered significant in a high-risk patient with predisposing factors for acquisition of zygomycosis. Positive cultures from nonsterile specimens should be interpreted with caution and will require correlation between the finding and the clinical situation.¹⁹

Identification of the Zygomycetes at the genus and species levels requires culture studies; however, in a high proportion of cases, cultures do not yield a fungus. Cultures are negative in about 50% of cases of zygomycosis, including all sites of infection.¹⁷ Zygomycetes appear as irregular, large, non-septate hyphae by histopathology or direct examination.¹⁹ However, it is not possible to make more precise identification to species, or even to genus, level based on morphology in tissues. Furthermore, differentiation between a Zygomycetes and another hyalohyphomycetes may be difficult by histopathology or direct examination.²⁰

The diagnosis of zygomycosis is very challenging: most such infections are identified only as zygomycosis, without species or at least genus determination.⁷ The classical method of identification of Zygomycetes involves phenotypic identification based mainly on morphological characteristics. However, identification by morphology is difficult and time-consuming and sometimes needs the expertise of a reference laboratory.²¹

To overcome this limitation, molecular techniques are now being increasingly applied to identify Zygomycetes in grown cultures and tissue samples. The molecular identification of clinical Zygomycetes using the ITS region has been successfully used in recent years.^{18,22-25} Iwan et al reported a case of primer cutaneous Zygomycosis due to *M.circinelloides* with a history of myelodysplastic syndrome and diabetes. The histopathology showed hyphae typical of a Zygomycetes and cul-

ture yielded a fungus identified as a *Mucor* species. Identification as *M.circinelloides* was suggested by morphological characteristics and confirmed by comparison of an ITS sequences which aligned with 98% similarity to multiple sequences of *M.circinelloides*.²³

In Turkish literature, the sequence-based molecular confirmation of the etiologic agent was performed only in four cases including the current case.^{18,24,25} The first was described in 2006, a histologically and mycologically proven sinonasal mucormycosis case causing palatal necrosis in a nondiabetic patient with renal failure. The fungus was isolated from surgical specimens and identified as *Rhizopus oryzae* by phenotypic and genotypic tests.²⁴ The second was reported in 2009, a case of fungemia and cutaneous mucormycosis cause due to *Mucor circinelloides* in a neurological intensive care unit patient with diabetes mellitus. The diagnosis was made based on the growth of fungi in the blood, skin biopsy cultures and histopathologic examination of the skin biopsy.²⁵ The third case was an acute lymphoblastic leukemia patient who had rhino-orbital mucormycosis caused by *Rhizopus oryzae*. The diagnosis was made with endoscopic appearance, computerized tomography of the paranasal sinuses, and culture of the surgical materials.¹⁸

Identification of etiological agent to species level is necessary for better clinical outcome because of different susceptibility patterns of the Mucorales.²⁶ It has been reported that *Rhizopus* spp. are significantly less susceptible to itraconazole, posaconazole, terbinafine, and amphotericin B than *Lichtheimia* spp., and less susceptible than *Mucor* spp. to amphotericin B. *Rhizopus microsporus* appears to be more susceptible to terbinafine than *Rhizopus oryzae*.²⁷

In conclusion, the identification of Zygomycete species on morphological features alone is difficult, time consuming. The importance of zygomycosis as an emerging infectious disease in compromised patients enhances the need for better methods to diagnose and treat this condition. This study has demonstrated that ITS sequencing can be a useful tool in the identification of the most common clinically significant species of Zygomycetes.

REFERENCES

- Iwen PC, Thapa I, Bastola D. Review of methods for the identification of zygomycetes with an emphasis on advances in molecular diagnostics. *Lab Med* 2011;42(5):260-6.
- Barr A, Nolan M, Grant W, Costello C, Petrou MA. Rhinoorbital and pulmonary zygomycosis post pulmonary aspergilloma in a patient with chronic lymphocytic leukaemia. *Acta Biomed* 2006;77(Suppl 4):13-8.
- Severo CB, Guazzelli LS, Severo LC. Chapter 7: zygomycosis. *J Bras Pneumol* 2010;36(1):134-41.
- Muqetadnan M, Rahman A, Amer S, Nusrat S, Hassan S, Hashmi S. Pulmonary mucormycosis: an emerging infection. *Case Rep Pulmonol* 2012;2012:120809.
- Diwakar A, Dewan RK, Chowdhary A, Randhawa HS, Khanna G, Gaur SN. Zygomycosis-a case report and overview of the disease in India. *Mycoses* 2007;50(4):247-54.
- Gomes MZ, Lewis RE, Kontoyiannis DP. Mucormycosis caused by unusual mucormycetes, non-Rhizopus, -Mucor, and -Lichtheimia species. *Clin Microbiol Rev* 2011;24(2):411-45.
- Ribes JA, Vanover-Sams CL, Baker DJ. Zygomycetes in human disease. *Clin Microbiol Rev* 2000;13(2):236-301.
- Baradkar VP, Mathur M, Panda M, Kumar S. Sino-orbital infection by syncephalastrum racemosum in chronic hepatorenal disease. *J Oral Maxillofac Pathol* 2008;12(1):45-7.
- Kontoyiannis DP, Lewis RE. Invasive zygomycosis: update on pathogenesis, clinical manifestations, and management. *Infect Dis Clin North Am* 2006;20(3):581-607, vi.
- Sellappan B, Bakhshi S, Safaya R, Gupta AK, Arya LS. Invasive colonic mucormycosis in early induction therapy of childhood acute lymphoblastic leukemia. *Indian J Pediatr* 2005;72(1):77-9.
- Auxiliadora-Martins M, Alkimm-Teixeira GC, Machado-Viana J, Nicolini EA, Martins-Filho OA, Bellissimo-Rodrigues F, et al. Meningoencephalitis caused by a zygomycete fungus (*Basidiobolus*) associated with septic shock in an immunocompetent patient: 1-year follow-up after treatment. *Braz J Med Biol Res* 2010;43(8):794-8.
- Önal Ö, Hasdıraz L, Oğuzkaya F. [Mycotic infections of the lung: mucormycosis]. *Türkiye Klinikleri J Thor Surg-Special Topics* 2012;5(1):134-40.
- Chayakuakeere M, Ghannoum MA, Perfect JR. Zygomycosis: the re-emerging fungal infection. *Eur J Clin Microbiol Infect Dis* 2006;25(4):215-29.
- Ibrahim AS, Edwards JE, Filler SG. Zygomycoses. In: Dismukes WE, Pappas PG, Sobel JD, eds. *Clinical Mycology*. 1st ed. New York, NY: Oxford University Press: 2003. p.241-51.
- Choi HL, Shin YM, Lee KM, Choe KH, Jeon HJ, Sung RH, et al. Bowel infarction due to intestinal mucormycosis in an immunocompetent patient. *J Korean Surg Soc* 2012;83(5):325-9.
- Kontoyiannis DP, Lewis RE. How I treat mucormycosis. *Blood* 2011;118(5):1216-24.
- Roden MM, Zaoutis TE, Buchanan WL, Knudsen TA, Sarkisova TA, Schaufele RL, et al. Epidemiology and outcome of zygomycosis: a review of 929 reported cases. *Clin Infect Dis* 2005;41(5):634-53.
- Gumral R, Yildizoglu U, Saracli MA, Kapitan K, Tosun F, Yildiran ST. A case of rhinoorbital mucormycosis in a leukemic patient with a literature review from Turkey. *Mycopathologia* 2011;172(5):397-405.
- Lass-Flörl C. Zygomycosis: conventional laboratory diagnosis. *Clin Microbiol Infect* 2009;15(Suppl 5):60-5.
- Chamilos G, Marom EM, Lewis RE, Lionakis MS, Kontoyiannis DP. Predictors of pulmonary zygomycosis versus invasive pulmonary aspergillosis in patients with cancer. *Clin Infect Dis* 2005;41(1):60-6.
- Dannaoui E. Molecular tools for identification of Zygomycetes and the diagnosis of zygomycosis. *Clin Microbiol Infect* 2009;15(Suppl 5):66-70.
- Galgóczy L. Molecular characterization of opportunistic pathogenic Zygomycetes. *Acta Biol Szeged* 2005;49(3-4):1-7.
- Iwen PC, Sigler L, Noel RK, Freifeld AG. *Mucor circinelloides* was identified by molecular methods as a cause of primary cutaneous zygomycosis. *J Clin Microbiol* 2007;45(2):636-40.
- Kantarcioglu AS, Yücel A, Nagao K, Sato T, Inci E, Oğreden S, et al. A *Rhizopus oryzae* strain isolated from resected bone and soft tissue specimens from a sinonasal and palatal mucormycosis case. Report of a case and in vitro experiments of yeastlike cell development. *Med Mycol* 2006;44(6):515-21.
- Dizbay M, Adisen E, Kustimur S, Sari N, Cengiz B, Yalcin B, et al. Fungemia and cutaneous zygomycosis due to *Mucor circinelloides* in an intensive care unit patient: case report and review of literature. *Jpn J Infect Dis* 2009;62(2):146-8.
- Schwarz P, Bretagne S, Gantier JC, Garcia-Hermoso D, Lortholary O, Dromer F, et al. Molecular identification of zygomycetes from culture and experimentally infected tissues. *J Clin Microbiol* 2006;44(2):340-9.
- Dannaoui E, Meletiadiis J, Mouton JW, Meis JF, Verweij PE; Eurofung Network. In vitro susceptibilities of zygomycetes to conventional and new antifungals. *J Antimicrob Chemother* 2003;51(1):45-52.