

Massive Mobile Thrombus in the Right Heart Chambers and Ensuing Massive Pulmonary Embolism Due to Migration of This Thrombus: Original Image

Kalbin Sağ Boşluklarında Masif Mobil Trombüs ve Bu Trombüsün Göç Etmesiyle Oluşan Masif Pulmoner Emboli

Abdurrahman EKŞİK,^a
 Mehmet GÜL,^a
 Selahattin TUREN,^a
 Mustafa DİKER^b

^aClinic of Cardiology,
 İstanbul Mehmet Akif Ersoy Thoracic
 Cardiovascular Surgery
 Training and Research Hospital,

^bClinic of Radiology,
 Haseki Training and Research Hospital,
 İstanbul

Geliş Tarihi/Received: 24.03.2015
 Kabul Tarihi/Accepted: 19.06.2015

Yazışma Adresi/Correspondence:
 Mehmet GÜL
 İstanbul Mehmet Akif Ersoy Thoracic
 Cardiovascular Surgery
 Training and Research Hospital,
 Clinic of Cardiology, İstanbul,
 TÜRKİYE/TURKEY
 drmg23@gmail

Anahtar Kelimeler:

Pulmoner emboli;
 ekokardiyografi

Key Words:

Pulmonary embolism;
 echocardiography

Türkiye Klinikleri J Cardiovasc
 Sci 2015;27(2):76-8

doi: 10.5336/cardiosci.2015-45134

Copyright © 2015 by Türkiye Klinikleri

A 70-year-old male patient with a known history of hypertension, rheumatic heart disease and hemorrhagic stroke was admitted to our hospital with dyspnea and palpitation. His symptoms started 2 days before his admission. On physical examination, he had 2/6 systolic murmur at the apex. Electrocardiography (ECG) revealed atrial fibrillation. Two-dimensional transthoracic echocardiographic examination at apical four chamber and subcostal views showed regular noncalcific mass freely moving at systole and diastole in right atrium (RA) and right ventricle (RV) (Figure 1, 2 and Video 1). Two-dimensional transthoracic echocardiographic examination also revealed rheumatic mitral disease with moderate mitral regurgitation and mitral stenosis and moderate tricuspid regurgitation with dilated RA and RV. Estimated pulmonary artery pressure was measured 70 mmHg with continuous wave Doppler examination. In order to evaluate pulmonary artery embolus computed tomography (CT) scan obtained. Multislice CT scan confirmed bilateral pulmonary emboli (PE) with no thrombus in RV and RA after 2 hours from the admission (Figure 3). On echocardiographic follow up examination this mass was disappeared and dilation in right heart chamber was slightly increased (Figure 4). The patient was not given thrombolytic therapy because of the recent history of hemorrhagic stroke. Patient was started on iv heparin treatment and consulted to cardiovascular surgery immediately for right heart thrombus. While the patient was being prepared to surgery he developed sudden hemodynamic collapse. At that time patient was evaluated for catheter embolectomy but due to his medical condition he could not be taken to catheter laboratory and eventually died.

Pulmonary embolism, occurs as a result of complete or partial blockage of pulmonary arterial bed and is a serious life-threatening cardiopulmonary disease. It occurs as a result of the interaction between the patient and the conditions related risk factors. While predisposing factors related to the patient (age, previous history of PE, congenital or acquired thrombophilia, hormone replacement therapy and oral contraceptive use, active

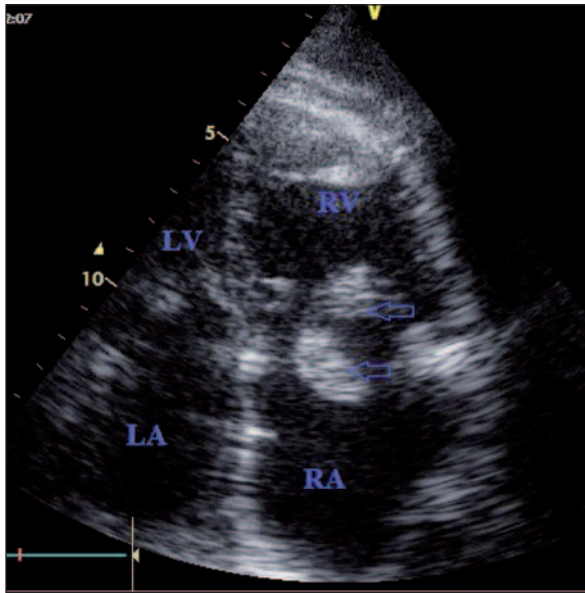


FIGURE 1: Right atrium (RA), right ventricle (RV), left atrium (LA) and left ventricle (LV), are seen in this apical four-chamber view. Thrombus is shown with arrows and extends to both RV and RA.

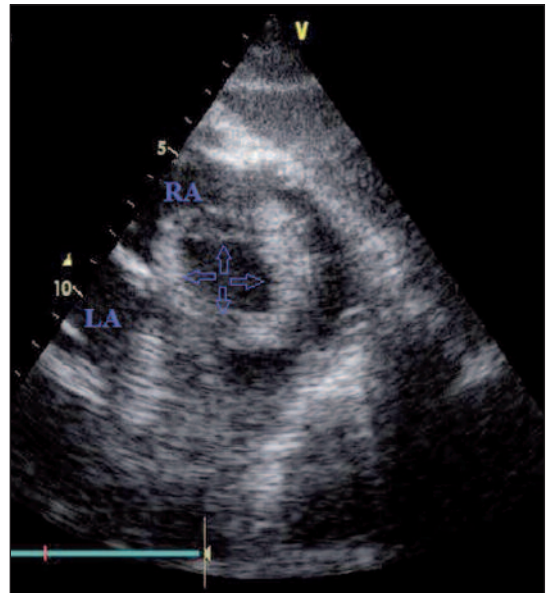


FIGURE 2: Thrombus in right atrium (RA) is shown with arrows in subcostal view image.

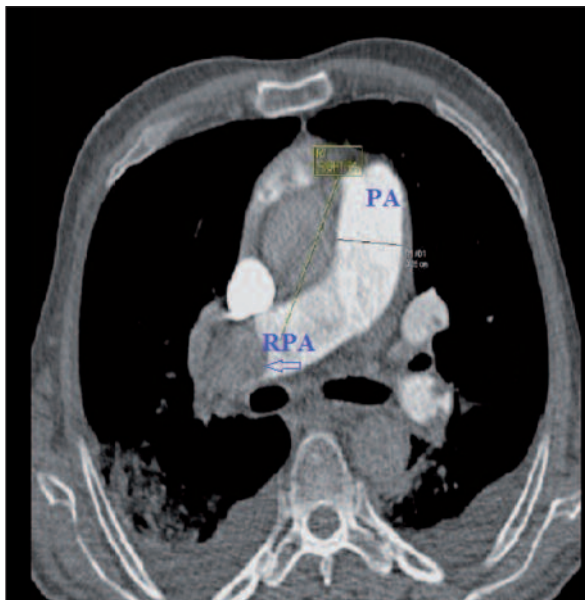


FIGURE 3: Thrombus in the right pulmonary artery (RPA) is shown with an arrow in the multislice CT image. PA: Pulmonary artery.

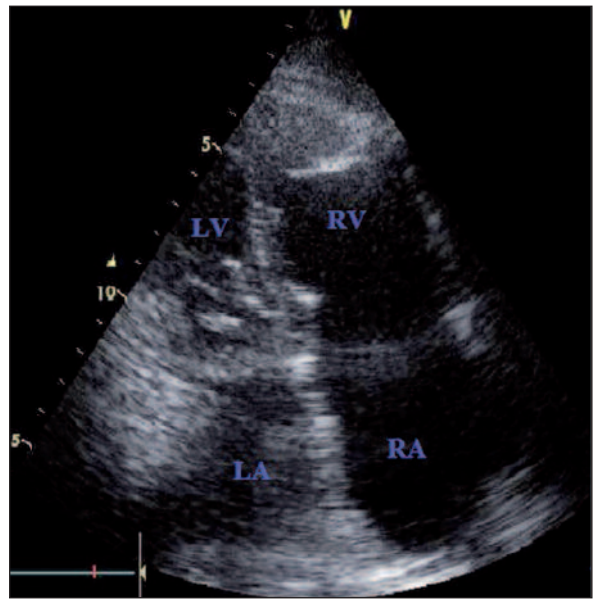


FIGURE 4: Mobile mass in right atrium (RA) and right ventricle (RV) disappeared on follow up assessment.

cancer, limb paresis with neurological diseases, situations requiring bed rest for a long time such as the heart disease or respiratory failure) are usually permanent, predisposing factors related to conditions (hip or leg fractures, surgery, trauma, chemotherapy, pregnancy and postpartum) are

temporary. In our case given the mass in the RV and RA was mobile, myxoma and metastatic cancer was thought in the differential diagnosis. Bilateral lower extremity venous Doppler US revealed right popliteal vein thrombosis. Therefore, we concluded that thrombus in the RA and RV origi-

nated from his deep vein thrombosis. Mobile right heart thrombi are rarely seen in PE patients. Echocardiographic follow up is very helpful in assessment of right heart cavities and proximal pulmonary arteries.¹ Pulmonary embolus patients with right heart cavity thrombus have worse hemodynamic situations than the patients those who do not have and heparin alone treatment associated with higher mortality rate.² In patients with a mobile right heart thrombus, the incidence of PE is 97% and reported mortality is over 44%.³ Investigators have recommended either urgent surgical

treatment or thrombolysis of mobile right heart thrombus.

CONCLUSION

Pulmonary embolism is a common condition and have a high mortality rates with conservative treatment. Especially in massive PE once the diagnosis is made aggressive treatment should be done urgently. Depending on the center's experience and patient suitability thrombus removal with either catheter-based or surgical methods, or thrombolytic therapy should be considered.

REFERENCES

1. Erođlu S, Yildirir A, Simşek V, Müderrisođlu H. [Right atrial mobile thrombus leading to pulmonary embolism]. *Anadolu Kardiyol Derg* 2004;4(3):279-80.
2. Torbiki A, Galié N, Covezzoli A, Rossi E, De Rosa M, Goldhaber SZ; ICOPER Study Group. Right heart thrombi in pulmonary embolism: results from the International Cooperative Pulmonary Embolism Registry. *J Am Coll Cardiol* 2003;41(12):2245-51.
3. Chartier L, Béra J, Delomez M, Asseman P, Beregi JP, Bauchart JJ, et al. Free-floating thrombi in the right heart: diagnosis, management, and prognostic indexes in 38 consecutive patients. *Circulation* 1999;99(21):2779-83.