

Surgical Treatment of Spinal Deformity Due to Ankylosing Spondylitis: Surgical Technique

OMURGA TUTULUMLU ANKİLOZAN SPONDİLİTLİ OLGUDA CERRAHİ TEDAVİ

Hakan ATALAR, MD,^a Esin KAYAOĞLU, MD,^b Aziz ERAKAR, MD,^c Derya DİNÇER, MD^d

^aDepartment of Orthopedic Surgery, Fatih University Faculty of Medicine,

^bDepartment of Orthopedic Surgery, Demetevler Hospital,

^cOrthopedic Surgeon,

^dDepartment of Orthopedic Surgery, Ankara University İbn-i Sina Hospital, ANKARA

Abstract

Ankylosing spondylitis is a chronic inflammatory disease of unknown etiology. As a result of the ossification of the ligaments and joints, the fused vertebrae limit movement and elasticity of the spinal column. A thoracolumbar kyphosis is the most common deformity in ankylosing spondylitis. After conservative treatment has failed, surgical treatment should be considered to reconstruct the sagittal balance. Here we present a 33-year-old male patient with a 12-year history of ankylosing spondylitis and resulting advanced kyphosis, for whom we performed corrective L3 vertebral osteotomy. The high complication rate with this type of surgical intervention is well known. In our patient, complications were encountered in the early postoperative period but long-term results were successful.

Key Words: Spondylitis, ankylosing, therapeutics

Türkiye Klinikleri J Med Sci 2007, 27:132-135

Özet

Ankiloza spondilit, etiolojisi bilinmeyen kronik inflamatuvar bir hastalıktır. Bağların ve eklemlerin ossifikasyonu sonucunda oluşan vertebral füzyon spinal kolonun elastisitesini ve hareketlerini kısıtlar. Torakolomber kifoz ankiloza spondilitte en sık görülen deformitedir. Konservatif tedavinin başarısız kaldığı durumlarda, spinal kolonun sagittal balansını düzeltmek için cerrahi tedavi düşünülmelidir. On iki yıldır ankiloza spondilit tanısı ile izlenen 33 yaşındaki erkek hastaya ileri derecede kifoz nedeniyle düzeltici L3 vertebral osteotomi yapıldı. Bu tür cerrahi girişimlerde komplikasyon oranının fazla olduğu bilinmektedir. Bizim olgumuzda da erken dönemde komplikasyon gelişmeyle birlikte uzun dönemde başarılı sonuç elde edilmiştir.

Anahtar Kelimeler: Ankiloza spondilit, tedavi

Ankylosing spondylitis (AS) is a chronic inflammatory disease of unknown etiology developing at major joints of the spine, hip and shoulder. A fixed thoracolumbar kyphotic deformity causing sagittal imbalance may develop with fusion of the spine, and is the most common spine deformity.¹

Thoracolumbar kyphosis results in a stooped posture. It is difficult for patients to look straight ahead, to sit, to stand up straight or to lie down.² After conservative treatment has failed, surgery may be considered to reconstruct the sagittal balance. This deformity may be corrected by spinal osteotomies.

In this report, we evaluate surgical therapy performed for a patient with advanced spinal deformity due to AS.

A 33-year-old male patient was referred to our clinic with complaints regarding waist and back pain and not being able to look straight ahead. Twelve years before, he had received a diagnosis of AS and used medical and physical therapy. In the last 2 years, his complaints had markedly in-

Geliş Tarihi/Received: 15.08.2005

Kabul Tarihi/Accepted: 07.03.2006

Yazışma Adresi/Correspondence: Hakan ATALAR, MD
Fatih University Faculty of Medicine,
Department of Orthopaedic Surgery,
ANKARA
atalarhakan@yahoo.com

Copyright © 2007 by Türkiye Klinikleri

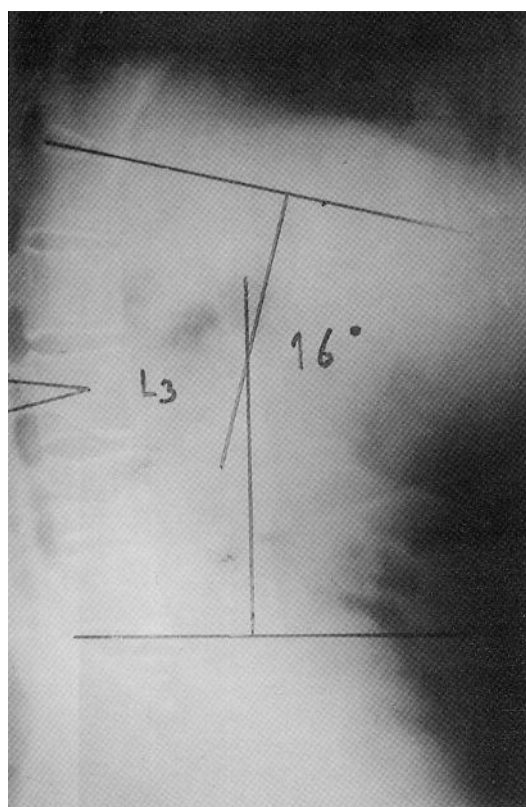


Figure 1. Preoperative lateral lumbar X-rays showed loss of lumbar lordosis. The patient's L₁-L₅ vertebrae angle showed 16 degrees of kyphosis.

creased. Preoperatively, the patient's L₁-L₅ vertebrae angle showed 16 degrees of kyphosis (Figure 1). Surgical release of T₁₂-L₄ was performed via an anterior approach, and with the patient still under anesthesia, through a posterior approach, a wedge osteotomy was performed on the L₃ vertebra, and corrective fixation of the spinal column with allograft was achieved with posterior instrumentation (Figure 2). Monosegmental lordization at L₃ provided a correction of 44 degrees, resulting in an angle of 28 degrees lordosis. On postoperative day 2, the patient was mobilized with a thoracolumbar corset. After 6 weeks, one of the L₅ screws pulled out and revision surgery was performed. During the third postoperative week, the peroneal branch of the left sciatic nerve was injured during an intramuscular injection of analgesic. This problem completely resolved 1 year later. In the graphics taken on postoperative month 7, a posterior fusion mass was observed (Figure 3). Correction of the patient's posture was apparent on inspection (Fig-

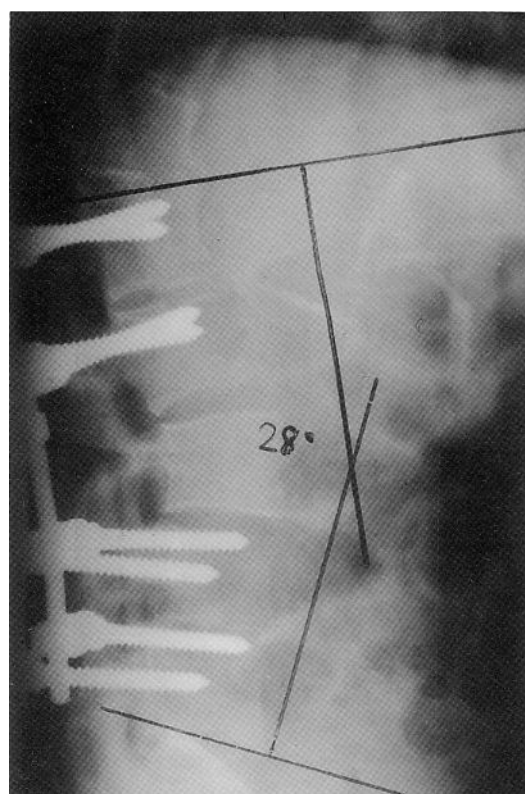


Figure 2. Through the use of a closed wedge osteotomy in L₃, posterior instrumentation was placed from L₁ to L₅.

ures 4 a,b and 5 a,b). After that time, corset use was tapered to zero over a period of three months.

A primary problem of kyphotic deformity in AS is bent trunk. The sagittal imbalance of the spine per degree of kyphosis is greater the more caudal the deformity lies, because the proximal spine acts as a longer lever. Surgical lordization therefore should be carried out as far caudal as possible. There are various surgical techniques for correction of thoracolumbar kyphosis in AS.² In Smith-Peterson's anterior opening wedge osteotomy, at levels above L₂₋₃ or in older patients with reduced arterial elasticity, the rates of major vascular complications was high due to violent elongation of the anterior column.³ In Zielke's polysegmental osteotomy, part of the posterior elements of each vertebra are resected and the spine is shortened posteriorly at 4 to 7 levels for lordization.⁴ Although this procedure is less risky, it may result with insufficient correction if intervertebral discs

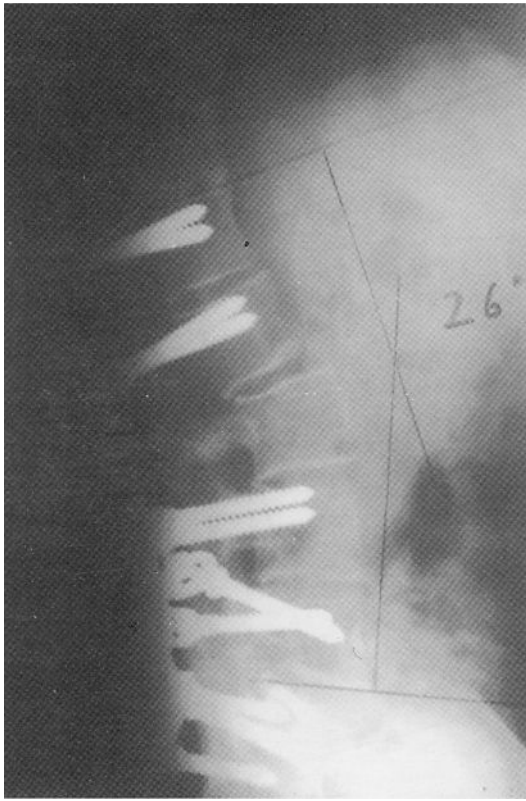


Figure 3. At postoperative month 7, lateral lumbar X-rays showed a posterior fusion mass at L₃. Besides, a 2-degree decrease in the angle of lordosis was detected.

are too stiff to be opened up anteriorly after resection of the corresponding posterior elements.

Thomassen's transpedicular closing wedge vertebral osteotomy is safer and more effective than the other two techniques.⁵ In this technique, the pivot point is shifted from the posterior edge to the center of the vertebral body, thus preventing a large ventral gap that can cause serious complications. However, it has a potential risk of neurological injuries and temporary instability. To prevent neurological complications in patients with osteoporosis, the calcified discs are loosened anteriorly before posterior osteotomy.

In our patient, due to the advanced degree of deformity we preferred an anterior release and L₃ vertebra closed wedge osteotomy. In the postoperative period, to reduce the burden on the implant, a corset was used. After the fusion mass was visualized on the X-ray at postoperative month 7, corset use was tapered to zero during the following 3 months.





Figure 4 (A-B). Preoperative anterior-posterior and lateral views of the patient.

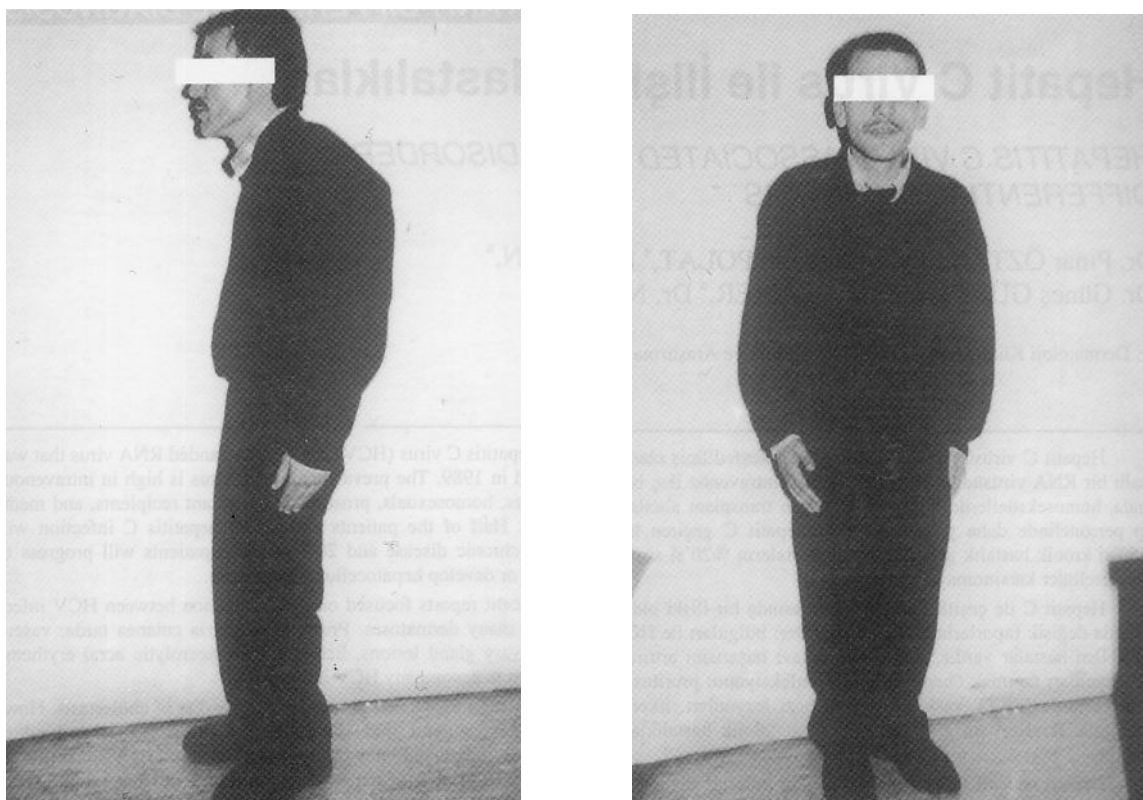


Figure 5 (A-B). At the 7th postoperative month, anterior-posterior and lateral views of the patient.

Osteotomy surgery in patients with AS is associated with a higher complication rate compared to other surgeries for adult spinal deformity.² Infection, instrumentation failure, major general complications and vascular and neurological complications are not uncommon.

In our patient, in postoperative week 6, a pedicular screw in L₅ pulled out and this happened despite a stable fixation and the use of a corset. This may be attributed to overcorrection of the rigid deformity and to poor bone quality. In the revision operation, the sacrum was included in the fixation. Transpedicular wedge osteotomy may correct or prevent progression of thoracolumbar kyphosis caused by AS. High complication rates in this group of patients are due partly to the difficult surgery but also to the underlying disease. Surgery should be performed in specialized centers by experienced surgeons.

Acknowledgements

The authors thank Greg Hammond for proofreading the English version of this manuscript.

REFERENCES

1. Van Royen BJ, De Gast A, Smith TH. Deformity planning for sagittal plane corrective osteotomies of the spine in ankylosing spondylitis. *Eur Spine J* 2000; 9:492-8.
2. Willems KF, Slot GH, Anderson PG, Pavlov PW, de Kleuver M. Spinal osteotomy in patients with ankylosing spondylitis: Complications during first postoperative year. *Spine* 2005;30:101-7.
3. Weatherley C, Jaffray D, Terry A. Vascular complications associated with osteotomy in ankylosing spondylitis: A report of two cases. *Spine* 1988;13:43-6.
4. Hehne HJ, Zielke K, Bohm H. Polysegmental lumbar osteotomies and transpedicled fixation for correction of long curved kyphotic deformities in ankylosing spondylitis. Reports on 177 cases. *Clin Orthop Relat Res* 1990;(258):49-55.
5. Thomasen E. Vertebral osteotomy for correction of kyphosis in ankylosing spondylitis. *Clin Orthop Relat Res* 1985;(194): 142-52.