

# Retropharyngeal Liposarcoma Presenting with Dysphagia and Weight Loss: Case Report

## Disfaji ve Kilo Kaybı ile Başvuran Bir Retrofaringeal Liposarkom Olgusu

Senem ÇENGEL, MD,<sup>a</sup>  
A. Şefik HOŞAL, MD<sup>b</sup>

<sup>a</sup>Department of Otorhinolaryngology-Head and Neck Surgery, Ondokuz Mayıs University, Faculty of Medicine, Samsun

<sup>b</sup>Department of Otorhinolaryngology-Head and Neck Surgery, Hacettepe University, Faculty of Medicine, Ankara

Geliş Tarihi/Received: 22.08.2008  
Kabul Tarihi/Accepted: 05.12.2008

Yazışma Adresi/Correspondence:  
Senem ÇENGEL, MD  
Ondokuz Mayıs University,  
Faculty of Medicine,  
Department of Otorhinolaryngology-Head and Neck Surgery, Samsun,  
TÜRKİYE/TURKEY  
senemcengel@hotmail.com

**ABSTRACT** Liposarcoma is a common soft tissue malignant tumor, although it is rare in the head and neck region. In particular, there have been only a few cases of liposarcoma arising in the retropharyngeal space. Those tumors cause special diagnostic and therapeutic difficulties. In this case, a well-differentiated liposarcoma of the retropharyngeal space in a 51-year-old woman is reported. The tumor continued to grow slowly over a period of four years. We were unable to make a proper diagnosis of this tumor prior to surgery although the radiographic findings resembled the tumors containing fatty component. In the present case, total excision of the tumor with free margins was performed. Although surgical excision with a wide margin is appropriate, it was difficult to resect the tumor completely. Herein, recommendations for earlier and correct diagnosis and treatment of this neoplasm are discussed with a review of the literature.

**Key Words:** Liposarcoma; hypopharyngeal neoplasms

**ÖZET** Liposarkomlar yetişkinlerde sık görülen yumuşak doku tümörlerinden biri olmasına rağmen baş boyun bölgesinin nadir görülen tümörlerinden biridir. Literatürde şimdiye kadar çok az sayıda retrofaringeal bölgeden köken alan liposarkom olgusu yer almaktadır. Ayrıca, retrofaringeal bölgeden köken alanlarda tanı ve tedavi oldukça zordur. Bu makalede, 51 yaşında bir kadın hastada retrofaringeal bölgede yerleşim gösteren iyi diferansiye liposarkom olgusu tartışıldı. Dört yıllık bir dönem içinde yavaş yavaş büyüme gösteren tümörde, radyolojik bulgular tümörün yağ komponentleri içerdiğini göstermekle birlikte, tümörün kesin tanısı cerrahi sonrası konulabildi. Tedavi olarak tümör serbest cerrahi sınırlarla birlikte total olarak çıkartıldı. Liopsarkomlarda tedavi tümörün geniş emniyet marjinleriyle çıkarılması olmakla beraber bu her zaman mümkün olmamaktadır. Burada nadir görülen bu tümörün erken ve doğru tanısı ve tedavisi için öneriler literatür ışığında tartışıldı.

**Anahtar Kelimeler:** Liposarkom; hipofaringeal neoplazmlar

**Türkiye Klinikleri J Med Sci 2010;30(4):1421-4**

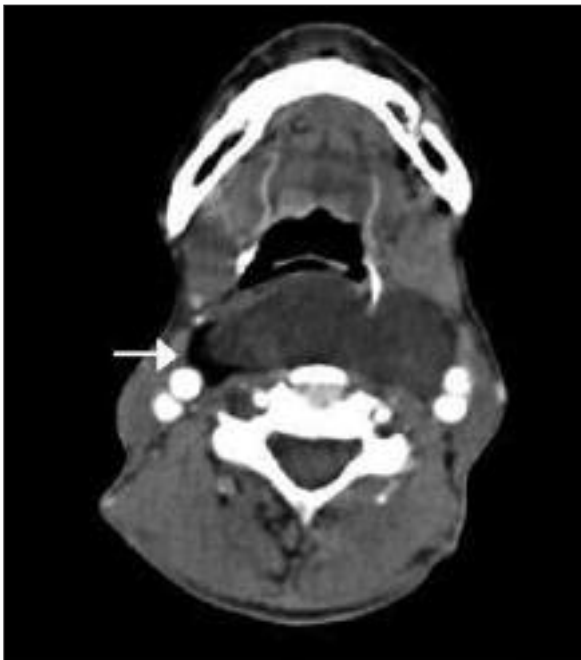Liposarcoma, the second most common soft tissue sarcoma, is rarely localized in the head and neck region.<sup>1</sup> To our knowledge, there are only seven other reports of a liposarcoma occurring in the retropharyngeal space.<sup>2-7</sup> The clinical and pathologic characteristics of these tumors are mainly obtained from studies of liposarcoma cases arising from other parts of the body rather than the head and neck. Therefore, it is difficult to make rational treatment plan for the head and neck liposarcomas. In this report, a case of well-differentiated liposarcoma of the retropharyngeal space is reported and discussed in the light of the current literature.

## CASE REPORT

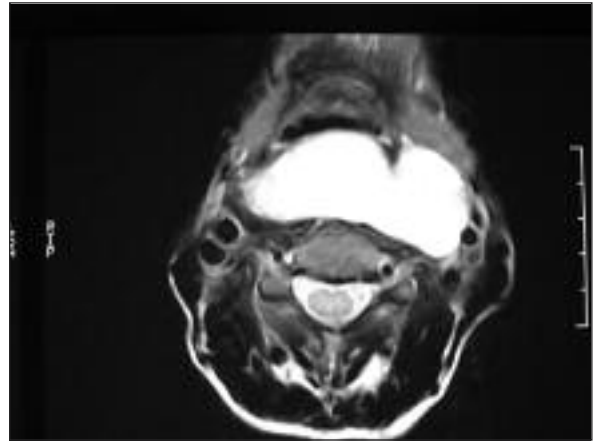
A 51-year-old woman presented with a four year history of dysphagia and a foreign-body sensation in her throat that gradually increased over the past six months. She did not complain of hoarseness or dysphonia. She was a nonsmoker, and had a significant weight loss.

Physical examination revealed a soft, non-tender, extensive swelling in both sides of the neck, prominently on the left side. Fiberoptic laryngoscopy revealed a smooth sessile swelling of the posterior pharyngeal wall extending behind and over the larynx preventing observation of the laryngeal inlet.

The computed tomography (CT) demonstrated a large, well circumscribed non-enhancing lesion in the retropharyngeal area, 3 x 6 x 9.5 cm in size, and extending from the oropharynx down to the level of the thyroid gland. A small crescentic component with fat density could be seen at the right lateral aspect (Figure 1). In addition, a fatty internal septation was seen more superiorly.



**FIGURE 1:** Axial CT scan of the neck with intravenous contrast shows a large retropharyngeal mass with a component at fat density on the right lateral margin (arrow).

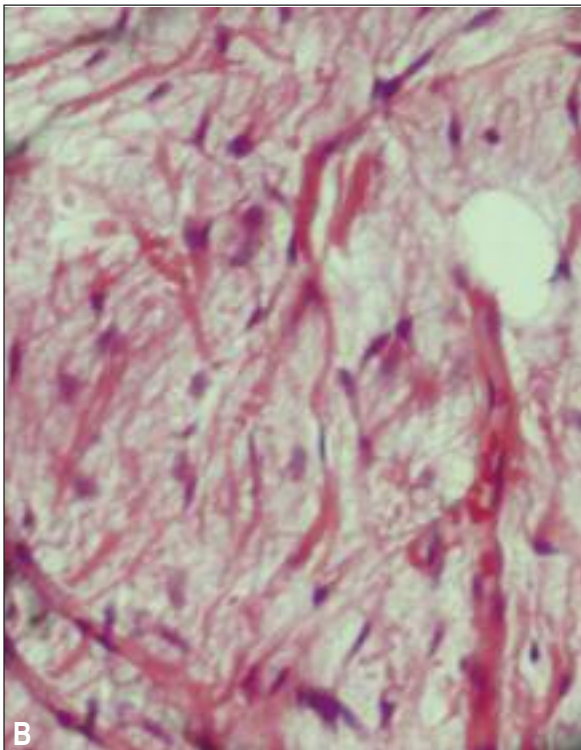
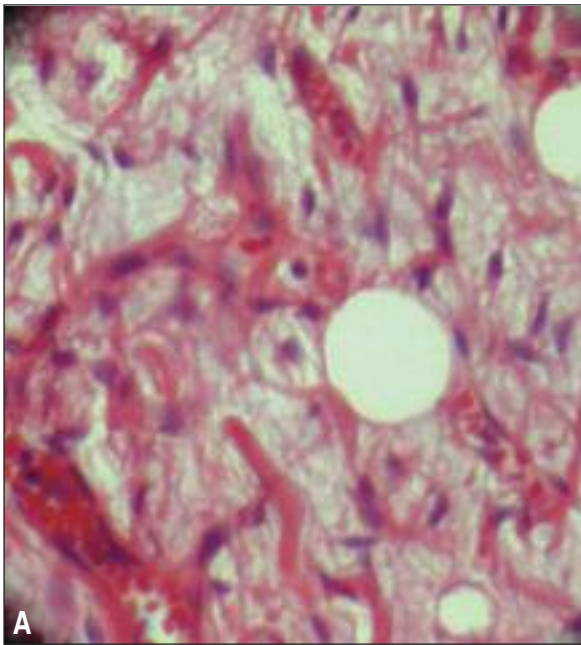


**FIGURE 2:** The fat suppressed T2-weighted image demonstrates signal loss of the right lateral component, confirming its fatty nature.

The magnetic resonance imaging (MRI) performed to further establish the nature and extent of this soft tissue mass revealed a sharply margined lobular mass, isointense to muscle on T1 W1, hyperintense on T2 weighted images. The CT the mass showed pronounced enhancement following gadolinium injection. The fat density component seen on CT again demonstrated signal changes consistent with fat and lost signal on the fat saturated images (Figure 2).

The tumor was excised through an oblique incision on the left side of the neck where the mass was more predominant. The tumor was extending from cranial base to the clavicle and occupying the retropharyngeal and parapharyngeal spaces. The tumor was removed completely by blunt and partly sharp dissection. The gross specimen was lobulated and well-circumscribed yellowish-white fatty tissue which measured 14 x 8 cm. The histological diagnosis was well-differentiated liposarcoma. Scattered fusiform or vacuolated lipoblasts with slightly pleomorphic nuclei were easily found. In most fields it consisted of well-differentiated adipose tissue without mitotic figures or necrosis (Figure 3A-3B).

Adjuvant postoperative radiotherapy was not indicated, since the tumor was excised completely with clear margins. Chemotherapy was not also considered. Close clinical follow-up and periodic CT scans were planned. So far, the patient recove-



**FIGURE 3A-B:** Large vacuolated and pleomorphic lipoblasts in hematoxylin-eosin stain, x400.

red well with no evidence of tumor in three year follow-up.

## DISCUSSION

Although liposarcoma is common among soft tissue sarcomas in adults, it rarely occurs in the head

and neck region.<sup>1</sup> The majority of liposarcomas occur between the fourth and sixth decades of life, predominantly in males. They arise from primitive mesenchymal cells other than mature adipose tissue or a pre-existing lipoma.<sup>9</sup> Presence of wide variety of cell types in liposarcomas, both morphologically and cytochemically, indicates that these tumors originate from the totipotential mesenchymal cells.<sup>10</sup>

The histological classification has prognostic significance: clinical behavior tends to correlate with degree of cellular differentiation. Enzinger and Weiss proposed a classification into four groups: myxoid, round cell, well-differentiated and pleomorphic.<sup>1</sup> The influence of the grade of differentiation on survival was demonstrated in a study through 5-year survival rate, which was about 70% in the more differentiated types and 20% in the nondifferentiated forms.<sup>11</sup> Although more differentiated forms may recur locally, they are unlikely to metastasize. Metastasis of liposarcoma occurs most frequently to the lungs.

The diagnosis of liposarcoma presents some difficulties because of its slow-growing nature, tendency to circumscribe itself and firm but resilient texture. Clinically, it may present itself with various symptoms according to its location and size. In our case the main symptoms were dysphagia, an abnormal sensation in throat and weight loss. Rhinorrhea, nasal obstruction, sleep apnea and neck swelling are other symptoms reported in the literature. Radiologic findings, especially MRI and CT, are useful to make a correct diagnosis. Well-differentiated liposarcomas usually appear similar to lipomas on CT and MRI. They may have the same density with subcutaneous fat, or may be slightly heterogeneous and denser. The MRI findings are more variable, however well differentiated types tend to mimic lipomas with well defined margins, high signal on T1-weighted images, no or very faint enhancement following contrast. The undifferentiated ones are more difficult to diagnose as they have only scattered fatty components or fatty septations. The majority of these tumors typically have low signal on T1-weighted sequences with intense enhancement on postcontrast images. Our

case, although histologically classified as a well-differentiated type, demonstrated features of a less differentiated type with only few small foci of fatty tissue and a diffuse, prominent enhancement.

Both surgical excision and radiotherapy have been tried in the treatment.<sup>1-9,12</sup> Radiotherapy has been used either after surgery to sterilize the region or for unresectable tumors. It appears particularly useful for the myxoid variety. Chemotherapy was mainly used in metastatic disease however it has been used in a few cases as an adjunct to radiotherapy. Even though liposarcomas may appear encapsulated, the main tumor is often surrounded by satellite nodes. So, it is often difficult to resect the tumor with clear margins, especially in the he-

ad and neck region. McCulloch et al. reported an 80% rate of local or distant recurrence in patients with incomplete surgical excision compared with a rate of only 17% when complete excision was accomplished.<sup>12</sup> Therefore, complete excision of the tumor with free margins is critical in the treatment. In the other reports of retropharyngeal liposarcomas, six patients were treated only by surgery and one was treated by both surgery and radiotherapy due to recurrence after surgery.<sup>2-8</sup>

In conclusion, liposarcomas of the retropharyngeal space are extremely rare and usually show a very slow growth rate. Wide local excision is the mainstay of the treatment and regular follow-up is strongly recommended.

## REFERENCES

1. Enzinger FM, Weiss SW. Liposarcoma. In: Enzinger FM, Weiss SW, eds. *Soft Tissue Tumors*. 3<sup>rd</sup> ed. St Louis: Mosby; 1995. p. 431-66.
2. Menown IB, Liew SH, Napier SS, Primrose WJ. Retro-pharyngeal liposarcoma. *J Laryngol Otol* 1992;106(5):469-71.
3. Hermans R, Dewitte B, Delaere P, Feenstra L, Baert AL. Retropharyngeal liposarcoma. *J Belge Radiol* 1993;76(3):176-7.
4. Prince ME, Nasser JG, Fung BR, Broderick I. Liposarcoma of the retropharyngeal space: review of the literature. *J Otolaryngol* 1997;26(2):139-42.
5. Ozawa H, Soma K, Ito M, Ogawa K. Liposarcoma of the retropharyngeal space: report of a case and review of literature. *Auris Nasus Larynx* 2007;34(3):417-21.
6. Demir D, Katircioglu S, Suoglu Y, Bilgic B. Radiation-induced liposarcoma of the retropharyngeal space. *Otolaryngol Head Neck Surg* 2006;134(6):1060-2.
7. Ballesteros F, Jose Sanz J, Maria Guilemany J, Moragas M, Gaspa A, Bernal-Sprekelsen M. Bulky cervical liposarcoma associated with sleep apnea syndrome. *Acta Otolaryngol* 2006;126(2):209-13.
8. Gundelach R, Ullah R, Coman S, Campbell K. Liposarcoma of the retropharyngeal space. *J Laryngol Otol* 2005;119(8):651-4.
9. Otte TH, Kleinasser O. Liposarcoma of the head and neck. *Arch Otorhinolaryngol* 1981;232(3):285-91.
10. Sadeghi EM, Sauk JJ Jr. Liposarcoma of the oral cavity. Clinical, tissue culture, and ultrastructure study of a case. *J Oral Pathol* 1982;11(4):263-75.
11. Enzinger FM, Winslow DJ. Liposarcoma: A study of 103 cases. *Virchows Arch Pathol Anot* 1962;335:367-88.
12. McCulloch TM, Makielski KH, McNutt MA. Head and neck liposarcoma. A histopathologic reevaluation of reported cases. *Arch Otolaryngol Head Neck Surg* 1992;118(10):1045-9.