

Unilateral Iridocyclitis with Hypopyon as the Initial Presentation of Relapsing Acute Lymphoblastic Leukemia: Case Report

Akut Lenfoblastik Lösemide Relapsın İlk Bulgusu: Hipopiyonlu İridosiklit

Fatih Mehmet AZIK, MD,^a
Arsen AKINCI, MD,^b
Vildan KOŞAN ÇULHA, MD,^a
Kuddusi TEBERİK, MD,^c
Tülin REVİDE SAYLI, MD,^a
Mehmet Yasin TEKE, MD,^d
Bahattin TUNÇ, MD^a

^aDepartments of
Pediatric Haematology,
^bPediatric Ophthalmology,
Dışkapı Children's Hospital,
^cDepartment of Eye Diseases,
^dDepartment of Retina,
Ulucanlar Eye Hospital, Ankara

Geliş Tarihi/Received: 01.09.2008
Kabul Tarihi/Accepted: 28.11.2008

Yazışma Adresi/Correspondence:
Dr. Fatih Mehmet AZIK
Dışkapı Children's Hospital,
Department of Pediatric Haematology,
Ankara, TÜRKİYE/TURKEY
mfatihazik@yahoo.com

ABSTRACT Leukemic hypopyon is a rare feature of presentation or relapses of leukemia. The aim of this publication is to report a case of unilateral iridocyclitis with hypopyon as the initial presentation of relapsing acute lymphoblastic leukemia. An 8-year-old boy with acute lymphoblastic leukemia developed unilateral ocular pain and sudden visual loss in the second remission period. Cytopathological examination of the aqueous humor revealed the presence of lymphoblasts. There was no evidence of leukemic cells in the simultaneous bone marrow and cerebrospinal fluid samples. Iridocyclitis resolved dramatically in a few days after local irradiation and chemotherapy. The treatment modality in these cases is not well established. Leukemic hypopyon can be treated completely and satisfactory visual improvement can be achieved by local radiotherapy combined with systemic and intrathecal chemotherapy. However, leukemic eye involvement usually shows a poor prognostic factor especially it represents as leukemic hypopyon.

Key Words: Precursor cell lymphoblastic leukemia-lymphoma; iridocyclitis

ÖZET Hipopiyon oldukça nadir olarak lösemilerin ilk başvuru ya da relaps bulgusu olabilir. Bu yayının amacı hipopiyonlu iridosiklitin ilk relaps bulgusu olduğu akut lenfoblastik lösemili bir çocuğu rapor etmektir. Akut lenfoblastik lösemi ile tedavisi sürdürülen 8 yaşında bir çocuk hastada ikinci remisyon döneminde tek taraflı göz ağrısı ve ani görme kaybı ortaya çıktı. Gözden alınan aköz humorun sitopatolojik incelemesinde lenfoblastların varlığı tespit edildi. Eş zamanlı kemik iliği ve beyin omurilik sıvısı incelemelerinde lösemik tutulum saptanmadı. Lokal radyoterapi ve sistemik kemoterapi sonrası birkaç gün içinde iridosiklit düzeldi. Lösemik tutulumla bağlı iridosiklit olan olgularda tedavi protokolleri henüz netleşmemiştir. Lösemik hipopiyon lokal radyoterapi, sistemik ve intratekal kemoterapi ile tam olarak tedavi edilebilir, görme fonksiyonu yeterli bir şekilde geri kazanılabilir. Ancak, lösemiye bağlı göz tutulumu özellikle de lösemik hipopiyon genellikle kötü prognozun işaretçisidir.

Anahtar Kelimeler: Prekürsör hücreli lenfoblastik lösemi; hipopiyonlu iridosiklit

Türkiye Klinikleri J Ophthalmol 2009;18(2):137-40

Ocular involvement in leukemia is well established.¹ Acute leukemia as involve the eye more commonly than chronic ones.² The tissue of choroid and retina is the most common site of involvement.³ Nodular or diffuse involvement of the iris by leukemic cells has also been reported.⁴ Leukemic hypopyon is not a common feature of presentation or relapses of leukemia.⁵ However there are several cases in the literature in which the presentation or the relapse of acute leukemia occurred in the

form of iridocyclitis.⁶⁻¹³ The treatment modality in these cases is not well established.

In this paper, we report a case with unilateral iridocyclitis with hypopyon as the initial presentation of relapsing acute lymphoblastic leukemia (ALL) and we discuss the outcome obtained after local irradiation and chemotherapy.

CASE REPORT

An 8-year-old boy with high risk ALL developed unilateral ocular pain and sudden visual loss in the second remission period. The treatment was initiated with Berlin-Frankfurt-Münster Study Group 95 (BFM-95) chemotherapy protocol, but remission could not be achieved until high risk blocks. (According to BFM-95 protocol the high risk criteria are; 1) Leukaemic cells >1000 micromol/L in the peripheral blood on day 8 after 7 day prednisone pre-phase. 2) No complete remission on day 33. 3) Translocation t(9;22) or BCR/ABL recombination. 4) Translocation t(4;11) or MLL/AF4 recombination. 5) Each criterion alone qualifies as high risk regardless of age and WBC). Prophylactic cranial radiation therapy (1800 cGy) was applied according to BFM-95 protocol. During the first month of continuation therapy (23 months after the diagnosis) bone marrow and central nervous system relapse occurred. A relapse chemotherapy protocol was started and weekly triple intrathecal treatment (methotrexate, cytarabine, and prednisone) was continued until cerebrospinal fluid was cleared. During the recovery of bone marrow after the last chemotherapy regimen (6 months later from the first relapse) he suddenly developed unilateral ocular pain and visual loss. His best corrected visual acuity was counting fingers from one meter distance in the right eye and 10/10 in the left eye. Color vision could not be evaluated in the right eye and it was 12/12 in the left eye. There was no relative afferent pupillary defect. Eye movements were normal. Intraocular pressures were 52 and 19 mmHg in the right and left eyes, respectively. Slit-lamp examination revealed iridocyclitis (4+ inflammatory cells in anterior chamber) with 1/8 hypopyon in the right eye while left eye was completely normal (Figure 1). Fundus of the right eye

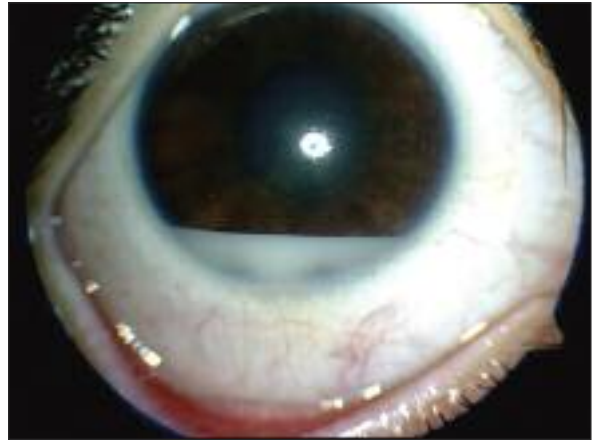

FIGURE 1: Slit-lamp photograph of right eye demonstrating leukemic hypopyon at presentation.

could not be visualized; however, B mode ultrasonographic examination did not reveal any pathologic finding. Dilated fundus examination of the left eye was completely normal. A treatment with a topical steroid drop (1 drop/hour), tropicamide (3 drops/day), and topical combined glaucoma agents; dorzolamid HCL and timolol maleat combination (2 drops/day) and brimonidine tartrate (2 drops/day) was started and the patient was hospitalized in the haematology clinic for the further investigation. On physical examination, no organomegaly or lymphadenopathy was detected. Neurologic examination did not reveal any deficit.

Laboratory studies disclosed following values: Hemoglobin 12.6 g/dL, hematocrit 37.4%, white blood cells 2.100/mm³ with 34% neutrophils, and platelets 242.000/mm³ erythrocyte sedimentation rate 30 mm/h, C-reactive protein 1.23 mg/dL. Biochemical profiles of blood were normal.

1 mL of intraocular cellular infiltrate was aspirated with a 28 gauge needle from anterior chamber under topical anesthesia (proparacaine HCL). Cytopathological examination of this sample revealed the presence of lymphoblasts in the aqueous humor (Figure 2). Bone marrow aspiration biopsy and lumbar puncture (LP) were performed. LP disclosed normal composition. There was no evidence of leukemic cells in the bone marrow and cerebrospinal fluid samples.

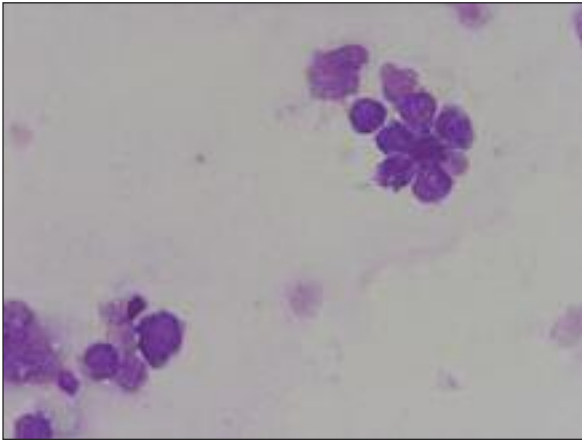


FIGURE 2: Light microscopic photograph demonstrating lymphoblasts in the aqueous humor, Wright-Giemsa stain, 1000x.

Intraocular pressure decreased suddenly just after aspiration of aqueous humor from anterior chamber and hypopyon resolved. However, in following a couple of days hypopyon redeveloped gradually and intraocular pressure could not be controlled despite the addition of systemic glaucoma agents (100 mL mannitol/day, acetazolamide 500 mg/day) to the treatment. Measured minimum intraocular pressure level for the right eye was 42 mmHg under this maximum treatment. Additionally, 4 days after the first diagnosis of iridocyclitis in the right eye, iridocyclitis without hypopyon and elevation of intraocular pressure was detected in the left eye. The same treatment was applied to the left eye. Measured minimum intraocular pressure level for the left eye was about 30 mmHg under this maximum treatment. Local irradiation with a total dose of 1800 cGy/10 fractions; systemic chemotherapy with vincristine and dexamethasone for 2 weeks; and weekly triple intrathecal treatment (methotrexate, cytarabine, and prednisone) was applied. Iridocyclitis resolved dramatically in a few days after local irradiation and systemic chemotherapy. One month after treatment, his best corrected visual acuity was 8/10 in the right eye and 10/10 in the left eye. Intraocular pressures were 12/14 mmHg. Slit-lamp examination revealed mild anterior subcapsular cataract in the right eye. Remaining ocular examination was completely normal. He hasn't had a suitable donor for stem cell transplantation.

Four months later from the eye involvement, testis and bone marrow relapse (third relapse) occurred. And in spite of systemic chemotherapy and local radiotherapy he did not achieve a remission period. He died seven months later from the third relapse.

DISCUSSION

Uveal involvement in children with ALL is usually observed with a concomitant central nervous system and/or bone marrow relapse and anterior chamber involvement in these cases is typically bilateral.^{7,14-16} However, in our patient leukemic hypopyon was unusually unilateral and there was neither a concomitant central nervous system nor bone marrow relapse. There are several cases in the literature resembling to our case in which the presentation or the relapse of ALL occurred in the form of unilateral iridocyclitis without a concomitant central nervous system or bone marrow relapse.^{12,17,18} The treatment modality in these isolated cases is not well established. In each of these cases, authors used different treatment modalities and the outcomes varied.

In the first report, by Masera G et al, a 7-year-old girl was successfully treated for ALL, and remained in remission after treatment had been completed in 3 years. Four months after cessation of treatment, iridocyclitis with hypopyon developed in one eye. Exudate from the anterior chamber contained numerous lymphoblasts. Local radiotherapy led to complete resolution of the ocular lesions, and the patient remained well 22 months later.¹⁸

Jankovic M et al reported follow-up observations for a case of isolated leukemic uveopathy that was first diagnosed in an 11-year-old girl shortly after cessation of treatment for ALL.¹² Prior therapy for the complication included systemic antileukemic chemotherapy and low doses of radiation (3.9 Gy) to the affected eye. Two months later, chemotherapy was stopped for the second time, she presented with recurrent leukemic hypopyon in the left eye and was treated again with antileukemic chemotherapy followed in 1 year by high-dose (20 Gy) local irradiation. After a third recurrence, which was

diagnosed as pre-B/B-cell ALL with a variable position of maturation arrest, enucleation was performed. The patient remained in complete remission for 26+ months after an additional course of systemic chemotherapy. This case illustrated the difficulty of eradicating leukemic cells from the eye with conventional treatment but suggests that a relapse in this site is not necessarily an ominous prognostic sign.¹²

Dadeya S et al reported an 11-year-old child presenting with plastic iridocyclitis and hypopyon.¹⁷ Subsequent paracentesis revealed leukemic infiltrates. A bone marrow biopsy confirmed the diagnosis of acute lymphocytic leukemia. The patient received the complete protocol of chemotherapy (vincristine, adriamycin and methotrexate) and radiotherapy prescribed for treatment of leukemia. After 2 weeks of treatment, uveitis resolved completely and vision improved to 6/9. In their unusual case of leukemic hypopyon, they advocated anterior chamber paracentesis and pediatrician referral in all cases of refractory uveitis.¹⁸

Acute loss of vision, which is an ophthalmic emergency, is sudden visual loss which may be uni-

lateral or bilateral, transient or permanent. A systematic approach is necessary to reach the correct diagnosis in a patient with acute visual loss.¹⁹ Our case developed unilateral ocular pain and sudden visual loss in the second remission period. A detailed history is the first and most important step in diagnosis. Good prognosis may be obtained by a prompt investigational work-up and treatment. History of ALL and investigational study of hypopyon resulted in leukemic relapse. Our case received local irradiation with a total dose of 1800 cGy/ 10 fractions and systemic chemotherapy with vincristine and dexamethasone for 2 weeks; and weekly triple intrathecal treatment for 3 weeks (methotrexate, cytarabine, and prednisone) was applied. Iridocyclitis resolved dramatically in a few days after local irradiation and chemotherapy and vision improved to 8/10. This case illustrated that leukemic hypopyon can be treated completely and satisfactory visual improvement can be achieved by local radiotherapy combined with systemic and intrathecal chemotherapy. However, it seems that leukemic eye involvement may be a poor prognostic factor especially it represents as leukemic hypopyon.

REFERENCES

- Allen RA, Straatma BR. Ocular involvement in leukemia and allied disorders. *Arch Ophthalmol* 1961;66:490-508.
- Martin B. Infiltration of the iris in chronic lymphatic leukaemia. *Br J Ophthalmol* 1968;52(10):781-5.
- Robb RM, Ervin LD, Sallan SE. An autopsy study of eye involvement in acute leukemia of childhood. *Med Pediatr Oncol* 1979;6(2):171-7.
- Fonken HA, Ellis PP. Leukemic infiltrates in the iris. Successful treatment of secondary glaucoma with x-irradiation. *Arch Ophthalmol* 1966;76(1):32-6.
- Abramson DH, Wachtel A, Watson CW, Jereb B, Wollner N. Leukemic hypopyon. *J Pediatr Ophthalmol Strabismus* 1981;18(3):42-4.
- Wadhwa N, Vohra R, Shrey D, Iyer VK, Garg S. Unilateral hypopyon in a child as a first and sole presentation in relapsing acute lymphoblastic leukemia. *Indian J Ophthalmol* 2007;55(3):223-4.
- Yi DH, Rashid S, Cibas ES, Arrigg PG, Dana MR. Acute unilateral leukemic hypopyon in an adult with relapsing acute lymphoblastic leukemia. *Am J Ophthalmol* 2005;139(4):719-21.
- Wetzler M, Lincoff N. Unusual manifestations of acute leukemia. Case 3. Unilateral leukemic hypopyon. *J Clin Oncol* 2000;18(19):3439-40.
- Matano S, Ohta T, Nakamura S, Kanno M, Sugimoto T. Leukemic hypopyon in acute myelogenous leukemia. *Ann Hematol* 2000;79(8):455-8.
- Ayliffe W, Foster CS, Marcoux P, Upton M, Finkelstein M, Kuperwaser M, et al. Relapsing acute myeloid leukemia manifesting as hypopyon uveitis. *Am J Ophthalmol* 1995;119(3):361-4.
- Decker EB, Burnstine RA. Leukemic relapse presenting as acute unilateral hypopyon in acute lymphocytic leukemia. *Ann Ophthalmol* 1993;25(9):346-9.
- Jankovic M, Masera G, Uderzo C, Cattoretti G, Conter V, Ceppellini C, et al. Recurrences of isolated leukemic hypopyon in a child with acute lymphoblastic leukemia. *Cancer* 1986;57(2):380-4.
- Smith WS, Burke MJ, Wong KY. Hypopyon in acute lymphoblastic leukemia. *Med Pediatr Oncol* 1984;12(4):258-9.
- Ridgway EW, Jaffe N, Walton DS. Leukemic ophthalmopathy in children. *Cancer* 1976;38(4):1744-9.
- Gruenewald RL, Perry MC, Henry PH. Leukemic iritis with hypopyon. *Cancer* 1979;44(4):1511-3.
- Ninane J, Taylor D, Day S. The eye as a sanctuary in acute lymphoblastic leukaemia. *Lancet* 1980;1(8166):452-3.
- Dadeya S, Malik KP, Guliani BP, Dewan S, Mehta R, Gupta VS. Acute lymphocytic leukemia presenting as masquerade syndrome. *Ophthalmic Surg Lasers* 2002;33(2):163-5.
- Masera G, Carnelli V, Uderzo C, Toselli C, Lasagni F, Lambertenghi E. Leukaemic hypopyon in acute lymphoblastic leukaemia after interruption of treatment. *Arch Dis Child* 1979;54(1):73-4.
- Tatlıpınar S, Özden S. [Acute visual loss.] *Turkiye Klinikleri J Med Sci* 2003;23(2):166-9.