

# Calcifying Tumor of the Pleura: Case Report and Review of the Literature

## Plevranın Kalsifiye Tümörü: Olgu Sunumu ve Literatürün Gözden Geçirilmesi

Elif Ülker AKYILDIZ,<sup>a</sup>  
Ulviye YALÇINKAYA,<sup>a</sup>  
Ahmet S. BAYRAM,<sup>b</sup>  
Sinem KANTARCIOĞLU COŞKUN<sup>a</sup>

<sup>a</sup>Department of Pathology,  
<sup>b</sup>Department of Thoracic Surgery,  
Uludağ University Faculty of Medicine,  
Bursa

Geliş Tarihi/Received: 21.01.2014  
Kabul Tarihi/Accepted: 13.10.2014

Yazışma Adresi/Correspondence:  
Elif Ülker AKYILDIZ  
Uludağ University Faculty of Medicine,  
Department of Pathology, Bursa,  
TÜRKİYE/TURKEY  
ulker33@yahoo.com

**ABSTRACT** Calcifying fibrous tumor is a well-circumscribed fibrous lesion usually observed in the subcutaneous and soft tissue of body, in serous areas, such as pleura, pericardium, peritoneum and the adrenal glands, lungs, mediastinum. It is characterized by dystrophic calcification inside the hyalinized fibrotic stroma. In 1996, Pinkard et al, for the first time, presented 3 cases of calcified fibrous tumor located on pleura. In macroscopic examination, the lesion is white-colored and hard consistency. In histological examination, spindle cells and multiple dystrophic or psammomatous calcifications in hyalinized collagenous tissue are observed. Inflammatory lymphoplasmacytoid cells in fibrous tissue can be seen. In immunohistochemical examination, spindle cells are stained positive with vimentin. Calcifying fibrous tumor located in the pleura is a rare lesion. Fourteen cases have been reported in the english literature to date. We present 44 year-old female patient that ossified mass was detected in the pleura and diagnosed with calcified tumor.

**Key Words:** Fibrosis; pleura; neoplasms

**ÖZET** Kalsifiye fibröz tümör, genellikle deri altında, yumuşak dokuda, plevra, perikard, periton gibi seröz alanlarda, adrenal bezlerde, akciğerde ve mediastende görülür. Hyalinize fibröz stroma içinde distrofik kalsifikasyon ile karakterizedir. İlk kez 1996 yılında Pinkard ve ark. plevrada yerleşmiş 3 kalsifiye fibröz tümör olgusu yayınlamıştır. Makroskopik incelemede lezyon beyaz renkli ve sert kıvamdadır. Histolojik incelemede hyalinize kollajenöz doku içinde iğsi hücreler ve çok sayıda distrofik veya psammomatöz kalsifikasyonlar izlenir. Fibröz doku içinde inflamatuvar lenfoplasmositoid hücreler de görülebilir. İmmünohistokimyasal incelemede iğsi hücreler vimentin ile pozitif boyanır. Plevra yerleşimli kalsifiye fibröz tümör nadir bir lezyondur. Günümüze kadar ingilizce literatürde 14 olgu bildirilmiştir. Plevrada osifiye kitle saptanan ve kalsifiye tümör tanısı alan 44 yaşında kadın hastayı sunuyoruz.

**Anahtar Kelimeler:** Fibrozis; plevra; tümörler

**Türkiye Klinikleri J Case Rep 2015;23(4):380-4**

Calcifying fibrous tumor is a well-circumscribed fibrous lesion usually seen in young people. It is observed in the subcutaneous and soft tissue of body, extremities and neck. Also, it may be observed in serous areas, such as pleura, pericardium, peritoneum and the adrenal glands, lungs, mediastinum. It is characterized by dystrophic calcification inside the hyalinized fibrotic stroma. Calcifying fibrous tumor located in the pleura is a rare lesion.<sup>1-4</sup> Fourteen cases have been reported in the english literature. We present 44 year-old female patient that ossified mass was de-

doi: 10.5336/caserep.2014-38881

Copyright © 2015 by Türkiye Klinikleri

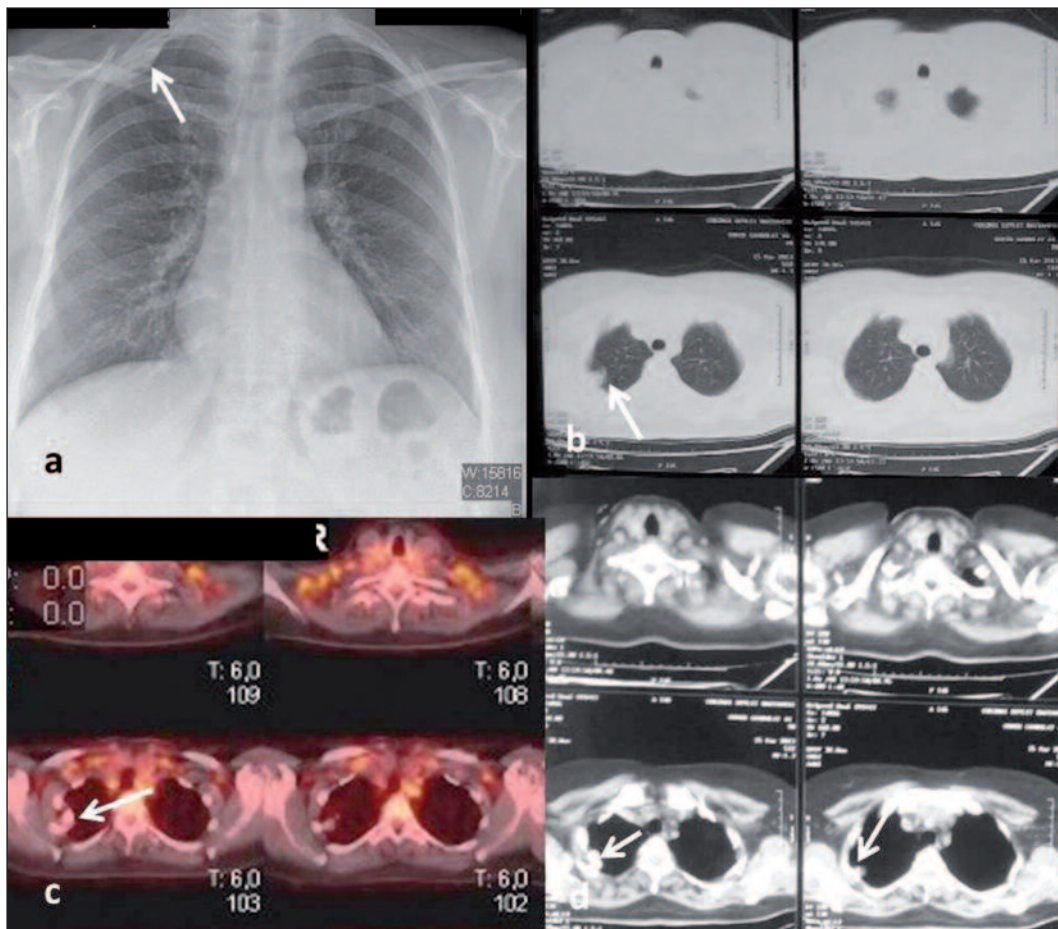
tected in the pleura and diagnosed with calcified pleural tumor as a result of pathologic examination. Informed consent was obtained from the patient.

## CASE REPORT

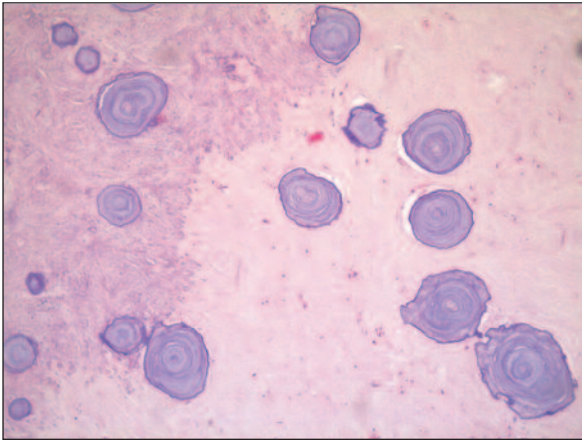
The apical-lateral wall thickening of the right lung was detected in the chest X-ray performed due to increasing dyspnea of 44 year-old woman with dyspnea and chest-back pain (Figure 1a). The thorax CT performed, an ossified mass with an view that it is associated with chest wall was observed in the apical-lateral wall of the right lung (Figure 1b and 1d). In the positron emission tomography (PET), the Standard uptake value (SUV) measure of the mass was detected as 3.5 (Figure 1c). Video-assisted thoracoscopic surgery was performed. Dur-

ing the operation, it has been observed that, the mass 4x2.5x0.5 cm in diameter, was located in the pleura adjacent to second rib, and found to be independent from the lung parenchyma and the rib. The mass was totally removed. Post-operative complication was not observed. The patient was discharge on the second postoperative day.

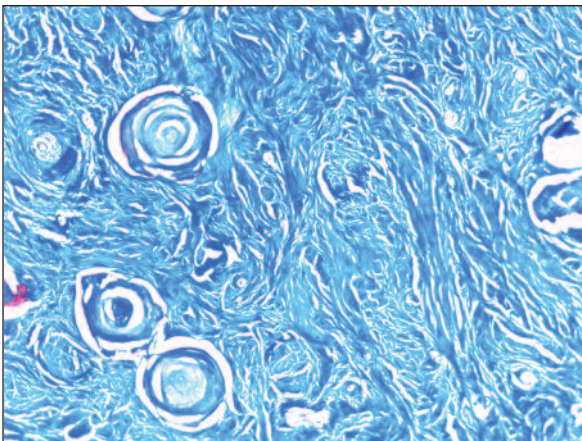
In the pathologic examination of the mass, sparse spindle cells in the hyalinized connective tissue and laminar psammomatous calcification were observed (Figure 2). A small number of lymphocytes and histiocytes were present in the fibrous tissue. Fibrous tissue was stained blue color with Mason trichrome stain (Figure 3). In the immunohistochemical staining, spindle cells were positive with vimentin (Figure 4). It was stained negative for cytokeratin, CD31, and CD34. The patient was



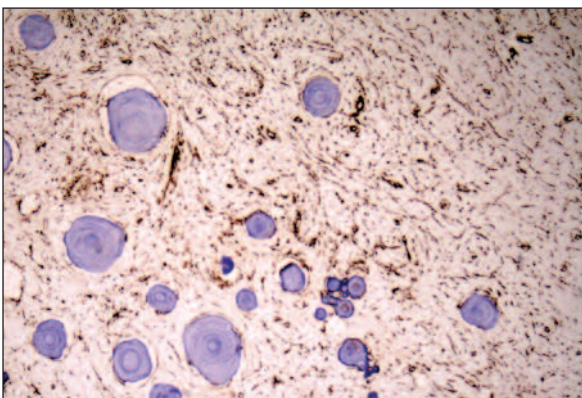
**FIGURE 1:** 1a. The apical-lateral wall thickening of the right lung (chest X-ray); 1 b. and 1d. an ossified mass in the apical-lateral wall of the right lung (thorax CT), 1c. Maximum Standard uptake value (SUV) measure is 3.5 in positron emission tomography (white arrows).



**FIGURE 2:** Sparse spindle cells in the hyalinized connective tissue and laminar psammomatous calcification (Hematoxylin Eosine x200).



**FIGURE 3:** Fibrous tissue was stained blue color with Mason Trichrome stain (x200).



**FIGURE 4:** Positive spindle cells with Vimentin (x200).

diagnosed with these findings as calcified tumor of the pleura.

## DISCUSSION

Calcifying fibrous tumor has been described for the first time in 1988 by Rosenthal and Abdul-Karim with the name of “childhood fibrous tumor with psammoma bodies” in two pediatric patients.<sup>1</sup> Five years later, in 1993, Fetsch et al. have made changes in naming in their publications on 10 patients due to this lesion can be seen in the adult age, psammoma body is not a condition for the diagnosis, lesion is not a real tumor, and suggested the term of “calcifying fibrous pseudotumor”.<sup>2</sup> Calcifying fibrous tumor is a lesion which is usually seen in limbs and trunk, including psammomatous and/or dystrophic calcifications, that hypocellular sclerotic tissue is seen. In 1996, Pinkard et al, for the first time, presented 3 cases of calcified fibrous tumor located on pleura.<sup>3</sup> Today, the term of “calcifying tumor of the pleura” (CTP) is used for this lesion in WHO 2004 classification.<sup>4</sup> Fourteen CTP cases have been reported in the english literature to date. The previously reported cases and our case were summarized in Table 1.<sup>3,5-15</sup>

Non-thoracic calcified fibrous tumors are usually seen in children and adolescents, the mean age has been reported as 14.5 years. Pleural cases were seen in older ages, the mean age is 38.9 years. Our case was middle-aged in accordance with the literature. CTP is often asymptomatic and rarely causes complaints such as chest pain, dry cough. Our patient was admitted to the hospital with dispnea and chest-back pain. CTP may be solitary or multiple.<sup>14,15</sup>

The pathogenesis of CTP remains unclear. Fetsch et al. thought that CTP was a unique form of fibrous pseudotumor.<sup>2</sup> Isaka et al. demonstrated osteopontin, a cytokine associated with inflammation and tissue remodelling, in the spindle cells within the CTP lesions and they speculated that CPT is multifocal and recurrent lesion appears during unusual inflammatory-reparative processes mediated by osteopontin expression.<sup>12</sup> Van Dorpe et al. reported a seventeen year-old girl with multiple peritoneal calcifying fibrous tumors and inflammatory myofibroblastic tumors and they considered CTP as a reactive process to inflammation or the end stage of inflammatory myofibroblastic tumors.<sup>15</sup>

**TABLE 1:** Reported calcifying fibrous tumor of the pleura in the english literature and our case.

Case	Author [Ref No.] (Year)	Age (year)	Gender	Number of Tumors	Operation	Immunostaining positive	Follow-Up
1	Pinkard and colleagues (1996)	23	Female	Multiple	Local resection	—	9 months
2	Pinkard and colleagues (1996)	28	Female	Two	Local resection	—	12 months
3	Pinkard and colleagues (1996)	34	Male	Solitary	Local resection	—	—
4	Hainaut and colleagues (1999)	29	Female	Multiple	Incomplete resection	—	—
5	Ammar and colleagues (2003)	38	Female	Solitary	Local resection	Cytokeratin, vimentin	9 months
6	Jang and colleagues (2004)	31	Female	Solitary	Local resection	Vimentin, CD34	12 months
7	Kondo N (2004)	54	Male	Multiple	Right side resection	—	—
8	Kawahara and colleagues (2005)	35	Female	Multiple	Local extirpation	Vimentin, factor XIIIa	—
9	Mito and colleagues (2005)	54	Male	Two	Local resection	Vimentin, CD34, factor XIIIa	—
10	Shibata and colleagues (2008)	54	Female	Multiple	Incomplete resection	Vimentin	4 months
11	Suh and colleagues (2008)	35	Male	Multiple	Complete resection	—	16 months
12	Isaka and colleagues (2011)	40	Male	Multiple	Complete resection	Vimentin, Osteopontin	28 months
13	Jiang and colleagues (2011)	44	Female	Multiple	Complete resection	—	12 months
14	Ağackiran and colleagues (2012)	40	Male	Multiple	Complete resection	Vimentin	—
15	Present case	44	Female	Solitary	Complete resection	Vimentin	6 months

In macroscopic examination, the lesion is white-colored and hard consistency. In histological examination, spindle cells and multiple dystrophic or psammomatous calcifications in hyalinized collagenous tissue are observed. Inflammatory lymphoplasmacytoid cells in fibrous tissue can be seen.<sup>10</sup>

In immunohistochemical examination, the different staining properties are reported in different studies. Shibata et al reported that spindle cells were positive only for vimentin.<sup>10</sup> In four previously reported cases, keratin, CD34 and factor VIII was positive in spindle cells as well as vimentin.<sup>6-9</sup> In our case, like Shibata spindle cells were positive only for vimentin and negative for cytokeratin, CD31, and CD34. It is believed that, the cause of this difference is the heterogeneity of the lesion.<sup>10,14</sup>

In the differential diagnosis, solitary fibrous tumor, chronic fibrous pleuritis, calcified fibrous plaque are the lesions that should be kept in mind. CD34 and bcl-2 positivity in solitary fibrous tumors is the aid in the differential diagnosis. Prominent chronic inflammatory infiltration, zonation and vertical vein structures are observed in chronic fibrous pleuritis. Calcified pleural plaque is smooth and ivory white, consisting of uniform and intensive-layered collagen fibers in parallel alignment or interweaving reticulum.

The only treatment of CTP, which is slow-growing benign lesion, is complete excision. The recurrence or distant metastasis was not documented so far.<sup>14</sup> Since CTP has been reported in recent years and is extremely rare, the new cases are important to clarify prognosis of this lesion.

## REFERENCES

- Rosenthal NS, Abdul-Karim FW. Childhood fibrous tumor with psammoma bodies. Clinicopathologic features in two cases. *Arch Pathol Lab Med* 1988;112(8):798-800.
- Fetsch JF, Montgomery EA, Meis JM. Calcifying fibrous pseudotumor. *Am J Surg Pathol* 1993;17(5):502-8.
- Pinkard NB, Wilson RW, Lawless N, Dodd LG, McAdams HP, Koss MN, et al. Calcifying fibrous pseudotumor of pleura. A report of three cases of a newly described entity involving the pleura. *Am J Clin Pathol* 1996;105(2):189-94.
- Travis WD, Tazelaar H, Churg A. Mesenchymal tumours. In: Travis WD, Brambilla E, Müller-Hermelink HK, Harris CC, eds. *World Health Organization Classification of Tumours. Pathology and Genetics of Tumours of the Lung, Pleura, Thymus and Heart*. 1st ed. Lyon: IARC Press; 2004. p.141-4.
- Hainaut P, Lesage V, Weynand B, Coche E, Noirhomme P. Calcifying fibrous pseudotumor (CFPT): a patient presenting with multiple pleural lesions. *Acta Clin Belg* 1999;54(3):162-4.

6. Ammar A, El Hammami S, Horchani H, Sellami N, Kilani T. Calcifying fibrous pseudotumor of the pleura: a rare location. *Ann Thorac Surg* 2003;76(6):2081-2.
7. Jang KS, Oh YH, Han HX, Chon SH, Chung WS, Park CK, et al. Calcifying fibrous pseudotumor of the pleura. *Ann Thorac Surg* 2004;78(6):e87-8.
8. Kawahara K, Yasukawa M, Nakagawa K, Katsura H, Nagano T, Iwasaki T. Multiple calcifying fibrous tumor of the pleura. *Virchows Arch* 2005;447(6):1007-8.
9. Mito K, Kashima K, Daa T, Kondoh Y, Miura T, Kawahara K, et al. Multiple calcifying fibrous tumors of the pleura. *Virchows Arch* 2005;446(1):78-81.
10. Shibata K, Yuki D, Sakata K. Multiple calcifying fibrous pseudotumors disseminated in the pleura. *Ann Thorac Surg* 2008;85(2):e3-5.
11. Suh JH, Shin OR, Kim YH. Multiple calcifying fibrous pseudotumor of the pleura. *J Thorac Oncol* 2008;3(11):1356-8.
12. Isaka M, Nakagawa K, Maniwa T, Saisho S, Ohde Y, Okumura T, et al. Disseminated calcifying tumor of the pleura: review of the literature and a case report with immunohistochemical study of its histogenesis. *Gen Thorac Cardiovasc Surg* 2011;59(8):579-82.
13. Jiang K, Nie J, Wang J, Li J. Multiple calcifying fibrous pseudotumor of the bilateral pleura. *Jpn J Clin Oncol* 2011;41(1):130-3.
14. Ağaçkırın Y, Fındık G, Aydogdu K, Günay E, Günay S, Kaya S. An extremely rare case of multiple calcifying tumor of the pleura. *Tuberk Toraks* 2012;60(4):385-8.
15. Van Dorpe J, Ectors N, Geboes K, D'Hoore A, Sciort R. Is calcifying fibrous pseudotumor a late sclerosing stage of inflammatory myofibroblastic tumor? *Am J Surg Pathol* 1999;23(3):329-35.