

Value of Nucleolar Organizer Region Counts in Inflammatory, Pre-Malignant and Malignant Lesions of the Uterine Cervix

UTERİN SERVİKSİN İNFLAMATUAR, PRE-MALİGN VE MALİGN LEZYONLARINDA NUKLEOLAR ORGANİZER BÖLGE SAYILARININ DEĞERİ

B.Handan ÖZDEMİR*, Ayşe SERTÇELİK*

*Dept. of Pathology, Medical School of Ankara University, Ankara, TURKEY

Summary

Aim: The aim of the present study was to assess the diagnostic value of silver stained nucleolar organizer region associated proteins (AgNOR) in a variety of benign and malignant cervical lesions.

Material and Method: 42 routinely processed benign and malignant cervical lesions were evaluated by AgNOR method. 10 were totally benign, 10 had cervical intraepithelial neoplasia I (CTN I), 8 CIN II, 6 CIN III and finally 8 patients had cervical squamous epithelial carcinoma.

Result: Statistically significant differences were found between AgNOR indices of inflammatory lesions of the cervix and CIN ($p<0.001$), CIN and malignant lesions ($p<0.001$), inflammatory lesions and malignant lesions ($p<0.001$). Also a significant difference was found between AgNOR indices of CIN I and CIN III lesions. However an overlap was found in AgNOR indices between CIN I and CIN II and between CIN II and CIN III ($p>0.05$).

Conclusion: AgNOR indices in non-neoplastic cervical epithelium is different from that seen in the neoplastic epithelium. Counting of AgNORs may be useful in the differential diagnosis between benign, pre-malignant and malignant uterine cervical lesions.

Key Words: Nucleolar organizer region,
Cervical intraepithelial neoplasia,
Cervical lesions

T Klin J Med Res 2000, 18:79-83

Received: Dec. 22,1999

Correspondence: B. Handan ÖZDEMİR
Bağlar Caddesi 194-6
06700, GOP, Ankara, TURKEY

T Klin J Med Res 2000, 18

Özet

Amaç: Bu çalışmanın amacı, 42 adet benign ve malign servikal lezyonda, gümüş ile boyanmış nukleolar organizör bölge ile ilişkili proteinlerin tamsal değerini araştırmaktır.

Materyel ve Method: Rutin olarak çalışılmış 42 adet benign ve malign servikal lezyonu AgNOR metodu ile değerlendirildi. 10 vaka tamamen benign nitelikte idi, geri kalan vakaların 10'unda servikal intraepitelyal neoplazi I (CİN I), 8'inde CİN II, 6'sında CİN III ve 8 hastada servikal skuamöz epitelyal karsinoma mevcuttu.

Bulgular: Serviksin inflamatuvar lezyonlar ve CİN ($p<0.001$), CİN ve malign lezyonlar ($p<0.001$), inflamatuvar lezyonlar ve malign lezyonlar ($p<0.001$) arasında AgNOR değerleri açısından istatistiksel olarak anlamlı farklılık bulunmuştur. Aynı zamanda CİN I ve CİN III lezyonlarının AgNOR değerleri arasında da belirgin farklılık bulunmuştur. Bununla beraber CİN I ve CİN II ile CİN II ve CİN III lezyonlarının AgNOR değerleri arasında çakışma saptanmıştır ($p>0.05$).

Sonuç: Non-neoplastik servikal epitelde bulunan AgNOR değerleri neoplastik epitelde farklıdır. AgNOR sayımı benign, pre-malign ve malign uterin servikal lezyonların ayıncı tanısında yararlı olabilir.

Anahtar Kelimeler: Nukleolar organizör bölge,
Servikal intraepitelyal neoplazi,
Servikal lezyonlar

T Klin Araştırma 2000, 18:79-83

In recent years silver staining of the nucleolar organizer region (NOR) associated proteins (AgNOR) in interphase cells has become a widely used alternative method for assessing proliferation

in tumor pathology (1,2). NOR's are loops of ribosomal RNA. Specifically associated with NOR's are acidic proteins, probably sub units of DNA and RNA polymerase 1 that modulate the transcription of ribosomal DNA or maintain its extended configuration (3). AgNOR quantity has been found directly related to the population doubling time in human tumor cell lines in vitro and also allows estimation of the rapidity of the cell cycle in routinely processed histological sections (4,5).

AgNOR counts have been used in several studies to compare benign and malignant lesions and also as prognostic indicators in malignancy. The objective of our study was to distinguish the differences between pre-neoplastic and neoplastic lesions in the cervix by using argyrophil staining method.

Material and Method

Fortytwo specimens with known cervical pathology were studied. These specimens were obtained by biopsy or hysterectomy in our department. The pathological diagnosis was made from H&E slides by two pathologists. There were 10 chronic inflammation, 10 Cervical intraepithelial neoplasia I (CIN I), 8 CIN II, 6 CIN III and 8 well differentiated squamous cell carcinoma of the uterine cervix.

All specimens were fixed in 10% formalin and processed to paraffin wax. Sections were cut in thickness of 4µ and stained with AgNOR method (6). Briefly, sections were exposed to a silver colloid solution comprising 2g/dl gelatine in 1 ml/dl aqueous formic acid. This solution was mixed with twice its volume of 50 g/dl aqueous silver nitrate solution. The method was run for 30 min at room temperature in the dark room.

The AgNORs were counted according to the recommendations of Crocker et al (7). AgNORs both within and outside nucleoli were enumerated as separate entities and included in the count. AgNOR counting was done after sharp focusing on the nuclear membrane and fine granular nuclear matrix, using an oil immersion lens at a magnification of X1000, as described previously (8). In all lesions the number of AgNOR dots in 100 cells were randomly counted. The mean number of AgNORs per nucleus calculated for each specimen. The re-

Table 1. Silver stained NORs per nucleus in inflammatory, pre-neoplastic and neoplastic uterine cervical lesions

	N	%	AgNOR
Chronic cervicitis	10	23.8	1.9±0.2
CIN I	10	23.8	2.1±0.4
CIN II	8	19.05	3.6±0.5
CIN III	6	14.3	4.3±0.3
Invasive Ca	8	19.05	6.8±1.7

suiting data were analyzed by Kruskal Wallis and Mann Whitney U test.

Results

Based on cervical pathology, the cases were classified into three groups; group I: inflammatory lesions, group II: cervical intraepithelial neoplasia (CIN) and group III: invasive squamous cell carcinoma.

AgNORS were clearly recognised as black dots in cell nuclei (Figure 1,2). The mean number of AgNORs of inflammation, pre-malignant and malignant lesions of the uterine cervix were summarised in Table 1. As shown in Table 1, the mean number of AgNORs in inflammatory lesions were very low. The number of AgNORs tended to increase with the progression of the CIN from grade I to grade III. The mean AgNOR count were 1.9±0.2 for inflammatory lesions, 3.4±0.7 for CIN lesions and 6.8±1.7 for malignant lesions. The statistical analyses showed significant variations in AgNOR counts between the three study groups. When the groups were analyzed by means of Mann Whitney U test a significant difference was found between inflammatory lesions of the cervix and CIN ($p<0.001$), CIN and malignant lesions ($p<0.001$), inflammatory lesions and malignant lesions ($p<0.001$).

Subgroup analysis was also done on comparing lesions classified as CIN I with CIN II and CIN III. No significant difference was noticed between patients with CIN I and CIN II, and between patients with CIN II and CIN III ($p>0.05$). But a significant difference was observed between patients

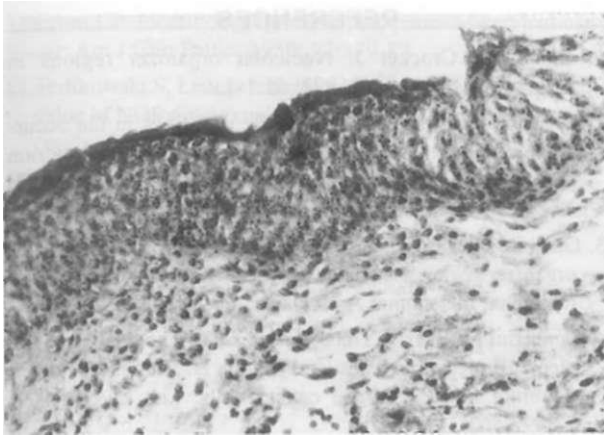


Figure 1. Silver stained nucleolar organizer regions in CIN III lesion. There is generally smaller numbers of silver-stained organizer regions within nuclei than malignant lesions and bigger numbers than other pre-malignant and benign lesion. X 100.

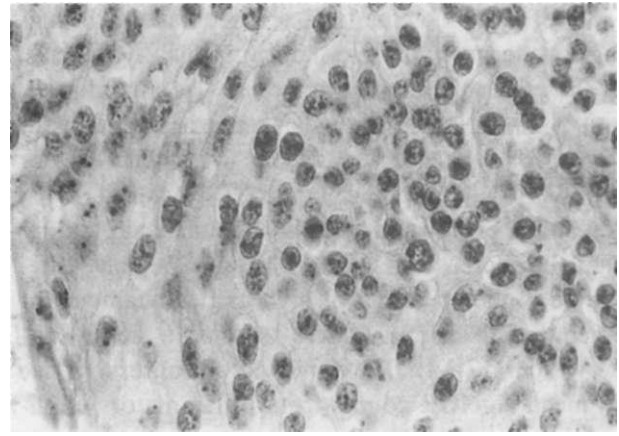


Figure 2. Silver-stained nucleolar organizer regions in well differentiated squamous cell carcinoma of cervix. Nucleolar aggregates are prominent. Individual intra nucleolar dots are discernible and more conspicuous than in benign nuclei. X 400.

with CIN I and CIN III ($p < 0.01$). No overlap was found in any case between CIN I and CIN III lesions. Similarly, a comparison was made between invasive carcinoma with CIN III and a significant difference was noticed between them ($p < 0.01$). In addition, the cut off point between CIN III and invasive carcinoma was found to be 5.1. The mean numbers of AgNORs in all cases with CIN III lesions were below than 5.1, whereas mean numbers of AgNORs in all cases with invasive carcinoma were greater than 5.1.

Discussion

Because cervical carcinoma develops in different stages, the early and accurate diagnosis of early grade cervical lesions is important, because of the possibility of progression. To evaluate the proliferation index of different grades of cervical lesions we studied AgNOR in cervical biopsies containing chronic cervicitis, CIN I, II or III and squamous cell carcinoma in current study. Staining with AgNOR expresses nuclear NOR's which form loops of ribosomal DNA. The information coded in this rDNA is transcribed to rRNA. The biologic significance of NOR's is related to their fundamental action during protein synthesis in cells (9). It has been reported that the number and/or size of the silver-binding black dots reflect the proliferative activity of malignant tissue (10,11).

The results of current study showed that the mean number of AgNORs in inflammatory, CIN and neoplastic lesions tended to increase with increasing neoplastic changes. Those in well differentiated squamous cell carcinoma and high grade squamous intraepithelial lesions (HSIL) (CIN II and III) the mean AgNOR index were significantly higher than those patients with inflammatory lesions and low grade squamous intraepithelial lesions (LSIL)(CIN I). We found that benign and malignant cervical lesions could clearly be separated by the mean number of AgNORs per cell. No overlap was found between LSIL and HSIL. This documents the diagnostic value of AgNOR in grading of intraepithelial lesions. We also suggested that it is possible to differentiate invasive carcinomas from HSIL by using cut off point of the mean AgNOR index, which was found to be 5.1 in our cases. The cut off point of the mean AgNOR index between cervical lesions were not given in previous studies. In routine study, it will not be appropriate to use the standard cut off point in every case in order to differentiate benign and malignant cervical lesions because of the methodological problems such as staining technique, variation in section thickness, and the diversity of counting techniques.

The cervical intraepithelial lesions were considered to be a direct precursor of well-differentiated squamous cell carcinoma of the cervix. The re-

suits of AgNOR counts in pre-neoplastic and malignant lesions tend to confirm this hypothesis. Although the number of our cases was small for appropriate statistical analysis, the higher numbers of AgNOR's in neoplastic lesions were clear in our study. Moreover, higher grade CIN lesions (HSIL) had highly elevated AgNOR counts, suggesting that the increase in AgNOR counts begins somewhere in the spectrum of high grade squamous intraepithelial lesions. Others reported a similar observation (12-14). They showed a progressive rise in mean AgNOR counts from inflammatory cervical tissue to CIN III. They suggested that this was a pattern related to potential for malignant evaluation of the lesion. Several other studies confirm such a view (15-18). Egan et al (15) showed a progressive rise in numbers of AgNORs from CIN I to CIN III. They also found significantly different AgNOR counts in human papilloma virus (HPV) infected cells and normal basal cells. Thus they suggested that diagnosis of HPV-infected cells could be made by comparing AgNOR counts. Egan et al has also shown that size of the AgNORs had diagnostic implications. They found that CIN III could be distinguished from CIN I and CIN II on the basis of AgNOR size and that an inverse relationship existed between AgNOR numbers and size (16). Recently similar observation about the size of AgNORs was found in the electron microscopic examination of AgNORs in cervical adenocarcinomas (19). In the study of Kaneko et al, a significant positive correlation of the BrdU labeling index, PCNA labeling index and the number of AgNORs in cervical intraepithelial neoplasia was found (20). They concluded that the number of AgNORs is related to the rapidity of cell proliferation. Crum et al found statistically significant correlation between AgNOR counts and tumor progression (17). All these observations suggest that AgNOR counts may be of significance in the evaluation of cervical carcinogenesis (17).

In conclusion, because nuclear and nucleolar characteristics are included in the grading of CIN and invasive carcinomas, we hoped that the AgNOR technique would be helpful in the evaluation of these lesions. Counting AgNORs may be useful in the differential diagnosis between benign, pre-malignant and malignant uterine cervical lesions.

REFERENCES.

1. Egan MJ, Crocker J. Nucleolar organizer regions in Pathology. *Br J Cancer* 1992; 65:1-7.
2. Leek RD, Alison MR, Sarraf CE. Variations in the occurrence of silver staining nucleolar organizer regions in non proliferating and proliferating tissues. *J Pathol* 1991; 165: 43-51.
3. Gambini C, Casazza S, Borgiani L. Counting the nucleolar organizer region associated proteins is a prognostic clue of malignant melanoma. *Arch Dermatol* 1992; 128:487-90.
4. Derenzini M, Sirri V, Trere' D, Ochs RL. The quantity of nucleolar proteins nucleolin and protein B23 is related to cell doubling time in human cancer cells. *Lab Invest* 1995; 73:497-502.
5. Derenzini M, Pession A, Trere' D. The quantity of nucleolar silver stained proteins is related to proliferating activity in cancer cells. *Lab Invest* 1990; 63:137-40.
6. Smith R, Crocker J. Evaluation of the nucleolar organizer region associated protein in breast malignancy. *Histopathology* 1988;12:113-25.
7. Crocker J, Boldy DAR, Egan MJ. How should we count AgNORs? Proposal for a standardized approach. *J Pathol* 1989; 158:185-8.
8. Hansen AB, Ostergard B. Nucleolar organizer regions in hyperplastic and neoplastic prostatic tissue. *Virchows Archiv. Pathol Anat* 1990;417:9-13.
9. Crocker J. Nucleolar organizer regions. In Underwood JCE (ed): *Pathology of the nucleus*. London, UK, Springer-Verlag, 1990: 91-149.
10. Chomette GP, Aurioi MM, Labrousse F et al. Mucoepidermoid tumors of salivary glands: Histoprognostic value of NOR's stained with AgNOR technique. *J Oral Pathol* 1991; 20:130-2.
11. Sano K, Takahashi H, Fujita S et al. Prognostic implication of silver-binding nucleolar organizer regions (AgNORs) in oral squamous cell carcinoma. *J Oral Pathol* 1991; 20:53-6.
12. Leopardi O, Colavecchio A, Colecchia M, Dede A. Value of AgNOR counts in cervical pathology. *Eur J Gynecol Oncol* 1992; 6:539-44.
13. Lahshmi S, Nair A, Jayasree K, Jayaprakash PG, Rajalekshmy TN, Kannan S, Pillai R. Argyrophilic nucleolar organizer regions (AgNORs) in inflammatory pre-malignant and malignant lesions of the uterine cervix. *Cancer Letter* 1993; 71:197-201.
14. Kobayashi I, Matsuo K, Ishibashi Y, Kanda S, Sakai H. The proliferative activity in dysplasia and carcinoma in situ of the uterine cervix analyzed by proliferating cell nuclear antigen immunostaining and silver-binding Argyrophilic nucleolar organizer region staining. *Human Pathol* 1994; 25: 198-202.
15. Egan M, Freeth M, Crocker J. Intraepithelial neoplasia, human papilloma virus infection and argyrophilic nucleoprotein in cervical epithelium. *Histopathology* 1988; 13:561.
16. Egan M, Freeth M, Crocker J. The relationship between cervical intraepithelial neoplasia and the size and numbers of nucleolar organizer regions. *Gynecol Oncol* 1990; 36: 30.

17. Crum CP Identifying high risk precursors of cervical cancer. *Am J Clin Pathol* 1989; 92:379-82.
18. Terlikowski S, Lenczewski A, Sulkowski S et al. Diagnostic value of NORs in premalignant and malignant lesions of the cervix. *Ginekol Pol* 1998; 69:232-6.
19. Yokoyama Y, Takahashi Y, Serda D et al. Silver-stained nucleolar organizer regions in adenocarcinoma of the cervix - a light and electron microscopic study. *Patholo Res Pract* 1997; 193:275-81.
20. Keneko S, Izutsu T. Use of bromodeoxyuridine, proliferating cell nuclear antigen, and nucleolar organizer regions in the multiparametric assessment of proliferating potency in cervical intraepithelial neoplasia. *J Obstet Gynaecol* 1995; 21:133-44.