

# A Rare Cause of Eyelid Mass: Juvenile Xanthogranuloma

## Göz Kapağında Kitlenin Nadir Bir Sebebi: Juvenil Ksantogranülom

 Bilge TARIM<sup>a</sup>,  Nilay YÜKSEL<sup>a</sup>

<sup>a</sup>University of Health Sciences Ankara Bilkent City Hospital, Department of Ophthalmology, Ankara, Türkiye

This case report was presented as an oral presentation at Turkish Ophthalmology Association 42nd April Course, April 7-9, 2023, Ankara, Türkiye

**ABSTRACT** A 40-year-old female patient presented with a complaint of a mass on her right lower eyelid, which had been present for 1 year and had increased in size over the last month. She had previously received several topical and systemic treatments with a diagnosis of chalazion. Upon examination, a round, elevated, yellow-colored mass measuring 1×1 cm was noted on the lateral part of the right lower eyelid, including the eyelid margin. There was a hemorrhagic crust and eyelash loss on the lesion. The patient underwent an excisional biopsy, and the lesion was sent for histopathologic examination. Histopathology revealed that the cells of the lesion were widely positive for CD68, while Langerin, CD1A, and S100 were negative. This finding was consistent with a juvenile xanthogranuloma. On the 15th day post-operation, a recurrence was observed, and a re-excision was performed, with the injection of 0.1 cc of dexamethasone subcutaneously. No recurrence was observed at the 6-month follow-up.

**Keywords:** Eyelid neoplasms; juvenile xanthogranuloma; biopsy; non-Langerhans cell histiocytosis

**ÖZET** Kırk yaşında bir kadın hasta, sağ alt göz kapağında 1 yıldır var olan ve son 1 ay içinde boyutu giderek artan bir kitle şikâyetiyle kliniğimize başvurdu. Daha önceden şalazyon tanısı ile birçok topikal ve sistemik tedavi alma öyküsü mevcuttu. Muayenede, sağ alt göz kapağının lateralinde, kapak kenarını da içine alan 1×1 cm boyutunda, yuvarlak, yüzyden kabarık, sarı renkli bir kitle fark edildi. Lezyon üzerinde hemorajik bir kurut ve lezyonun olduğu bölgede kirpik kaybı vardı. Lezyondan histopatolojik inceleme yapılması üzerine eksizyonel biyopsi yapıldı. Histopatolojik incelemede, hücrelerin büyük ölçüde CD68 ile pozitif olduğu, Langerin, CD1A (Langerhans hücre belirteçleri) ve S100'ün negatif olduğu saptandı. Bu bulgu, juvenil ksantogranülom tanısı ile uyumluydu. Hastanın takipleri sırasında postoperatif 15. günde nüks ortaya çıkması üzerine lezyona re-eksizyon yapılarak o bölgeye subkütan 0,1 cc deksametazon enjekte edildi. Hastada 6 aylık takipte herhangi bir nüks gözlenmedi.

**Anahtar Kelimeler:** Göz kapağı tümörleri; juvenil ksantogranülom; biyopsi; Langerhans dışı hücreli histiyositoz

Juvenile xanthogranuloma (JXG) is a rare and benign disease that falls within the category of cutaneous non-Langerhans cell histiocytosis.<sup>1</sup> While the majority of reported cases are seen in infancy and early childhood, there have been reports of late-onset presentations.<sup>2-4</sup> Eyelid involvement is the rarest among ocular involvements. Clinically, cutaneous lesions are often misdiagnosed as other common eyelid conditions. Several treatment options have been described to date. Recurrences may occur after primary treatment and need further interventions.<sup>5</sup> In

this report, we present an adult patient with JXG of the eyelid, which recurred after primary surgical excision and discuss its management.

### CASE REPORT

All authors declare that informed consent was obtained from the patient to publish this case report and all the information and images belong to the case.

A 40-year-old female patient presented with a complaint of a mass on her right lower eyelid that had

**Correspondence:** Bilge TARIM

University of Health Sciences Ankara Bilkent City Hospital, Department of Ophthalmology, Ankara, Türkiye

**E-mail:** bilge\_basciftci@hotmail.com

Peer review under responsibility of Türkiye Klinikleri Journal of Ophthalmology.

**Received:** 26 Dec 2023

**Accepted:** 04 Apr 2024

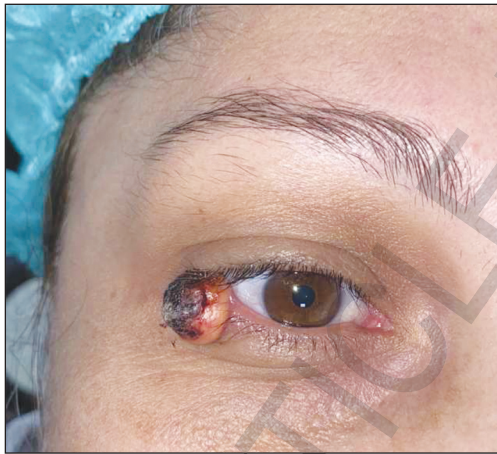**Available online:** 08 May 2024

2146-9008 / Copyright © 2024 by Türkiye Klinikleri. This is an open access article under the CC BY-NC-ND license (<http://creativecommons.org/licenses/by-nc-nd/4.0/>).



been present for one year and had noticed an increase in size over the last month. She had previously received several topical and systemic treatments with a diagnosis of chalazion. The patient had no significant systemic or ocular disease. Upon examination, we observed a round, elevated, yellow-colored mass measuring 1×1 cm on the lateral part of the right lower eyelid, including the eyelid margin (Figure 1). The lesion exhibited a hemorrhagic crust and eyelash loss.

The differential diagnosis included chalazion, sebaceous cyst, actinic keratosis, pyogenic granuloma and all types of eyelid malignancies. The patient underwent an excisional biopsy and the lesion was sent for histopathologic examination (Figure 2). Histopathology results indicated that the cells of the lesion were strongly positive with CD68, while Langerin, CD1A which are Langerhans cell markers, and S100 were negative, consistent with a diagnosis of JXG.



**FIGURE 1:** A round, elevated yellow-orange mass of approximately 1×1 cm in diameter, with well-defined borders on the lateral region of the right lower eyelid including eyelid margin.

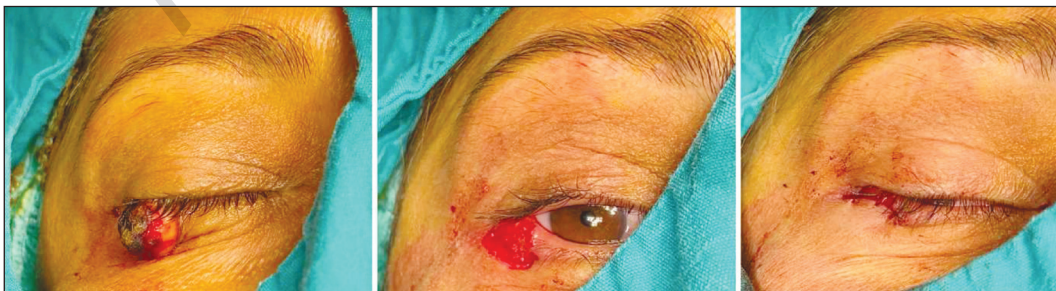On the 15<sup>th</sup> day after the initial operation, we observed a recurrence and subsequently conducted a re-excision, complemented by a subcutaneous injection of 0.1 cc of dexamethasone (Figure 3A). No further recurrence was observed at the 6-month follow-up (Figure 3B).

## DISCUSSION

Histiocytosis syndromes are categorized into 3 groups: Langerhans cell histiocytosis (L group), non-Langerhans cell histiocytosis (C group), and malignant histiocytosis (M group). Non-Langerhans cell histiocytosis is primarily localized to the skin and mucosal surfaces, and JXG, a benign disorder, falls within this group.<sup>1</sup>

The majority of JXGs are typically observed between the ages of 1 and 6, with a higher occurrence in the first year of life. However, it is worth noting that JXG can also occur in adults, although less frequently, and such cases occurring in the third decade and later are referred to as adult xanthogranulomas.<sup>6</sup> While approximately 90% of JXGs manifest in the head and neck region, ocular involvement is relatively rare.<sup>5</sup> Ocular involvement of JXG is more commonly found in the iris (68%) and conjunctiva (19%).<sup>7,8</sup> However, eyelid involvement, although the rarest form (6%), generally carries a more benign prognosis compared to other ocular manifestations.

Clinically, juvenile and adult xanthogranulomas are most commonly observed on the skin and as a solitary lesion. In a study that analyzed 13 cases of JXGs on the eyelid, the median age at which the disease manifested was 9 years (range: 1.2-47.0).<sup>9</sup> Within the same study, an additional 19 eyelid JXG



**FIGURE 2:** Intraoperative images show the excision of the mass and the suturing of the eyelid margin.

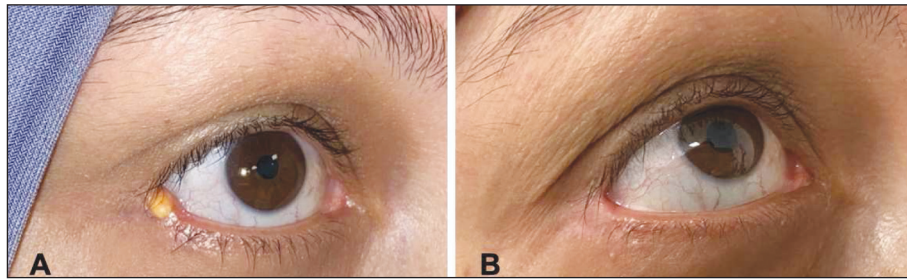


FIGURE 3: A) Recurrence occurring on the post-operative 15<sup>th</sup> day, B) Normal eyelid margin without recurrence at the 6<sup>th</sup> month follow-up.

cases from the literature were examined as a separate group, and the median age in this group was 2 years (range: 0.5-46.0). Among the 32 cases, the most common localization of lesions was the upper eyelid (62.5%), followed by the lower eyelid (31.25%), and the medial canthus (6.25%). In our case, the lesion was located in the lateral region of the lower eyelid. While the lesion had been present for 1 year in our case, the median duration of symptoms in the 32 cases reviewed was 6 months (range: 0.5-12). Furthermore, as observed in our case, histopathological evaluation of all cases in the review revealed negativity for CD1 and S100, while CD68 was consistently positive.

Adult onset xanthogranuloma affecting the eyelid is extremely rare. Chalfin and Lloyd diagnosed a case of solitary adult-onset xanthogranuloma in a 24-year-old Caucasian man.<sup>2</sup> They performed an excisional biopsy on a painless, solitary, non-tender mass on the upper eyelid, which had a 2-month history, leading to both diagnosis and treatment. Wiffen et al. reported the case of a 29-year-old female patient diagnosed with adult-onset xanthogranuloma, who presented with the complaint of a mass on her left upper eyelid.<sup>3</sup> Initially, the lesion was misdiagnosed as pyogenic granuloma, and intralesional triamcinolone was applied twice, with an interval of one month. An incisional biopsy was performed due to the lack of improvement in the lesion, and histology confirmed the diagnosis of JXG. Subsequently, the lesion was completely excised, and no recurrence was observed during the 3-month follow-up. Chiang et al. reported the case of a 46-year-old male patient with a mass on the right upper eyelid, which had been present for 1 year, and was clinically thought to be a papillary lesion.<sup>4</sup> However, histopathologic examination revealed a cu-

taneous granuloma after an excisional biopsy.

JXGs seen in childhood are benign lesions that typically regress spontaneously within 1-2 years.<sup>10</sup> While a conservative treatment approach is generally favored for children, in cases of persistent xanthogranulomas, especially in individuals aged 20 and older, excision of the lesion is recommended.<sup>11</sup> Considering that any lesion involving the eyelid can be malignant, benign, inflammatory, or non-inflammatory, it is important to include a wide range of possibilities in the differential diagnosis of JXG. An excisional biopsy is a valuable diagnostic and therapeutic approach in such cases. In our specific case, JXG was not initially among the preliminary diagnoses, and the precise diagnosis was established through histopathological evaluation following the excisional biopsy. In the existing literature, various treatment modalities have been documented, including intralesional steroids, low-dose radiotherapy, and laser ablation. Recurrence is relatively infrequent in different ocular manifestations of JXG. In recurrent cases, topical or intralesional corticosteroid treatment can be employed, while low-dose radiation or local cryotherapy may be considered as treatment options for resistant cases.<sup>5</sup> In our case, recurrence was observed as early as 15 days post-operatively. However, no recurrence was noted during the 6-month follow-up period following re-excision and subcutaneous steroid injection.

In conclusion, eyelid lesions can sometimes closely resemble each other. While JXG is a rare cause of eyelid lesions, particularly in adults, it should be considered in the differential diagnosis. Histopathological examination remains the most reliable method for confirming unexpected diagnoses.

### Source of Finance

During this study, no financial or spiritual support was received neither from any pharmaceutical company that has a direct connection with the research subject, nor from a company that provides or produces medical instruments and materials which may negatively affect the evaluation process of this study.

### Conflict of Interest

No conflicts of interest between the authors and / or family members of the scientific and medical committee members or members of the potential conflicts of interest, counseling, expertise,

working conditions, share holding and similar situations in any firm.

### Authorship Contributions

**Idea/Concept:** Nilay Yüksel; **Design:** Bilge Tarım; **Control/Supervision:** Nilay Yüksel; **Data Collection and/or Processing:** Bilge Tarım; **Analysis and/or Interpretation:** Nilay Yüksel; **Literature Review:** Bilge Tarım; **Writing the Article:** Bilge Tarım; **Critical Review:** Nilay Yüksel, Bilge Tarım; **References and Fundings:** Nilay Yüksel, Bilge Tarım; **Materials:** Nilay Yüksel, Bilge Tarım.

## REFERENCES

1. Emile JF, Ablá O, Fraitag S, Home A, Haroche J, Donadieu J, et al; Histiocyte Society. Revised classification of histiocytoses and neoplasms of the macrophage-dendritic cell lineages. *Blood*. 2016;127(22):2672-81. PMID: 26966089; PMCID: PMC5161007.
2. Chalfin S, Lloyd WC 3rd. Juvenile xanthogranuloma of the eyelid in an adult. *Arch Ophthalmol*. 1998;116(11):1546-7. PMID: 9823370.
3. Wiffen J, Kalantary A, Ardakani NM, Turner A. Adult onset xanthogranuloma of the eyelid. *Am J Ophthalmol Case Rep*. 2022;29:101775. PMID: 36544751; PMCID: PMC9762145.
4. Chiang E, Lissner G, Bryar PJ. Unusual presentation of xanthogranuloma on the eyelid of an adult. *Ophthalmic Plast Reconstr Surg*. 2014;30(6):e155-6. PMID: 24801255.
5. Samara WA, Khoo CT, Say EA, Saktanasate J, Eagle RC Jr, Shields JA, et al. Juvenile xanthogranuloma involving the eye and ocular adnexa: tumor control, visual outcomes, and globe salvage in 30 patients. *Ophthalmology*. 2015;122(10):2130-8. PMID: 26189188.
6. Tahan SR, Pastel-Levy C, Bhan AK, Mihm MC Jr. Juvenile xanthogranuloma. Clinical and pathologic characterization. *Arch Pathol Lab Med*. 1989;113(9):1057-61. PMID: 2505733.
7. Flockerzi E, Hager T, Seitz B. Intraocular juvenile xanthogranuloma of the iris in an adult patient. *Am J Ophthalmol Case Rep*. 2016;5:73-5. PMID: 29503951; PMCID: PMC5758008.
8. Lee KM, Wee WR, Lee JH, Kim MK. Juvenile xanthogranuloma presenting as infiltrative conjunctival mass in an adult. *Cornea*. 2012;31(4):447-9. PMID: 22222998.
9. Chen R, Liu S, Tang L, Yu X, Meng Z, Hu Y, et al. On the knowledge of solitary juvenile xanthogranuloma of the eyelid: a case series and literature review. *Graefes Arch Clin Exp Ophthalmol*. 2022;260(7):2339-45. PMID: 35084531; PMCID: PMC9203400.
10. Haggmann C, El-Bahrawy M, Stamp G, Abel RM. Juvenile xanthogranuloma: a case report of a preterm baby. *J Pediatr Surg*. 2006;41(3):573-5. PMID: 16516638.
11. Cohen BA, Hood A. Xanthogranuloma: report on clinical and histologic findings in 64 patients. *Pediatr Dermatol*. 1989;6(4):262-6. PMID: 2515528.