

Choroidal Thickness in Primary Open Angle Glaucoma and Pseudoexfoliative Glaucoma: An EDI-OCT Approach

Primer Açık Açılı Glokom ve Psödoeksfoliyatif Glokomda Koroid Kalınlığı: Bir EDI-OCT Yaklaşımı

^{id} Müberra AKDOĞAN^a, ^{id} Merve ŞİMŞEK^a, ^{id} Hamidu Hamisi GOBEKA^b, ^{id} A. Yeşim ORAL^a

^aDepartment of Ophthalmology, Afyonkarahisar Health Sciences University Faculty of Medicine, Afyonkarahisar, TURKEY

^bDepartment of Ophthalmology, Ağrı İbrahim Çeçen University Faculty of Medicine, Ağrı, TURKEY

ABSTRACT Objective: To investigate choroidal changes in pseudoexfoliative glaucoma and primary open angle glaucoma using enhanced depth imaging optical coherence tomography (EDI-OCT). **Material and Methods:** Ninety eyes of 90 participants, 30 of whom had pseudoexfoliative glaucoma (Group 1), 30 had primary open angle glaucoma (Group 2) and 30 were healthy subjects (Group 3) were investigated between June and September 2019. Pseudoexfoliative glaucoma and primary open angle glaucoma patients received only brimonidine tartrate and/or brinzolamide/dorzolamide and timolol maleate combination therapy during the study. Peripapillary retinal nerve fibre layer and subfoveal choroidal thickness with and without EDI mode of SD-OCT, central corneal thickness and intraocular pressure were compared among groups. **Results:** Mean age for each group was 56.12±11, 53.89±7 and 52.86±6 (±standard deviation) years in Groups 1, 2 and 3, respectively (p=0.110). Although Group 1 had retinal nerve fibre layer value of 72.9±20 µm, this was as high as 92±14 µm and 97.3±13 µm in Groups 2 and 3, respectively (p=0.001). Choroidal thickness measured using SD-OCT with and without EDI mode was 192±49/193±48 µm in Group 1. However, Group 2 and Group 3 had roughly identical choroidal thickness of 289±40/294±39 µm and 292±47/297±47 µm, respectively (p=0.001). Mean intraocular pressure was 14.8±3, 14.4±2.7, and 11.7±1.4 mmHg in Groups 1, 2 and 3, respectively (p=0.072). Group 1 was associated with marginally thinner cornea of 522±34 µm compared to 560±24 µm and 575±18 µm in Groups 2 and 3, respectively (p=0.001). **Conclusion:** Glaucoma, especially pseudoexfoliative glaucoma, influences choroidal microcirculation and thus physiological and morphological alteration of the choroidal layer.

Keywords: Choroidal thickness; pseudoexfoliative glaucoma; retinal nerve fibre layer; spectral-domain optical coherence tomography; enhanced depth imaging

ÖZET Amaç: Psödoeksfoliyatif glokom ve primer açık açılı glokomlu gözlerde, geliştirilmiş derinlik görüntüleme optik koherens tomografi [enhanced depth imaging optical coherence tomography (EDI-OCT)] ile koroid değişikliklerini incelemek. **Gereç ve Yöntemler:** Haziran ve Eylül 2019 tarihleri arasında 30'u psödoeksfoliyatif glokom (Grup 1), 30'u primer açık açılı glokom (Grup 2) ve 30'u sağlıklı (Grup 3) olmak üzere 90 katılımcının 90 gözü incelendi. Psödoeksfoliyatif glokom ve primer açık açılı glokom hastaları, çalışma sırasında sadece brimonidin tartar ve/veya brinzolamid/dorzolamid ve timolol maleat kombinasyon tedavisi almıştır. Peripapiller retina sinir lifi tabakası ve EDI modu olan ve olmayan subfoveal koroid kalınlığı, santral kornea kalınlığı ve göz içi basıncı gruplar arasında karşılaştırıldı. **Bulgular:** Grup 1, 2 ve 3'te her grup için ortalama yaş sırasıyla 56,12±11; 53,89±7 ve 52,86±6 (±standart sapma) yılı (p=0,110). Grup 1'in retina sinir lifi tabakası değeri 72,9±20 µm olmasına rağmen bu değer sırasıyla Grup 2 ve 3'te 92±14 µm ve 97,3±13 µm idi (p=0,001). Grup 1'de EDI modu olan ve olmayan spektral-domain OCT kullanılarak ölçülen koroid kalınlığı 192±49 µm/193±48 µm idi. Bununla birlikte Grup 2 ve 3, sırasıyla 289±40/294±39 µm ve 292±47/297±47 µm'lik kabaca özdeş koroid kalınlığına sahipti (p=0,001). Grup 1, 2 ve 3'te ortalama göz içi basıncı sırasıyla 14,8±3; 14,4±2,7 ve 11,7±1,4 mmHg idi (p=0,072). Grup 2 ve 3'te sırasıyla 560±24 µm ve 575±18 µm olan korneal kalınlıklarına göre Grup 1'de 522±34 µm'lik marjinal olarak daha ince kornea ile ilişkili idi (p=0,001). **Sonuç:** Psödoeksfoliyatif glokom başta olmak üzere glokom koroidal mikrovasküler kan dolaşımını etkileyerek, koroidal tabakanın fizyolojik ve morfolojik değişimine yol açar.

Anahtar Kelimeler: Koroid kalınlığı; psödoeksfoliyatif glokom; retina sinir lifi tabakası; spektral-domain optik koherens tomografi; geliştirilmiş derinlik görüntüleme

Correspondence: Müberra AKDOĞAN

Department of Ophthalmology, Afyonkarahisar Health Sciences University Faculty of Medicine, Afyonkarahisar, TURKEY/TÜRKİYE

E-mail: mbrakdogan@yahoo.com



Peer review under responsibility of Türkiye Klinikleri Journal of Ophthalmology.

Received: 17 Oct 2020

Received in revised form: 14 Feb 2021

Accepted: 15 Feb 2021

Available online: 18 Feb 2021

2146-9008 / Copyright © 2021 by Türkiye Klinikleri. This is an open access article under the CC BY-NC-ND license (<http://creativecommons.org/licenses/by-nc-nd/4.0/>).

Pseudoexfoliative glaucoma (PEG) is characterized by accumulation of recurrent fibrogranular pseudoexfoliative material on the anterior lens capsule and/or pupil rim, typically in the elderly, along with high intraocular pressure (IOP).¹⁻³ Latest studies have documented changes in the photoreceptor layer of pigment epithelium and choroid in glaucoma including the inner retinal layer and retinal nerve fibre layer changes.⁴⁻⁷

Spectral-domain optical coherence tomography (SD-OCT) technology with enhanced depth imaging (EDI) mode has allowed repeated, automated and quantitative assessment of retinal nerve fibre layer and choroidal thickness, probably through exponential growth of the EDI system.⁸⁻¹²

The goal of this study was to investigate changes of choroidal thickness and retinal nerve fibre layer in patients with PEG and primary open angle glaucoma (POAG) using EDI-OCT with SD-OCT technology and to compare the data with healthy individuals.

MATERIAL AND METHODS

STUDY PARTICIPANTS

This cross-sectional case-control observational study included 60 patients (30 with PEG and 30 with POAG) and 30 healthy individuals aged between 40 and 85 years. The study was conducted between July and September 2019 at Afyonkarahisar University of Health Sciences Department of Ophthalmology. The study procedure complied with the ethical standards of the Helsinki Declaration and was fully endorsed by the Afyonkarahisar Health Sciences University Ethics Committee of the Institutional Review Boards (5 July 2019-2019/8) (2011-KAEK-2). Before obtaining consent, all participants were informed about the study.

INCLUSION AND EXCLUSION REQUIREMENTS

Patients without ocular pathology apart from the ocular surface disorders (including mild-moderate dry eye, allergic conjunctivitis and blepharitis), presbiopia, and refractive error between -1.0 and +1.0 diopter were included in the study. On the other hand, patients with higher choroidal thickness-related primary choroidal pathology, patients with diseases that

could impede imaging of the ocular posterior segment, including corneal disorders and cataract, patients using prostaglandin analogue, patients with systemic hypertension that could impair choroid blood flow and smoking history were excluded. During the study, POAG and PEG patients received only brimonidine tartrate and/or brinzolamide/dorzolamide plus timolol maleate combination therapy.

OCULAR EXAMINATION AND GLAUCOMA DIAGNOSIS

A comprehensive ophthalmological examination was performed, including measurements of the best-corrected visual acuity with Snellen charts and IOP with Goldmann applanation tonometer (Inami, Japan), slit-lamp biomicroscopy of the anterior and posterior segments before and after pupil dilation [0.5% tropicamide (Tropamid, Bilim, Turkey)], 2.5% phenylephrine 2.5% phenylephrine (Mydrin, Alcon, USA), central corneal thickness with ultrasonic pachymeter (Accutome Accupach VI) and gonioscopy with Goldmann triple mirror contact lens. PEG diagnosis involved the following criteria: (1) an identification of the extracellular fibrillar gray-white material on the lens capsule or iris sphincter region; (2) a presence of glaucomatous changes during optic nerve tissue analysis; (3) an existence of glaucomatous defects in the visual field studies; (4) a decreased retinal nerve fibre layer thickness along with elevated IOP.³ Further, POAG diagnosis involved the following criteria: (1) an absence of secondary glaucoma-causing factors such as PEG, pigmentary glaucoma, lens based glaucoma; (2) a presence of the defects in the visual field studies and glaucomatous findings in OCT scan; (3) a presence of an open iridocorneal angle during gonioscopy; and (4) the IOP values >21 mmHg. The visual field studies were obtained by using Humphrey automated perimetry central 30-2 program (Allergan-Humphrey, Inc., DSan Leandro, USA).

EDI-OCT WITH SD-OCT TECHNIQUE

The SD-OCT (Heidelberg Engineering GmbH; software ver. 1.4, 1.5) technique was used to scan 360° in order to measure the mean retinal nerve fibre layer thickness of 4 quadrants (superior, inferior, nasal, temporal), that is, superior-temporal: 45-90, superior-nasal: 90-135, infero-nasal: 225-270 as well as infero-temporal: 270-315. Signal power of each scan

was checked and discarded if <1.5 . The subfoveal choroidal thickness and volumes assessed by EDI-OCT were evaluated by comparing data acquired from nine sectors as indicated in the Early Treatment Diabetic Retinopathy Study location profile after breaking choroidal thickness manually and getting a center through a 3.45 mm region.¹² In order to obtain the most appropriate values, the choroidal thickness was calculated using linear mixed modeling with and without EDI mode. Meanwhile, the central cornea thickness was calculated using corneal ultrasonic pachymetry.

STATISTICAL ANALYSIS

All statistical analyses were conducted using SPSS 14.0 (SPSS Inc., Chicago, USA). The Kolmogorov-Smirnov test was used to determine whether or not the data displayed normal distribution. Quantitative parameters were calculated using a one-way ANOVA test among groups, and a post hoc Scheffe test was used to allow comparisons among groups.

RESULTS

There was no statistically significant difference among groups in age, sex ($p=0.110$) and IOP parameters ($p=0.593$). The retinal nerve fibre layer thickness (Figure 1), choroidal thickness measured with EDI and without EDI mode and the central cornea thickness ($p=0.001$) were statistically significantly different among groups (Figure 2 and Figure 3) (Table 1). However, an intergroup comparison between healthy individuals and POAG patients revealed no statistically significant difference in the retinal nerve fibre layer thickness ($p=0.425$), choroidal thickness measured with and without EDI mode ($p=0.974$ and $p=0.979$), and central cornea thickness ($p=0.016$). The comparison of healthy individuals and POAG patients, with PEG patients revealed statistically significant differences in the retinal nerve fibre layer thickness, choroidal thickness measured with and without EDI mode, and central cornea thickness ($p=0.001$) (Table 2).

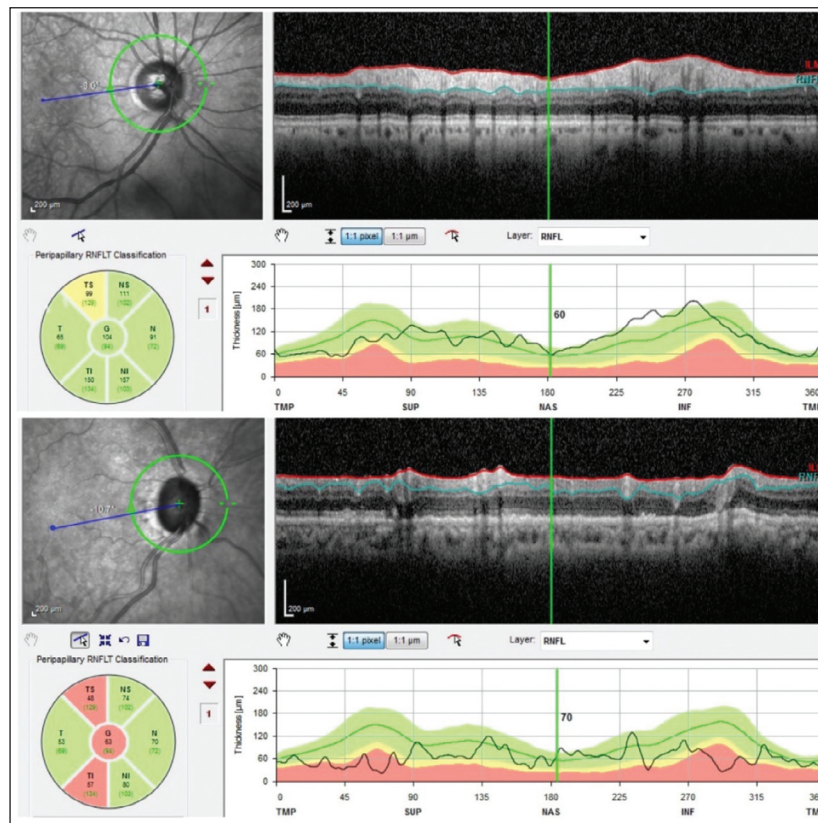


FIGURE 1: Illustration of retinal nerve fibre layer analysis of a patient with primary open angle glaucoma and pseudoexfoliative glaucoma.

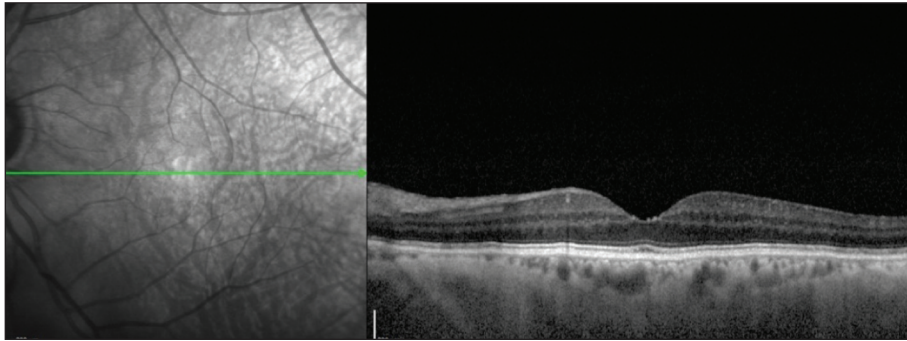


FIGURE 2: Illustration of choroidal thickness of a patient with primary open angle glaucoma measured using enhanced depth imaging optical coherence tomography.

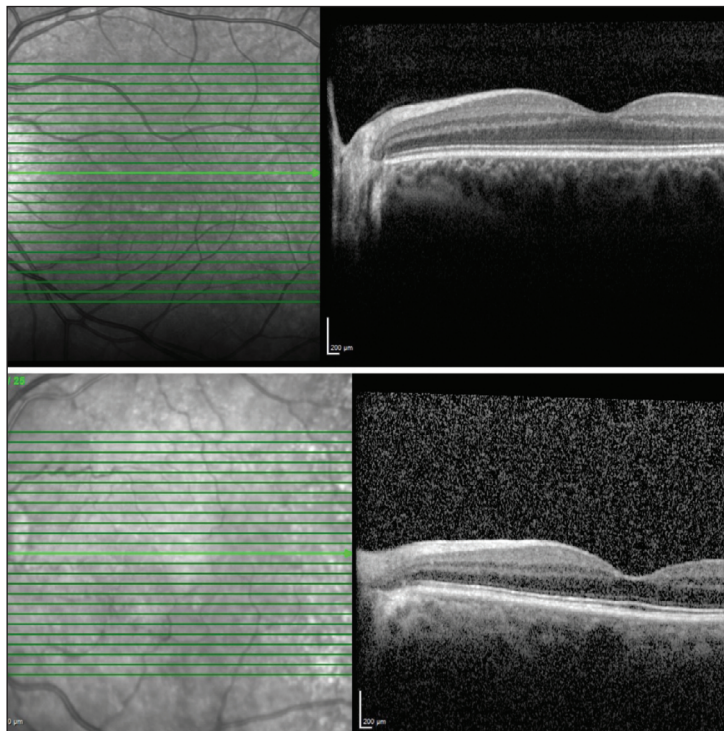


FIGURE 3: Illustration of choroidal thickness of healthy subject and a patient with pseudoexfoliative glaucoma measured using enhanced depth imaging optical coherence tomography.

DISCUSSION

Many PEG patients may develop glaucomatous damage due to an increased IOP and more extreme IOP variations especially in contrast to POAG. This condition demonstrates a somewhat rapid advancement and a poorer prognosis of PEG than POAG.^{13,14} At a predetermined IOP level, an optic nerve damage possibility has been reported to be greater in the eyes with pseudoexfoliation.¹⁵ Pseudoexfoliation syndrome is believed to be the most important indepen-

dent risk factor for glaucoma advancement.¹⁶ Moreover, the advancement of glaucoma has been reported to be as twice as high in patients with both ocular hypertension and pseudoexfoliation relative to patients with ocular hypertension alone. This indicates that factors other than IOP level may contribute to the pathogenesis of PEG.^{17,18} In this regard, the investigation of changes in the choroidal thickness and retinal nerve fiber layer in patients with PEG and POAG using EDI-OCT with SD-OCT technology, and a comparison of the data with healthy individuals has

TABLE 1: Study data of the respective groups.

Parameters	PEG (Group 1)	POAG (Group 2)	Control (Group 3)	p value
Age (years)	56.12±7	53.89±10	52.86±15	0.110
Gender (female/male)	14/16	16/14	15/15	0.076
Retinal nerve fibre layer (µm)	72.93±20	91.8±14	97.36±13	0.001
Choroidal thickness with EDI (µm)	193±48	294±39	297±47	0.001
Choroidal thickness without EDI (µm)	192±49	289±40	292±47	0.001
Intra ocular pressure (mmHg)	14.86±3	14.46±2.78	11.70±1.40	0.072
Central cornea thickness (µm)	524±34	554±24	575±18	0.001

POAG: Primary open angle glaucoma; PEG: Pseudoexfoliation glaucoma; EDI: Enhanced depth imaging; µm: Micrometer.

TABLE 2: Comparison of optical coherence tomography parameters of the groups concerned.

	Control/POAG	POAG/PEG	Control/PEG
Retinal nerve fibre layer (µm)	97.36±13/91.8±14 p=0.425	91.8±14/72.93±20 p=0.001	97.36±13/72.93±20 p=0.001
Choroidal thickness with EDI (µm)	297±47/294±39 p=0.974	294±39/193±48 p=0.001	297±47/193±48 p=0.001
Choroidal thickness without EDI (µm)	292±47/289±40 p=0.979	289±40/192±49 p=0.001	292±47/192±49 p=0.001
Central cornea thickness (µm)	575±18/554±24 p=0.979	575±18/524±34 p=0.001	554±24/524±34 p=0.001

POAG: Primary open angle glaucoma; PEG: Pseudoexfoliation glaucoma; EDI: Enhanced depth imaging; µm: Micrometer.

been conducted in the present study, in which age, sex and IOP did not differ significantly among groups. Most importantly, relative to healthy individuals and POAG patients, PEG patients revealed to have statistically significantly different retinal nerve fibre layer thickness, choroidal thickness measured with and without EDI mode, and central cornea thickness. A significantly decreased retinal nerve fibre layer thickness in the PEG patients may be considered as an effect of glaucoma. This condition result may signify early damage to the retinal nerve fiber even with normal IOP and normal visual field in the eyes of pseudoexfoliation syndrome. In addition, a significant decrease in choroid thickness measured with and without EDI mode in PEG patients demonstrates that ischemia could influence the duration of pseudoexfoliation and therefore contribute to the advancement of glaucoma. As far as the present study results are concerned, monitoring of the retinal nerve fibre thickness and choroidal thickness using EDI-OCT with SD-OCT technique in particularly PEG patients may be very useful for identifying advancement of glaucoma.

OCT is an advanced biomedical imaging technique which has been employed to a broad range of biological, clinical and material studies. This technique is similar to ultrasound B-mode imaging. However, apart from that, near-infrared light reflections are recorded in OCT instead of sound. OCT provides high-resolution, non-invasive real-time imaging of cell and tissue microstructures embedded inside densely scattered tissues. After its first presentation by Huang et al., this technology has revolutionized the diagnosis and treatment of retinal disorders as well as glaucoma. In addition, development of SD-OCT has provided repeated, automatic and quantitative measurement of peripapillary retinal nerve fibre layer thickness.¹⁹ The EDI-OCT, on the other hand, offers complete imaging and measurement of the subfoveal choroidal thickness. Peripapillary choroid is the primary source of blood transmission from the preliminary side of the optical nerve head. Recent studies have shown that various factors, including high myopia and age can be correlated with this region.^{12,20} In this regard, the study by Wu et al., published comparable results of peripapillary choroidal measurements with or without EDI mode.²¹

During measurement of retinal nerve fibre layer thickness using OCT, it has been reported that nearly 1 μm reduction in retinal nerve fibre layer thickness occurs per 10 years of age. There is also a strong degree of association between visual field tests and retinal nerve fibre layer thickness. Studies evaluating the relationship between retinal nerve fibre layer thickness and the global visual field index calculated using OCT in normal eyes, ocular hypertensive eyes, and POAG eyes reported substantial differences in retinal nerve fibre layer thickness among these eyes, and revealed an obvious correlation between these two parameters.^{21,22} It has been reported that when glaucoma is detected by visual field defect or optic nerve cupping, damage to retinal nerve fibre layer has already occurred in the range of 10-15%. Thus, examination of peripapillary retinal nerve fibre layer thickness using OCT can be implemented as an early diagnostic method not only for early diagnosis but also for monitoring glaucoma patients.²³

PEG represents approximately 25% of all definable glaucomas. A cross-sectional analysis of the relationship between pseudoexfoliation and open-angle glaucoma, ocular hypertension, and IOP in 3,654 people aged 49-97 years revealed a clear correlation between pseudoexfoliation and glaucoma. That glaucoma was approximately 8 times more prevalent in the eyes with pseudoexfoliation (14.2%) than in the eyes without pseudoexfoliation (1.7%) after age and sex adjustment.²² Another research conducted by Gorezis et al., comparing different forms of glaucoma reported a much thinner central cornea thickness in relation to PEG.²³ The present research confirmed the above finding that PEG patients were associated with thinner central cornea thickness compared to healthy individuals and POAG patients. That being said, there was no important difference in central cornea thickness between healthy individuals and POAG patients.

The relationship between pseudoexfoliation syndrome and hypoperfusion and stenosis of iris vessels, loss of normal radial iris vessels, and microneovascularisation has been reported before.^{24,25} Visontai et al., measured the typical carotid artery diameter and alteration of the arterial pulse in the control and pseudoexfoliation syndrome groups using a combination of ultrasonography and a vessel wall echo-tracking de-

vice.²⁶ They noted that the causes of vascular dysfunction were elaborated by evidence of increased stiffness and functional disorders in vessels. In view of this, the present study found that choroidal thickness, one of the most essential vascular structures in PEG patients, was significantly thinner compared to POAG patients and healthy subjects. These results support previous observations of morphological alteration of the macrovasculatures due to pseudoexfoliative material deposition. Despite this, there was no major difference between healthy individuals and POAG patients in terms of choroidal thickness with EDI mode. From a practical and physiological perspective, these data reinforce the earlier described epidemiological evidence regarding the relationship between systemic vascular diseases and pseudoexfoliation-related conditions, including PEG.

CONCLUSION

Patients with PEG were associated with decreased subfoveal choroidal thickness and retinal nerve fibre layer thickness relative to patients POAG and healthy individuals. But there was no substantial difference in choroidal thickness between patients with POAG and healthy individuals. Overall, these results demonstrate the influence of PEG on the choroidal microcirculation and therefore on the physiological and morphological changes of the choroid layer.

Source of Finance

During this study, no financial or spiritual support was received neither from any pharmaceutical company that has a direct connection with the research subject, nor from a company that provides or produces medical instruments and materials which may negatively affect the evaluation process of this study.

Conflict of Interest

No conflicts of interest between the authors and / or family members of the scientific and medical committee members or members of the potential conflicts of interest, counseling, expertise, working conditions, share holding and similar situations in any firm.

Authorship Contributions

Idea/Concept: Müberra Akdoğan, Merve Şimşek; **Design:** Müberra Akdoğan, Merve Şimşek; **Control/Supervision:** Müberra Akdoğan, Merve Şimşek; **Data Collection and/or Processing:** Merve Şimşek, Müberra Akdoğan; **Analysis and/or Interpreta-**

tion: Müberra Akdoğan, Merve Şimşek, Hamidu Hamisi Gobeka, A. Yeşim Oral; **Literature Review:** Müberra Akdoğan, Merve Şimşek, Hamidu Hamisi Gobeka; **Writing the Article:** Müberra Akdoğan, Merve Şimşek, Hamidu Hamisi Gobeka; **Critical Re-**

view: Müberra Akdoğan, Merve Şimşek, Hamidu Hamisi Gobeka, A. Yeşim Oral; **References and Fundings:** Müberra Akdoğan, Hamidu Hamisi Gobeka; **Materials:** Müberra Akdoğan, Merve Şimşek.

REFERENCES

1. Wu AM, Wu CM, Young BK, Wu DJ, Chen A, Margo CE, et al. Evaluation of primary open-angle glaucoma clinical practice guidelines. *Can J Ophthalmol.* 2015;50(3):192-6. [[Crossref](#)] [[PubMed](#)]
2. Naumann GO, Schlötzer-Schrehardt U, Küchle M. Pseudoexfoliation syndrome for the comprehensive ophthalmologist. Intraocular and systemic manifestations. *Ophthalmology.* 1998;105(6):951-68. [[Crossref](#)] [[PubMed](#)]
3. Ritch R. Exfoliation syndrome. Ritch R, Shields MB, Krupin T. *The Glaucomas.* vol 2. 2nd ed. Missouri. The CV Mosby Co.; 1996. p.993-1013.
4. Spraul CW, Lang GE, Lang GK, Grossniklaus HE. Morphometric changes of the choriocapillaris and the choroidal vasculature in eyes with advanced glaucomatous changes. *Vision Res.* 2002;42(7):923-32. [[Crossref](#)] [[PubMed](#)]
5. Kubota T, Jonas JB, Naumann GO. Decreased choroidal thickness in eyes with secondary angle closure glaucoma. An aetiological factor for deep retinal changes in glaucoma? *Br J Ophthalmol.* 1993;77(7):430-2. [[Crossref](#)] [[PubMed](#)] [[PMC](#)]
6. Panda S, Jonas JB. Decreased photoreceptor count in human eyes with secondary angle-closure glaucoma. *Invest Ophthalmol Vis Sci.* 1992;33(8):2532-6. [[PubMed](#)]
7. Nork TM, Ver Hoeve JN, Poulsen GL, Nickells RW, Davis MD, Weber AJ, et al. Swelling and loss of photoreceptors in chronic human and experimental glaucomas. *Arch Ophthalmol.* 2000;118(2):235-45. [[Crossref](#)] [[PubMed](#)]
8. Bayhan HA, Bayhan SA, Can İ. Evaluation of the macular choroidal thickness using spectral optical coherence tomography in pseudoexfoliation glaucoma. *J Glaucoma.* 2016; 25(2):184-7. [[Crossref](#)] [[PubMed](#)]
9. Matlach J, Wagner M, Malzahn U, Göbel W. Repeatability of peripapillary retinal nerve fiber layer and inner retinal thickness among two spectral domain optical coherence tomography devices. *Invest Ophthalmol Vis Sci.* 2014;55(10):6536-46. [[Crossref](#)] [[PubMed](#)]
10. Batioğlu F. Optik koherens tomografi temel prensipler [Optical coherence tomography basic principles]. *Türkiye Klinikleri J Ophthalmol-Special Topics.* 2010;3(1):1-11. [[Link](#)]
11. Spaide RF, Koizumi H, Pozzoni MC. Enhanced depth imaging spectral-domain optical coherence tomography. *Am J Ophthalmol.* 2008;146(4):496-500. Erratum in: *Am J Ophthalmol.* 2009;148(2):325. [[Crossref](#)] [[PubMed](#)]
12. Hirooka K, Tenkumo K, Fujiwara A, Baba T, Sato S, Shiraga F. Evaluation of peripapillary choroidal thickness in patients with normal-tension glaucoma. *BMC Ophthalmol.* 2012;12:29. [[Crossref](#)] [[PubMed](#)] [[PMC](#)]
13. Konstas AG, Quaranta L, Katsanos A, Riva I, Tsai JC, Giannopoulos T, et al. Twenty-four hour efficacy with preservative free tafluprost compared with latanoprost in patients with primary open angle glaucoma or ocular hypertension. *Br J Ophthalmol.* 2013;97(12):1510-5. [[Crossref](#)] [[PubMed](#)]
14. Ritch R. Systemic associations of exfoliation syndrome. *Asia Pac J Ophthalmol (Phila).* 2016;5(1):45-50. [[Crossref](#)] [[PubMed](#)]
15. Topouzis F, Harris A, Wilson MR, Koskosas A, Founti P, Yu F, et al. Increased likelihood of glaucoma at the same screening intraocular pressure in subjects with pseudoexfoliation: the Thessaloniki Eye Study. *Am J Ophthalmol.* 2009;148(4):606-613.e1. [[Crossref](#)] [[PubMed](#)]
16. Leske MC, Heijl A, Hyman L, Bengtsson B, Dong L, Yang Z; EMGT Group. Predictors of long-term progression in the early manifest glaucoma trial. *Ophthalmology.* 2007;114(11):1965-72. [[Crossref](#)] [[PubMed](#)]
17. Grødum K, Heijl A, Bengtsson B. Risk of glaucoma in ocular hypertension with and without pseudoexfoliation. *Ophthalmology.* 2005; 112(3):386-90. [[Crossref](#)] [[PubMed](#)]
18. Moghimi S, Mazloumi M, Johari MK, Fard MA, Chen R, Weinreb R, et al. Comparison of macular choroidal thickness in patients with pseudoexfoliation syndrome to normal control subjects with enhanced depth SD-OCT imaging. *J Curr Ophthalmol.* 2017;29(4):258-63. [[Crossref](#)] [[PubMed](#)] [[PMC](#)]
19. Huang D, Swanson EA, Lin CP, Schuman JS, Stinson WG, Chang W, et al. Optical coherence tomography. *Science.* 1991;254(5035):1178-81. [[Crossref](#)] [[PubMed](#)] [[PMC](#)]
20. Ehrlich JR, Peterson J, Parlitsis G, Kay KY, Kiss S, Radcliffe NM. Peripapillary choroidal thickness in glaucoma measured with optical coherence tomography. *Exp Eye Res.* 2011;92(3):189-94. [[Crossref](#)] [[PubMed](#)]
21. Wu MA, Xu WX, Lyu Z, Shen LJ. Optical coherence tomography with or without enhanced depth imaging for peripapillary retinal nerve fiber layer and choroidal thickness. *Int J Ophthalmol.* 2017;10(10):1539-44. [[PubMed](#)] [[PMC](#)]
22. Mitchell P, Wang JJ, Hourihan F. The relationship between glaucoma and pseudoexfoliation: the Blue Mountains Eye Study. *Arch Ophthalmol.* 1999;117(10):1319-24. [[Crossref](#)] [[PubMed](#)]
23. Gorezis S, Christos G, Stefanidou M, Moustaklis K, Skyrlas A, Kitsos G. Comparative results of central corneal thickness measurements in primary open-angle glaucoma, pseudoexfoliation glaucoma, and ocular hypertension. *Ophthalmic Surg Lasers Imaging.* 2008;39(1):17-21. [[Crossref](#)] [[PubMed](#)]
24. Brooks AM, Gillies WE. The development of microvascular changes in the iris in pseudoexfoliation of the lens capsule. *Ophthalmology.* 1987;94(9):1090-7. [[Crossref](#)] [[PubMed](#)]
25. Parodi MB, Bondel E, Saviano S, Ravalico G. Iris indocyanine green angiography in pseudoexfoliation syndrome and capsular glaucoma. *Acta Ophthalmol Scand.* 2000;78(4):437-42. [[Crossref](#)] [[PubMed](#)]
26. Visontai Z, Mersich B, Holló G. Carotid artery elasticity and baroreflex sensitivity in patients with glaucoma. *J Glaucoma.* 2005;14(1):30-5. [[Crossref](#)] [[PubMed](#)]