

Determination of Frequency of Osteoma Cutis in Maxillofacial Region by Dental Volumetric Tomography

Maksillofasial Bölgede Osteoma Cutis Sıklığının Dental Volumetrik Tomografi ile Belirlenmesi

Adem PEKİNCE^a,
Kader AZLAĞ PEKİNCE^a,
Fatma ÇAĞLAYAN^b,
Muhammed Akif SÜMBÜLLÜ^b

^aDepartment of Oral Diagnosis and Radiology,
Karabük University Faculty of Dentistry,
Karabük, TURKEY

^bDepartment of Oral Diagnosis and Radiology,
Atatürk University Faculty of Dentistry,
Erzurum, TURKEY

Received: 07 Aug 2018

Received in revised form: 24 Dec 2018

Accepted: 25 Dec 2018

Available online: 27 Dec 2018

Correspondence:

Kader AZLAĞ PEKİNCE
Karabük University Faculty of Dentistry,
Department of Oral Diagnosis and Radiology, Karabük,
TURKEY/TÜRKİYE
azlagkader@gmail.com

ABSTRACT Objective: The purpose of this study was to evaluate the frequency of osteoma cutis and its location in the maxillofacial region by dental volumetric tomography (DVT). **Material and Methods:** In this study, DVT images of 332 patients (137 men and 195 women), admitted to our clinic and have taken dental tomography for various reasons; are reevaluated retrospectively for the presence of osteoma cutis. Chi-square test was used to assess the relationship between osteoma cutis presence and patients' age and gender. Patients with osteoma cutis were grouped according to location of the osteoma cutis. **Results:** Although numerically more common in women, there was no statistically significant differences between gender and the presence of osteoma cutis ($p>0.05$). The 21 patients of 23 patients with osteoma cutis were in the range 21-60 years. Osteoma cutis was present in the cheek in 12 patients of 23 patients with osteoma cutis in maxillofacial region. **Conclusion:** DVT is a useful diagnostic tool to show soft tissue calcification seen in the maxillofacial region including osteoma cutis. When osteoma cutis is seen in at the age of one, it may be accompanied by a syndrome. Dental radiologists must be more vigilant against those lesions that can be detected with dental volumetric tomography, and must inform the patient.

Keywords: Skin calcifications; osteoma cutis; dental volumetric tomography

ÖZET Amaç: Bu çalışmanın amacı, dental volumetrik tomografi (DVT) ile maksillofasial bölgede; osteoma kutis görülme sıklığının ve yerleşiminin değerlendirilmesidir. **Gereç ve Yöntemler:** Bu çalışmada, kliniğimize başvurmuş ve çeşitli nedenlerle tomografisi alınmış 332 hastanın (137 erkek ve 195 kadın) DVT görüntüleri kullanılmıştır. Bu görüntüler osteoma kutis varlığı açısından retrospektif olarak tekrar değerlendirildi. Osteoma kutis varlığı ile hastaların yaşı ve cinsiyeti arasındaki ilişkiyi değerlendirmek için ki-kare testi kullanıldı. Osteoma kutis saptanan hastaların görüntüleri osteoma kutis'in lokasyonuna göre gruplandırıldı. **Bulgular:** Kadınlarda sayısal olarak daha sık olmasına rağmen, cinsiyet ile osteoma kutis varlığı arasında istatistiksel olarak anlamlı fark bulunmadı ($p>0,05$). Osteoma kutis saptanan 23 hastanın 21'i 21-60 yaş aralığındaydı. Maksillofasial bölgede osteoma kutis saptanan 23 hastanın 12'sinde yanak bölgesinde osteoma kutis mevcuttu. **Sonuç:** DVT, osteoma kutis dahil olmak üzere maksillofasial bölgede görülen yumuşak doku kalsifikasyonunu göstermek için yararlı bir tanı aracıdır. Osteoma kutis sendromlarda görülebilen bir kalsifikasyon olması açısından dental radyologlar, dental volumetrik tomografi ile saptanabilen lezyonlara karşı daha uyanık olmalı ve hastayı bilgilendirmelidir.

Anahtar Kelimeler: Cilt kalsifikasyonları; osteoma kutis; dental volumetrik tomografi

Osteoma cutis (OC) is an uncommon non malignant disease that is featured by osseous nodules which are present in the reticular layer of the skin.^{1,2} Inner of the nodules are osteocytes and lamellar bone, while the outer part is osteoclasts.³ This osseous nodule's etiology is still undiscovered.⁴ Size, number and location are variable and generally asymptomatic. Osteoma cutis can be seen all over the body, but; most frequently on the legs, arms, face and scalp. The lesion is often covered with normal

skin, but sometimes erythema, atrophy, pigmentation or ulceration can be monitored. Osteoma cutis shows no tendency according to age and race. However, the frequency in women is more than men.^{2,5} Gender differences were connected to the estrogen, however, the relationship between osteoma cutis with estrogen has not been shown. Because men and postmenopausal women have also been shown to develop osteoma.⁶ Primary type that representing 15% of the cases arises absence predisposing factors or genetic disease.⁷ Secondary osteoma cutis occur for many reasons such as a pre-existing inflammation, neoplastic diseases or trauma.⁸ Osteoma cutis is usually presented as case reports in the literature. There are not enough articles in the literature about the incidence of osteoma box, so our study is important for literature that evaluates the frequency of osteoma cutis by dental volumetric tomography (DVT).

The target of this study is to assess the frequency of osteoma cutis and its location in the maxillofacial region with DVT.

MATERIAL AND METHODS

In the present study, DVT images of 332 consecutive patients (137 men, 195 women) admitted to our clinic and taken dental tomography for various reasons, were reevaluated retrospectively for the presence of osteoma cutis. The mean age was 32 ± 14.6 years (minimum 8 years and maximum 82 years).

Ethics committee approval of our study was obtained from the ethics committee of our university (Ethics committee approval number:42).

Newtom 3G (Quantitative Radiology, Verona, Italy) Flat Panel Based DVT machine was used to obtain images of patients included in the study. And, images of patients who underwent standard shooting procedures were used. Then the raw data is viewed through special study files.

STANDARD SHOOTING PROCEDURES

The patient was laid down horizontally in order to make the Frankfort plane vertical to the desk, thus ensuring a consistent orientation of the images. The X-ray tube detector apparatus carried out a 360° turning around the patient's head, with a canning

period of 36 s. It was used a maximum 110 KV output and 5 mAs, a 0.16-mm voxel size and a usual exposure time of 5.4 s to actuate the scanner. The pictures was analyzed by the QR-NNT software v.2.21 (Quantitative Radiology).

Following the raw data was obtained, the patient got out from the treatment room, and the clinician carried out the initial reconstruction to acquire 0.5 mm axial slices. OC presence was detected on axial slices throughout the scanning area. Patients who were screened for the presence of OC were evaluated according gender, age [Table 1](#), single or multiple lesions and its localization ([Table 2](#)).

STATISTICAL ANALYSES

Statistical analyses were carried out via SPSS® software (SPSS v. 20.0 for Windows; SPSS Inc., Chicago, IL). Chi-square test was used to detect the relationship between OC and age and gender. Patients with OC were grouped according to their location of the lesion.

RESULTS

The group of the patients we studied was consisted of 332 patients, of whom 195 (59%) were women and 137 (41%) were male. The mean age of the study group was 32 ± 14.6 (minimum 8 years; maximum 82 years). The frequency of OC according to gender and mean ages are presented on [Table 3](#).

Of 332 patients images of DVT, 23 (6.9%) patients had osteoma cutis. 14 (61%) of these patients were female and 9 (39%) were male. Osteoma cutis rate was 6.5% in males and 7.2% in females.

There wasn't any statistically meaningful distinction between genders by means of frequency of OC ($p > 0.05$). In terms of age and OC relation, there were statistically meaningful distinctions within the age groups. Namely, OC was more frequent in 21-60 years old adult patients ([Table 1](#), $p < 0.05$). The locations of OC were grouped as cheeks, chin, nose and lips as seen on ([Table 2](#)). OC was detected on the cheek of 12 patients [Figure 1a](#), [Figure 1b](#), [Figure 2a](#) and, chin of 3 patients [Figure 2b](#), nose of 2 patients [Figure 3](#) and lip of 1 patient ([Figure 4](#), [Figure 5](#)). In addition, there was multiple OC in 5 of the 23 patients.

TABLE 1: The frequency of osteoma cutis according to age.						
	Total Patients		Patients with Osteoma Cutis		X ²	P
	N	(%)	N	(%)		
0-20 age (year)	89	26.8	-	-	9.586	0.008*
21-60 age (year)	208	69.0	21	91.3		
>61 age (year)	12	4.2	2	8.7		

*: P<0.05

TABLE 2: The distribution of the location of osteoma cutis.						
	Cheek	Chin	Cheek and chin	Nose	Lip	Total
Single	12	3	-	2	1	18
Multiple	2	1	2	-	-	5
Total	14	4	2	2	1	23

TABLE 3: The demographic data of patients and frequency of osteoma cutis according to gender.						
	Total Patients		Patients with Osteoma Cutis		X ²	P
	N (%)	Age	N (%)	Age		
Male	137 (41)	33.8±14	9 (39)	37.4±10	0.046	0.829*
Female	195 (59)	30.9±14.8	14 (61)	42.4±12.9		
Total	332 (100)	32±14.6	23 (100)	40.5±11.9		

*: P>0.05

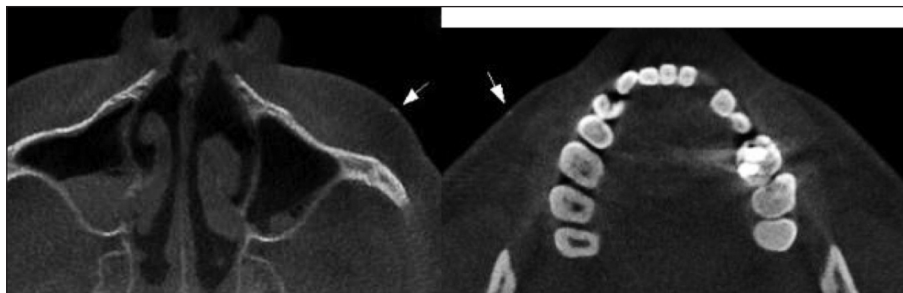


FIGURE 1: Osteoma cutis in cheek of 61 years old (left) and 33 years old (right) women patient.

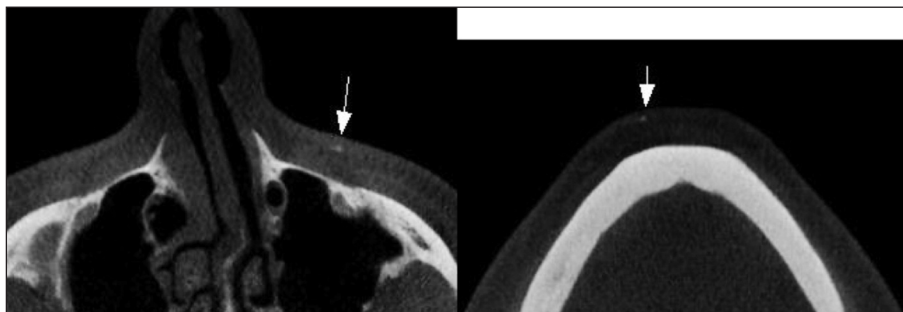


FIGURE 2: Multiple osteoma cutis in cheek (left) and chin (right) of 25 years old women patient.

DISCUSSION

Osteoma cutis is reported as a rare calcification in most studies as in our study, however, in a radiological study by Kim et al., osteoma cutis was reported to be 42.1%.⁹ In our study, no significant relationship was found with gender in accordance with the literature. However, it has been determined that the frequency increases as age progresses.

Osteoma cutis may exist as primary or secondary. Primary osteoma cutis appears in 15 percent of the cases, and it doesn't have relation with any history of local trauma or former cutaneous disease.¹⁰ Primary osteoma cutis may occur association with a syndrome or can be seen isolated. The primary osteoma cutis may be associated with genetic syndromes or not. Primary osteomas: Syndromes -Progressive osseous heteroplasia-Albright's hereditary osteodystrophy-Fibrodysplasia ossificans progressiva (Mc-Cune-Albright's syndrome) Gardner syndrome

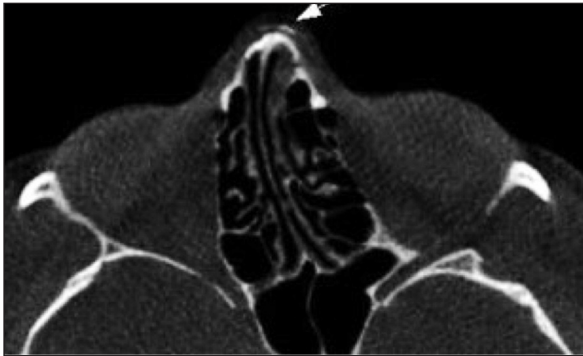

FIGURE 3: Osteoma cutis in nose of 26 years old woman patient.

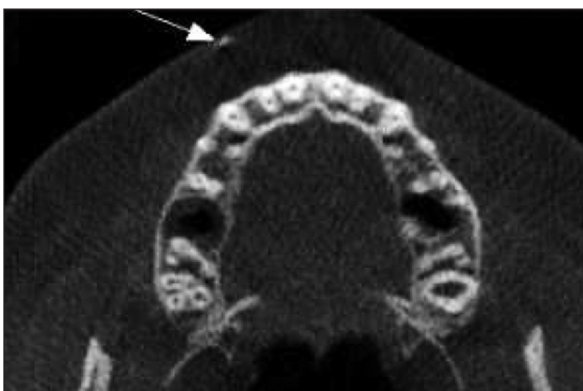


FIGURE 4: Osteoma cutis in upper lip of 58 years old woman patient.

Isolated, non-associated-Single small osteoma-Single large osteoma, plate-like osteoma-Multiple widespread osteomas- Multiple miliary osteomas on the face.⁴ Because of causing 85 percent of the cases, seconder osteoma cutis is the most prevalent version. It is defined as consequences of some diseases such as CREST syndrome, progressive systemic sclerosis/scleroderma, dermatomyositis (skin and muscle inflammation), morphea (rough skin), tumours, trauma, venous stasis and scars.^{5,10,11} There are some papers in literature describing that osteoma cutis occurs in female more than male. It mostly appears in females, between 20 and 30 ages.⁵ It's reason still not known why osteoma cutis appears frequently in females.¹² Gender differences were connected to the estrogen, but the relationship between osteoma cutis and estrogen has not been shown.⁶ In the present study, frequency of OC was numerically higher in female than male, however, the difference was not significant statistically. In addition, OC was more frequent in 21-60 years old adult patients than it is today. Mutations in the GNAS1 gene is the possible etiology of heterotopic ossification. The mutation of this gene is seen in patients who have Albright's inherited osteodystrophy or in patients who have serious progressive heterotopic ossification in skeletal muscle and deep connective tissue. But, when we look at former reports about primary osteoma cutis we don't see this relationship.¹³ Osteoma cutis lesions are benign and asymptomatic lesions, but they can cause aesthetic and psychological discomfort to the patient. Despite the non malignant evolution, the disease may bring out to remarkable cutaneous deformities at the affected parts. That causes aesthetic malformations and psychological problems in the patients. Therefore, treatment is conservative and is dependent on patient demand. The correct treatment is not detected yet. Clinical or surgical treatment may be applied or both of them. Clinical treatment may be applied to this patients and topical and systemic drugs can be used. Surgical alternatives which can be used for the treatment are procedures such as dermabrasion, curettage, laser or resection of the lesions. Moritz and Elewski mentioned about the use of retinoic acid to trigger deepithelialization, which helps the spontaneous extermination of the super-

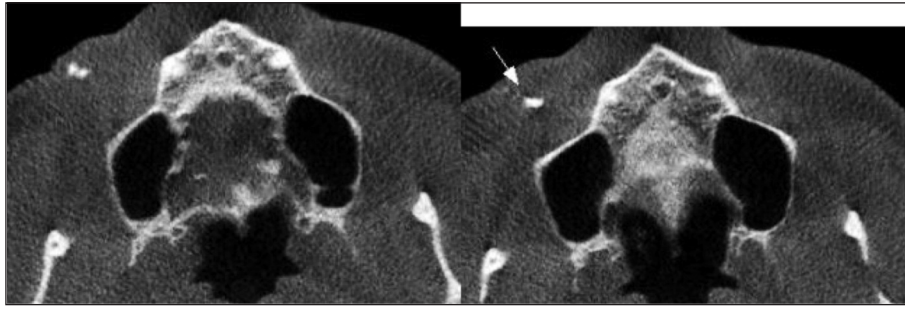


FIGURE 5: Two-axillary appearance of osteoma cutis causing swelling in the cheek area of a 38-year-old male patient.

ficial osseous pieces.³ OC may be detected incidentally on DVT scans. An incidental finding is not related to the existing illness and it is unintentionally found out.¹⁴ DVT can be used as an important diagnostic tool to evaluate soft-tissue calcifications and it is possible to measure in three dimensions without any superposition.¹⁵ Regardless of the low soft-tissue contrast of DVT images, it is considered successful for showing soft tissue calcifications such as carotid atherosclerosis, tonsilloliths and sialoliths. On a DVT scan, it is easier to identify tiny calcifications than panoramic or intraoral radiograph.¹⁵ Sometimes calcifications can be noticed at panoramic radiography, because of the closeness of soft-tissue structures to the focal trough. But, these monitorings are inherently planar and two-dimensional that makes localization and diagnosis difficult. Therefore, these lesions may be misdiagnosed as enostosis or any other lesions, when they are superposed on the jaws. This distinction can be made by placing the film between cheek and lip or a second radiological two-dimensional plane may be obtained. On the upshot, localization of osteoma cutis can be exactly made in cone-beam computed tomography images because of there is no such superposition.

The age range of overall patient group was 8-82 years. When OC is seen at the age of one, it may be accompanied by a syndrome probably. However, the number of pediatric patients was lower in the present study, because we do not prefer DVT scan for patients under 15 years unless mandatory. However, our overall patient group composed of relatively young adult individuals due to the many patient admitted to our clinic with complaints of wisdom tooth. We think that similar studies should be conducted on homogenize age groups in the fu-

ture. In the present study, we have grouped the location of OC as cheek, chin, nose and lip. The lesions were more frequent on cheek region as seen on (Table 2). We were unable to evaluate osteoma cutis on the forehead, because the field of view (FOV) area does not include the forehead. By looking at the suspected disease presentation and region of interest we can choose an optimal FOV for each patient.

CONCLUSION

DVT is a useful diagnostic tool to show soft tissue calcification seen in the maxillofacial region including osteoma cutis. Oral radiologists should be aware of incidental lesions as well as OC and should be awake about comprehensively evaluating possible underlying diseases.

There are not enough articles in the literature about the incidence of osteoma box, so our study is important for literature that evaluates the frequency of osteoma cutis by DVT.

Source of Finance

During this study, no financial or spiritual support was received neither from any pharmaceutical company that has a direct connection with the research subject, nor from a company that provides or produces medical instruments and materials which may negatively affect the evaluation process of this study.

Conflict of Interest

No conflicts of interest between the authors and / or family members of the scientific and medical committee members or members of the potential conflicts of interest, counseling, expertise, working conditions, share holding and similar situations in any firm.

Authorship Contributions

All authors contributed equally while this study preparing.

REFERENCES

- Mast AM, Hansen R. Multiple papules on the elbows. Congenital osteoma cutis. *Arch Dermatol.* 1997;133(6):777-80. [[Crossref](#)] [[PubMed](#)]
- Ma HJ, Jia CY, Yang Y, Song LJ, Hu R, Li TH. Primary multiple miliary osteoma cutis: an unusual chinese case. *Int J Dermatol.* 2014;53(1):73-5. [[Crossref](#)] [[PubMed](#)]
- Moritz DL, Elewski B. Pigmented postacne osteoma cutis in a patient treated with minocycline: report and review of the literature. *J Am Acad Dermatol.* 1991;24(5 Pt 2):851-3. [[Crossref](#)]
- Baginski DJ, Arpey CJ. Management of multiple miliary osteoma cutis. *Dermatol Surg.* 1999;25(3):233-5. [[Crossref](#)] [[PubMed](#)]
- Ayaviri NA, Nahas FX, Barbosa MV, Farah AB, de Arimatéia Mendes J, Ferreira LM. Isolated primary osteoma cutis of the head: case report. *Can J Plast Surg.* 2006;14(1):33-6. [[Crossref](#)] [[PubMed](#)] [[PMC](#)]
- Myllylä RM, Haapasaari KM, Palatsi R, Germain-Lee EL, Hägg PM, Ignatius J, et al. Multiple miliary osteoma cutis is a distinct disease entity: four case reports and review of the literature. *Br J Dermatol.* 2011;164(3):544-52. [[Crossref](#)] [[PubMed](#)]
- Kim BK, Ahn SK. Acquired perforating osteoma cutis. *Ann Dermatol.* 2015;27(4):452-3. [[Crossref](#)] [[PubMed](#)] [[PMC](#)]
- Duarte IG. Multiple injuries of osteoma skin in the face: therapeutical least invasive in patients with acne sequela-case report. *An Bras Dermatol.* 2010;85(5):695-8. [[Crossref](#)] [[PubMed](#)]
- Kim D, Franco GA, Shigehara H, Asaumi J, Hildenbrand P. Benign miliary osteoma cutis of the face: a common incidental CT finding. *AJNR Am J Neuroradiol.* 2017;38(4):789-94. [[Crossref](#)] [[PubMed](#)]
- Cottoni F, Dell' Orbo C, Quacci D, Tedde G. Primary osteoma cutis. Clinical, morphological, and ultrastructural study. *Am J Dermatopathol.* 1995;15(1):77-81. [[Crossref](#)]
- Bowman PH, Leshner JL Jr. Primary multiple miliary osteoma cutis and exogenous ochronosis. *Cutis.* 2001;68(2):103-6.
- Altman JF, Nehal KS, Busam KJ, Halpern AC. Treatment of primary miliary osteoma cutis with incision, curettage, and primary closure. *J Am Acad Dermatol.* 2001;44(1):96-9. [[Crossref](#)] [[PubMed](#)]
- Davis MD, Pittelkow MR, Lindor NM, Lundstrom CE, Fitzpatrick LA. Progressive extensive osteoma cutis associated with dysmorphic features: a new syndrome? Case report and review of the literature. *Br J Dermatol.* 2002;146(6):1075-80. [[Crossref](#)] [[PubMed](#)]
- Çağlayan F, Tozoğlu U. Incidental findings in the maxillofacial region detected by cone beam CT. *Diagn Interv Radiol.* 2012;18(2):159-63. [[Crossref](#)] [[PubMed](#)]
- Çağlayan F, Dağistan S, Keleş M. The osseous and dental changes of patients with chronic renal failure by CBCT. *Dentomaxillofac Radiol.* 2015;44(5):20140398. [[Crossref](#)] [[PubMed](#)] [[PMC](#)]