

Ectopic Salivary Tissue Mimicking Carotid Body Tumor in the Carotid Bifurcation: Case Report

KAROTİS BİFURKASYONDA KAROTİS CİSİM TÜMÖRÜNÜ TAKLİT EDEN EKTOPIK TÜKRÜK DOKUSU

Cengiz ÇOLAK, MD,^a Cevdet Uğur KOÇOĞULLARI, MD,^a Hasan KOCATÜRK, MD,^b Sare ALTAŞ, MD,^c Hikmet KOÇAK, MD^a

Departments of ^aCardiovascular Surgery, ^bCardiology Medical Center, ^cDepartment of Pathology, Atatürk University Medical Faculty, ERZURUM

Abstract

A 60-year-old woman presented with a mass on the left upper side of the neck, which had slowly grown in size over the previous 3 years. A painless, semi-mobile mass approximately with a size of 2-cm-diameter was palpated in the left jugulodigastric region. Preoperative computed tomography (CT) demonstrated a regular-border mass with contrast material retention and with a size of 2.8 x1.5 cm within left carotid artery bifurcation. The mass was excised completely and then histopathological examination revealed a normal salivary gland tissue with serous acini. To our knowledge, this is the first report of an ectopic salivary tissue within the carotid bifurcation in the world literature.

Key Words: Carotid body; carotid body tumor; adenoma, pleomorphic

Türkiye Klinikleri J Cardiovasc Sci 2007, 19:183-185

Özet

60 yaşında 3 yıldır boynun sol üst tarafında yavaş büyüyen kitle ile başvurdu. Ağrısız, az hareketli yaklaşık 2 cm büyüklüğünde bir kitle sol jugulodigastrik bölgede palpe edildi. Operasyon öncesi alınan bilgisayarlı tomografide sol karotis arter bifurkasyon bölgesi içinde 2.8x1.5 cm ebatlı, kontrast tutulumu gösteren düzgün sınırlı kitle gösterildi. Kitle tamamen çıkarıldı, histopatolojik incelemede seröz asinuslar ihtiva eden ektopik tükrük dokusu tespit edildi. Bizim bilgilerimize göre literatürde karotis bifurkasyonu içinde rapor edilen ektopik tükrük bezi ilgili ilk vakadır.

Anahtar Kelimeler: Karotid cisim; karotid cisim tümörü; pleomorfik adenom

Patients with carotid body tumours usually present with a gradually enlarging non-tender anterolateral neck mass. Differential diagnosis includes metastatic lymph nodes, carotid artery aneurysm, salivary gland tumour, branchial cleft cyst, and neurogenic or thyroid tumours. Ectopic salivary tissue, normally found in the following sites: oropharynx, parotid lymph nodes, tongues and tonsil, in the neck is rare.^{1,2} As far as

we know, this is the first report of an ectopic salivary tissue within the carotid bifurcation in the world literature.

Case Report

A 60-year-old woman presented with a mass on the left upper side of the neck, which had slowly grown in size over the previous 3 years. A painless, semi-mobile mass approximately with a size of 2-cm-diameter was palpated in the left jugulodigastric region. She had no other symptoms like neck pain, dysphagia, hoarseness, nasal obstruction, and epistaxis.

Ultrasonography of the neck demonstrated a hypovascular mass within the left carotid bifurcation, consistent with a carotid body tumor. No

Geliş Tarihi/Received: 01.11.2006 Kabul Tarihi/Accepted: 31.01.2007

Yazışma Adresi/Correspondence: Cengiz ÇOLAK, MD
Medical Center,
Department of Cardiovascular Surgery, ERZURUM
drmccolak@yahoo.com

Copyright © 2007 by Türkiye Klinikleri

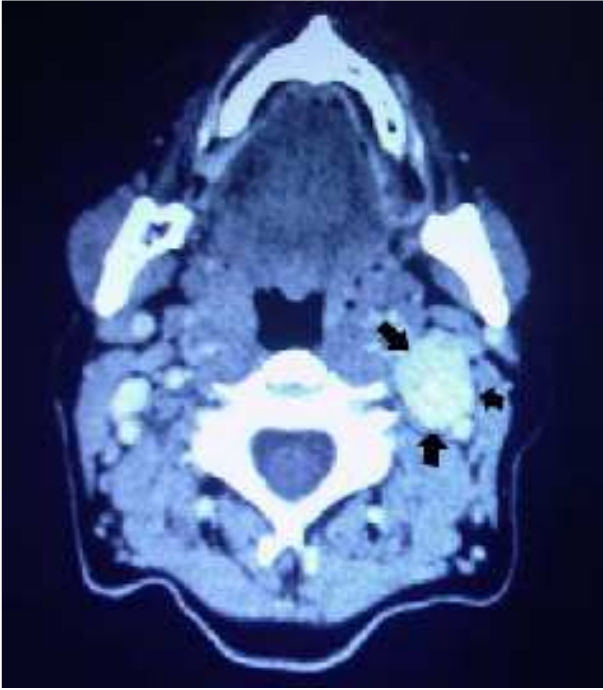


Figure 1. Preoperative computed tomography (CT) showing the mass with a size of 2.8 x 1.5 cm within left carotid artery bifurcation (black arrows).

other abnormality was detected either at palpation or at ultrasonography on the left side of the neck. Preoperative computed tomography (CT) demonstrated a regular-border mass with contrast material retention and with a size of 2.8 x 1.5 cm within left carotid artery bifurcation (Figure 1). Lateral angiographic view obtained with a selective left carotid artery injection demonstrated no tumor blush that is characteristic of the paraganglioma (Figure 2). Under general anesthesia, the mass was reached through a 5-6-cm under-skin excision fitting in with the upper half of anterior border of sternocleidomastoid muscle in the left neck region of the patient. The mass started from the bifurcation of carotid artery and it was upward between internal and external carotid arteries. The gross finding of the surgical specimen revealed a soft mass of 2.5 x 1.5 cm in size and white in color. Bleeding from the mass during surgery was very little because of weak vascular structure. Histopathological examination of the excised mass revealed a normal salivary gland tissue with serous acini (Figure 3). There were no complications after surgery and

there was no evidence of recurrence during the 2-year follow-up examination.

Discussion

In this paper, we present a case with an ectopic salivary tissue within the left carotid bifurcation. Ectopic salivary gland tissue occurs in many sites within the head and neck region and has even been found in other anatomical sites including anal mucosa. Head and neck site involvement includes the lateral and posterior neck, tongue, middle ear, thyroid, pituitary gland and mandible.^{3,4} Carotid body tumors are relatively rare tumors that originate from paraganglionic tissue in the neck and are

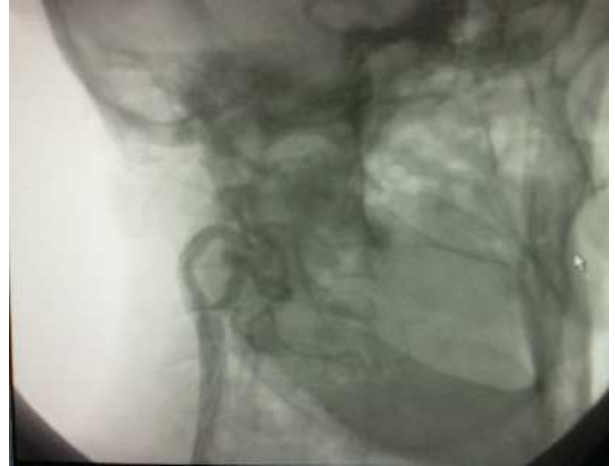

Figure 2. Lateral angiographic view obtained with a selective left carotid artery injection demonstrating normal left carotid angiogram.

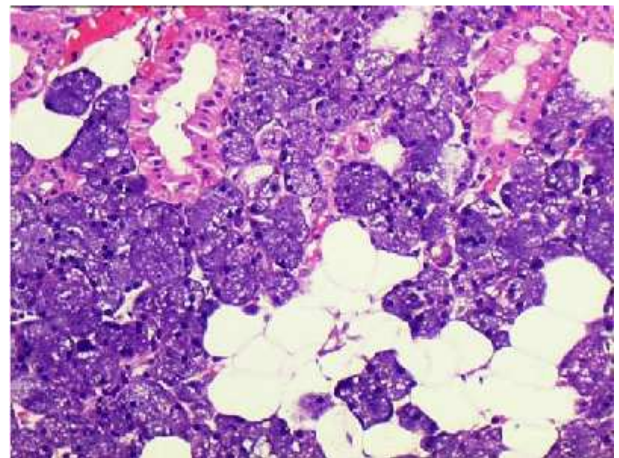


Figure 3. Excision material normal salivary gland tissue with serous acini (H&Ex100).

often referred to as chemodectomas. These tumors arise from specialized chemoreceptor sensory structures and, although highly vascular, grow slowly, usually with a history of several years.^{5,6} This tumour may be misdiagnosed if it is not suspected. When such a lesion is suspected, a non-invasive Doppler colour flow ultrasonography enables the clinician to arrive at a definite diagnosis. Subsequent arteriography is mandatory, because the finding of an intensely blushing hyper-vascular mass spreading into the carotid bifurcation further supports the diagnosis and provides accurate preoperative information concerning arterial blood supply.² The mass in our case was within the carotid bifurcation but had a weak vascular structure. CT, USG, traditional angiography imaging often provide a highly accurate diagnosis of carotid body tumors. Although these images reported the mass as carotid body tumor, it turned out to be salivary gland upon post-surgical histopathological evaluation.

In conclusion, ectopic salivary tissue does not exist in literature although there are various diag-

noses for the definitive diagnosis of carotid body tumors. As far as we gathered from our review of the world literature on the issue, this is the first report of an ectopic salivary tissue within the left carotid bifurcation in the literature. For this reason, we are of the strong opinion that this case will contribute a lot to literature.

REFERENCES

1. Muhm M, Polterauer P, Gstottner W, Temmel A, Losert H, Richling, B, et al. Glomus caroticum chemodectoma. Review on current diagnosis and therapy. *Wien Klin Wochenschr* 2000;112:115-20.
2. Hsu R, Hsu Y, Huang S. Hereditary ectopic salivary gland: Survey of three generations. *Acta Oto-Laryngologica* 2006;126:330-3.
3. Dorman M, Pierse D. Ectopic salivary gland tissue in the anterior mandible: A case report. *Br Dent J* 2002;193:571-2.
4. Guerrissi JO. Cervical by ectopic salivary gland. *J Craniofac Surg* 2000;11:394-7.
5. Derchi LE, Serafini G, Rabbia C, De Albertis P, Solbiati L, Candiani F, et al. Carotid body tumors: US evaluation. *Radiology* 1992;182:457-9.
6. Maher MM, O'Neill S, Corrigan TP, Murray JG. Bilateral neck masses. *Br J Radiol* 2000;73:223-4.