

Spontaneous Perforation of Liver Hydatid Cyst into the Thorax: Original Image

Karaciğer Kist Hidatiğinin Toraksa Spontan Perforasyonu

Ertan AYDIN,^a
Ali ÇELİK,^a
Ülkü YAZICI,^a
Nurettin KARAOĞLANOĞLU^a

^aClinic of Thoracic Surgery,
Atatürk Chest Disease and Chest Surgery
Training and Research Hospital,
Ankara

Geliş Tarihi/Received: 16.12.2011
Kabul Tarihi/Accepted: 28.02.2012

Bu çalışma TUSAD 32.Ulusal Kongresi
(20-24 Ekim 2010, Antalya)'nde poster (EP-140)
olarak sunulmuştur.

Yazışma Adresi/Correspondence:

Ali ÇELİK
Atatürk Chest Diseases and Chest Surgery
Training and Research Hospital,
Clinic of Thoracic Surgery, Ankara,
TÜRKİYE/TURKEY
alicelik78@gmail.com

Key Words: Echinococcosis, hepatic;
rupture, spontaneous; hydrothorax

Anahtar Kelimeler:

Ekinokokkozis, hepatic;
rüptür, kendiliğinden; hidrotoraks

Türkiye Klinikleri Arch Lung
2012;13(2):79-80

Copyright © 2012 by Türkiye Klinikleri

Spontaneous intrathoracic rupture of hydatid cyst is an uncommon but serious complication.¹ Presentation is usually related with thoracic finding and symptoms, such as pneumothorax, chest pain, dyspnea.

A sixty-year old patient was admitted to emergency clinic for chest pain and dyspnea. A chest X-ray revealed massive effusion on the right side (Figure 1a). A chest tube was inserted following thoracentesis and about 500 cc serohemorrhagic fluid was taken. There was no radiologically recovery on the chest X-ray after chest tube insertion. The patient's medical history included gastroenterology clinic follow up for multiple liver cyst hydatid since 15 years (Figure 1b). The patient was assumed as a perforation of liver hydatid cyst into the thorax and right thoracotomy was performed. In operation, a lot of daughter cysts located into the thorax through a diaphragmatic defect was found (Figure 1c). The diaphragm was incised for transdiaphragmatic evacuating of liver cysts (Figure 1d). After cleaning out of all cysts, the diaphragm itself

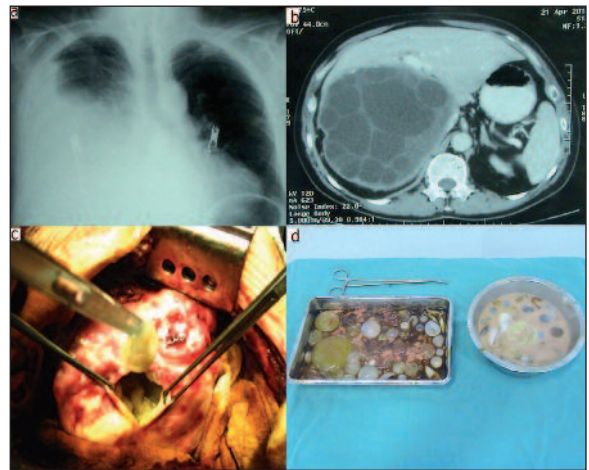


FIGURE 1: a) Chest X-Ray revealed massive effusion on right hemithorax, b) CT scan demonstrating multiple cysts in the right liver lobe, c) In operation field covered gas pack with bethadine, diaphragma incised and cysts cleaned out, d) excreted materials from the chest and liver.

was used for filling up the inner liver space and an 18F catheter was inserted into this area for follow up of bile drainage. On postoperative day of seven, because bile leakage had continued, an en-

doscopic sphincterectomy was performed. After 8 days from the last intervention, bilier drainage decreased and patient was discharged on postoperative 20th days.

REFERENCES

1. Dziri C, Haouet K, Fingerhut A, Zaouche A Management of cystic echinococcosis complications and dissemination: where is the evidence? *World J Surg* 2009;33(6):1266-73.