

Fat-Plug and Paper-Patch Myringoplasty in Rats

SİÇANLARDA YAPILAN YAĞ-TIKACI VE KAĞIT-YAMA MİRİNGOPLASTİSİ

Mehmet İMAMOĞLU*, Abdiilcemal Ümit IŞIK*, Özcan ACUNER*,
Gökhan HAROVA**, Osman BAHADIR*

* Dept. of Otorhinolaryngology, Medical School of Karadeniz Technical University,

** Dept. of Pathology, Medical School of Karadeniz Technical University, Trabzon, TURKEY

Summary

The purpose of this study was to investigate the recovery rate in paper-patch and fat-plug myringoplasty in rats. Small and large perforations have been inflicted on the tympanic membranes of 60 rats. Fat-plug and paper-patch myringoplasty was performed to different groups and another group was left for spontaneous healing.

It has been found that for small perforations, the recovery rate was 94.7 % in fat-plug myringoplasty 94.4 % in paper-patch myringoplasty and 66.6 % in control group. The recovery rate in large perforations was 52.9 56.2 % and 26.6%, respectively. On the other hand, in larger perforations paper-patch or fat-plug myringoplasty have not been found effective. In conclusion; due to the significant operational advantages, fat-plug or paper-patch myringoplasty can be suggested for the reconstruction of small and dry perforations of the tympanic membrane.

Key Words: Myringoplasty, Fat-plug, Paper-patch,
Rat

T Klin J Med Res 1998, 16:49-53

Myringoplasty is a reconstructive operation of the perforated tympanic membrane(1). Using full-thickness skin graft, it had first been performed by Berthold(2). Today, the most widely used graft material is otolog temporal muscle fascia which was first used in 1958 by Haermann and in 1959 by Ortegren(3,4). Routine myringoplasty operations are invasive procedures that require general anesthesia or intensive local anesthesia in operating room conditions. In addition, they also require a

Received: Feb. 03, 1997

Correspondence: Mehmet İMAMOĞLU
Dept. of Otorhinolaryngology,
Medical School of
Karadeniz Technical University
61080 Trabzon, TURKEY

T Klin .1 Med Res 1998, 16

Özet

Bu çalışmanın amacı, sıçanlardaki kağıt-yama ve yağ tıkaçı miringoplastisinin iyileşme oranlarını incelemektir. 60 adet sıçanın timpanik zarlarında küçük ve büyük perforasyonlar oluşturuldu. Değişik gruplarda yağ-tıkaçı ve kağıt-yama miringoplastisi uygulandı, diğer bir grup ise spontan iyileşme için bırakıldı.

Küçük perforasyonlar için iyileşme oranları; yağ-tıkaçı miringoplastisinde %94.7, kağıt-yama miringoplastisinde %94.4 ve kontrol grubunda %66.6 olarak bulundu. Büyük perforasyonlardaki iyileşme oranı ise sırasıyla %52.9, %56.2 ve %26.6 idi. Diğer taraftan, büyük perforasyonlarda kağıt-yama veya yağ-tıkaçı miringoplastisi etkili bulunmadı. Sonuç olarak; önemli cerrahi avantajları nedeniyle, timpan zarının küçük ve kuru perforasyonlarının tamirinde, yağ-tıkaçı veya kağıt-yama miringoplastisi tavsiye edilebilir.

Anahtar Kelimeler: Miringoplasti, Yağ-tıkaçı, Kağıt-yama,
Sıçan

TKlin Araştırma 1998, 16:49-53

more experienced surgeon, long hospitalization periods and have a relatively high risk of complications. Alternatively, fat-plug or paper-patch techniques may be preferred especially for myringoplasty of small, dry and central perforations, since those techniques may be performed on an ambulant basis and may have a relatively lower complication risk(5). Hence, it is* the purpose of this study to investigate the effects of fat-plug and paper-patch myringoplasty in rats.

Material and Method

This study has been conducted in the Surgical Research Laboratory of the Karadeniz Technical University, School of Medicine between March 1995-January 1996. Wistar rats of 250-400 grs. of body weight were used, as the structure of their

Table 1. Groups of the experiment

| Group No | Group Content | n |
|----------|---------------------------------|----------------|
| 1 | Fat plug/Small Perforation | 19 |
| 2 | Fat plug/ Large Perforation | 17 |
| 3 | Paper-patch/ Small perforation | 18 |
| 4 | Paper patch / Large Perforation | 16 |
| 5 | Control /Small Perforation | 1 [↔] |
| 6 | Control /Large Perforation | 15 |

tympanic membrane is anatomically and histologically similar to that of humans (6). A total of 60 rats were grouped in 6, yielding a sample size of 20 membranes per group. Membranes which were found to be abnormal in microscopic evaluation were excluded. The control group consisted of the rats which were left for spontaneous healing. The study groups were designed as in Table 1.

Rats were given intraperitoneal injections of 15-20 mgs. of Ketamin Hydrochloride depending on body weight. Following anesthesia, membranes were examined by using Zeiss Opmi-99 microscope under 16 magnification. The diameters of healthy membranes and the size of perforations to be inflicted were measured by the help of standard drill-tips. Using a sharp, straight pick, oval or round-shaped perforations were inflicted on the part of the membrane which can be clearly visible. If the size of the perforation exceeded 30 % of the membrane surface, this has been defined as a "large" perforation and a "small" perforation has been defined as one which was less than 30% of the membrane surface. For fat-plug myringoplasty, fat tissue was obtained from subcutaneous abdominal tissue of the rat. Plugs that were approximately three times larger than the perforation were prepared from the fat tissue. Under microscope, the plug was inserted through the perforation toward the middle ear by using the pick. Then, it has been slightly pulled back by alligator forceps so that the edges of the perforation turned laterally and the plug rested firmly on the perforation. For paper-patch myringoplasty, ordinary cigarette paper was used as a patch. A patch, approximately three times larger than the perforation was formed. It was soaked in 10 mg./ml. Rifamycin solution, then both sides of the patch were covered with a thin

layer of terramycin ophthalmic ointment. Using the alligator forceps under microscope, the patch was placed over the perforation completely covering it. A similar procedure was applied for inflicting the perforations for the control group which were then left for spontaneous healing. All groups were given intramuscular injections of 50 mg/kg/day scftriakson for 7 days. Thirty days after myringoplasty, otoscopic, pneumo-otoscopic and otomicroscopic examinations of all rats were performed under anesthesia. A "recovered" membrane was defined as the one whose perforation was completely closed, whose membrane color was normal whose membrane movement was present in pneumo-otoscopic examination. For further examination, rats with "recovered" membrane were sacrificed by a intraperitoneal injection of 50 mgs. Ketamin Hydrochloride, tympanic membranes, middle ear cavity and all temporal bones were removed from those and were kept in 10% formaldehyde for 3 days, then in a decalcification solution for 7 days. Following routine histopathological procedures, they were examined under light microscope. Statistical analysis of the findings was carried out by using an epidemiological software (Inlb 5.0). Qualitative data were analyzed by Chi-square tests. Yates' correction was applied for the cases which the number of observations in a 2x2 tabulation was less than 25. Fisher's exact test was used if the number of observations was below 5(7).

Results

In microscopic examination of the cases with fat-plug myringoplasty, the recovered membrane part was seen as an oval or round shaped region with visible borders and having a slightly darker color than the other parts. The unrecovered perforations were seen as covered with crusts and having purulent secretion around them. In microscopic examination of the cases with paper-patch myringoplasty, the recovered membrane part was seen as a clear region having a lighter color than the other parts. In addition, the recovered parts were seen as slightly retracted toward the middle ear. The unrecovered perforations had purulent secretion but even though a perforation was present, it was smaller in size due to new growth of the atrophic and retracted membrane. In microscopic examination of the cases in the control group, the recovered

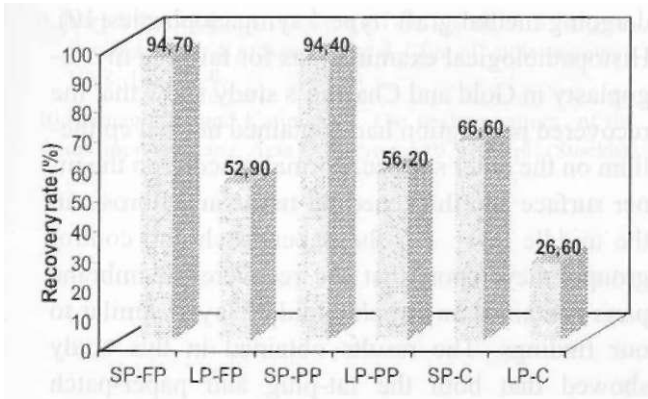


Fig.1. Recovery rate in percentage. (C: Control, FP: Fat plug, LP: Large perforation, PP: Paper patch, SP: Small perforation).

membranes were similar in appearance to those in the paper-patch group. Unrecovered perforations in the control group had no purulent secretion and their sizes were also reduced due to the new growth of the atrophic and retracted membrane.

The percentages of the recovered are given in Fig.1.

Statistical analysis of the results showed that for small perforations, recovery rate of the fat-plug and paper-patch groups are significantly different ($p=0.04$) from the recovery rate in the control group. On the other hand, no significant difference was found between the recovery rate of fat-plug and paper-patch myringoplasty for the small perforations ($p=0.74$). For the large perforations, no sig-

nificant difference was found between the recovery rate of the control group and fat-plug and paper-patch groups ($p=0.13$). However, both for the fat-plug and paper-patch groups, the recovery rate between small and large perforations was found to be significantly different ($p=0.01$). Histopathological examination of the membranes in the fat-plug group revealed that the middle layer of the tympanic membrane healed by the growth of fibrotic tissue, but those did not seem to be distributed regularly as would be in a normal membrane(8). Especially on the thickest part of the membrane the fibrils seemed to have a circular pattern (Fig.2). For the paper-patch group, histopathological examination revealed that the perforation was covered with squamous epithelium extending from the external ear canal and mucosa. The middle layer of the membrane was seen very thin or non-existent (Fig. 3). For the control group, findings of the histopathological examination were similar to the ones in the paper-patch group.

Discussion

Trauma, acute or chronic otitis media and applications of ventilation tube may cause permanent perforations of the tympanic membrane. Even though the most widely used technique in reconstruction is the temporal muscle fascia graft, alternative techniques have been developed especially for the smaller perforations such as fat-plug and paper-patch myringoplasty. It has been reported in Terry et al that a recovery rate of 79% has been

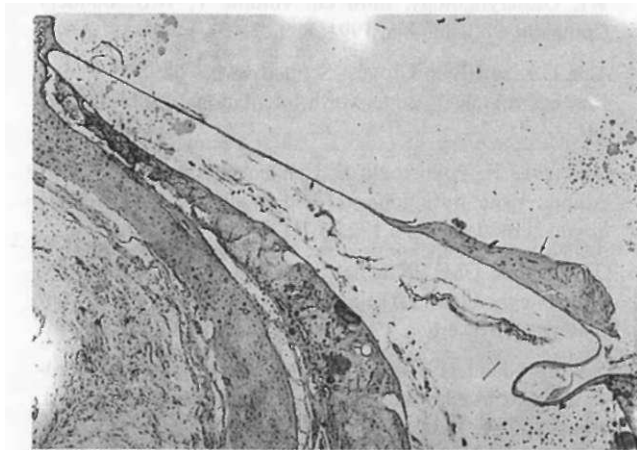


Fig. 2. Histopathological appearance; of recovered membrane (Arrow)with fat-plug myringoplasty

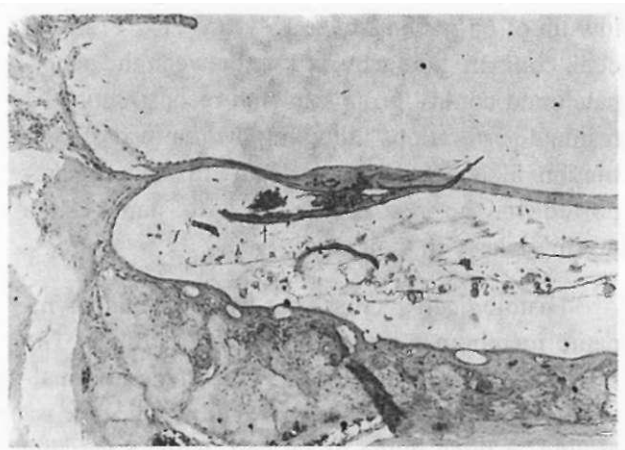


Fig. 3. Histopathological appearance of recovered membrane (Arrow) with paper-patch myringoplasty.

reached by fat-plug myringoplasty on 50 patients[^]). In a study on 62 infants with post-inflammatory perforations and residual perforations resulting from the removal of ventilation tube. Gross and Bassila report a 79.2 % recovery rate(1). They also used fat-plug myringoplasty and all of their cases were small perforations. Gold and Chaffoo compare fat-plug and paper-patch techniques in their study on guinea pigs.(2) The 88 % recovery rate in fat-plug myringoplasty in the Gold and Chaffoo's study is lower than that found in the present study. Gold and Chaffoo's reported recovery rate was 56 % for the paper-patch and 73 % for the control group. The authors explained the lower recovery rate in the paper-patch group by the higher inflammatory reaction of the guinea pigs to the foreign object. The significantly higher recovery rate for the paper-patch group in our study can be attributed to the application of prophylactic antibiotic and the treatment of the patch with antibiotic ointment prior to insertion. Reijnen and Kuijpers performed type 1 tympanoplasties in cats with a variety of connective tissues (including fat) as grafts, and found mesenchymal growth into the graft preceded epithelial and mucosal covering . The vascular connective tissues appeared to support proliferation of the overlying epithelium which bridges the gap.(10) Ringenberger reported a large series of successful type 1 tympanoplasties performed in human with ear lobule fat used as graft material. He compressed the fat in a fascia press, and used both medial and lateral technique to obtain an 86% closure rate with long-term follow-up of 65 patients over 15 years(11). Pribitkin et al, compare the recovery rate between the paper-patch and control groups for the reconstruction of residual perforations following the removal of ventilation tube(12). No significant difference is reported in the recovery rate with paper-patch myringoplasty in their study.

Histologically, cross-sections of healed tympanic membranes revealed several findings. The fat myringoplasty membranes consisted of normal-appearing outer epithelium and inner mucosa around a thick bulge of fat cell, with a variable amount of fibrous tissue. This appearance is similar to that described by Reijnen and Kuijpers in cat un-

dergoing medial graft type 1 tympanoplasties(10). Histopathological examinations for fat-plug myringoplasty in Gold and Chaffoo's study show that the recovered perforation had contained normal epithelium on the outer surface, normal mucosa on the inner surface and thickened fat tissue and fibrosis in the middle layer. For the paper-patch and control groups, they report that the recovered membrane parts contained an atrophic middle layer, similar to our findings. The results obtained in this study showed that both the fat-plug and paper-patch myringoplasty are as effective as any other myringoplasty technique in the reconstruction of dry, small and central perforations. It should also be noted that a significant advantage of either technique is that they can be performed bilaterally. On the other hand, in larger perforations, i.e. perforations that exceed 30 % of the membrane surface area, paper-patch or fat-plug myringoplasty have not been found effective. It can be argued that due to significant operational advantages, fat-plug or paper-patch myringoplasty can be suggested for the reconstruction of small and dry perforations of the tympanic membrane.

REFERENCES

1. Gross CW, Bassila M, Lazar RH, Long TE and Stanper S. Adipose plug myringoplasty: An alternative to formal myringoplasty techniques in children. *Otolaryngology-Head and Neck Surgery*, 1989; 101: 617-20.
2. Gold SR, Richard A and Chaffoo. Fat myringoplasty in the guinea pig. *Laryngoscope*, 1991; 101:1-5
3. Paparella MM, Shumrick DA, Gluckman JL and Meyerhoff WL *Otolaryngology*, third ed. volume 1, W.B.Sounders Company, Philadelphia, 1991; 8: 1271-81.
4. Alan G. IC and John Groves: *Scott-Brown's otolaryngology* fifty ed. volume I., Butterworth International Edition 1987: 14-5.
5. Özkarakaş F, Poyrazoğlu E, Candan Fİ, Uğur G, Erol H. Adipoz tıkaç miringoplasti. *Kulak burun boğaz ve baş boyun cerrahisi dergisi* 1995.3; 1; 14.
6. O'Denaghue GM. Epithelial migration of the Guinea Pig tympanic membrane: The influence of perforation and ventilating tube insertion. *Clin Otolaryngol* 1983.8;297-303.
7. Dawson-Sounders B, and Trapp RG. *Basic and Clinical biostatistics*, 2nd ed. Prentice-Hall international, Connecticut, 1994: 149-52.
8. Topaloğlu İ, Oğır Z, Arduç N, Önal B, Balkan V. Güney Ö. Adipoz doku ile miringoplasti: Deneyisel bir çalışma. *Kulak burun boğaz ihtisas dergisi* 1994.2(1);54-7.

9. Terry R M, Bellini MJ, Clayton Ml and Gandhi A G. Fat graft myringoplasty -a prospective trial. Clin, of otolaryngology 1988; 13:377-9
10. Reijnen CJH and Kuijpers W. The healing pattern of the drum membrane. Acta Otolaryngol 1971 (Suppl) (Stockh): 287.
11. Ringenberg J. Closure of Tympanic membrane perforations by use of fat. Laryngoscope 1978; 88:982-93.
12. Pribitkin EA, Handler SD, Tom LWC, Potsic WP and Wetmore RF. Ventilation Tube Removal, Indications for paper patch myringoplasty. Arc. of otolaryngology-head and neck surgery 1992; 118:495-7.