

Evaluation of urinary glycosaminoglycan excretion and renal pelvic mucosal glycosaminoglycan layer integrity in patients with recurrent stone disease and normal subjects

Kemal SARICA¹, Bora KÜPELİ², Çetin DİNÇEL¹, Canan AKBAY², Nursen SAYIN², Orhan GÖĞÜS¹

¹Depts. of Urology, ²Histology and Embryology, Medical School of Ankara University,

³Dept. of Urology, SSK Ankara Hospital, Ankara, TURKEY

To evaluate the Inhibitory effect of urinary macromolecules on crystal adhesion, aggregation, and growth, 24-hour urinary excretion of glycosaminoglycans (GAG's) together with the integrity of renal pelvic mucosal GAG layer were evaluated in 45 patients with recurrent Calcium-oxalate stone disease and 20 patients with ureteropelvic junction obstruction and no past history of stone disease. Urinary glycosaminoglycan excretion in patients with recurrent stone disease showed a statistically significant difference when compared to that of normal subjects (p<0.01). On the other hand, scanning electronmicroscopic (SEM) evaluation of the renal pelvic mucosal GAG layer revealed irregularity and disruption in some parts of the mucosa. Loss of mucosal GAG layer in some parts of the mucosa was also the leading finding of light microscopy. The integrity of this urothelial GAG layer was uniform and regular in all of the normal individuals evaluated. These findings suggest to a correlation between the level of macromolecules (GAG) in the urine and stone formation in patients with recurrent stone disease. The integrity of renal pelvic mucosal GAG layer may be important in the adhesion, aggregation and growth of calcium-oxalate crystals in stone forming patients. [Turk J Med Res 1995; 13(6): 176-180]

Keywords: Glycosaminoglycan, Urolithiasis

Urinary constituents that are able to reduce crystal nucleation and inhibit the growth and aggregation of formed crystals have been the focal point of many studies which deal with stone disease. Various ions, molecules and macromolecules have been studied in-vitro and are considered to be important in the development of urinary crystals (1-3). Although the composition of the urine seems to be involved in the formation of urinary crystals, the exact etiology is still unknown (4,5).

Experimental studies have suggested that the surface epithelium of the urinary tract should be resistant to the binding of a large number of substances (small and large ions, molecules, crystals, bacteria and cells) (6).

Both clinical and experimental studies during the last decade suggested a major role of urinary macromolecules in crystal oxalate formation and/or crystal growth (7,8). The glycosaminoglycan (GAG) layer that

normally covers urothelium seemed to prevent calcium crystals from adhering to the mucosal surface and acting as a nidus for stone formation (9-11). Thus, the level of excreted GAG in urine, and the integrity of GAG layer in the various parts of the urinary tract may be important in the adhesion, formation and growth of the urinary crystals (12,13).

In this prospective study, we have quantified the urinary GAG excretion in normal and stone forming patients; we have also compared the integrity of renal pelvic mucosa GAG layer in normal and stone bearing patients.

MATERIALS AND METHODS

Our study group consisted of 45 patients (32 males, 13 females) with recurrent stone disease and 20 patients (14 males, 6 females) with no past history of urinary stone disease. The ages of the patients with stone disease ranged from 24 to 46 years with an average value of 34.3 years. Average age value for the second group was 32.7 years (22-43 years).

All of the patients were on a regular diet, had normal renal functions and were not taking a diuretic. They did not have any active disease or urinary tract infection (UTI). A 24-hour overnight urine sample was

Received: Aug. 30, 1995

Accepted: Oct. 25, 1995

Correspondence: Kemal SARICA

Dept. of Urology, İbn-i Sina Hospital
Ankara, TURKEY

EVALUATION OF URINARY GLYCOSAMINOGLYCAN EXCRETION

obtained from each patient during the initial evaluation. Samples were kept in a refrigerator without any preservation until the assessment of GAG level in the urine. Urinary GAG level was measured according to the method proposed by Teler et al (14).

Evaluation of renal pelvic mucosal GAG layer integrity was performed on tissue specimens obtained in operations performed in patients with recurrent stone disease (pyelolithotomy) and in patients with ureteropelvic junction stenosis (Pyeloplasty). The tissues were immediately placed in a mixture of 2% paraformaldehyde and 2% glutaraldehyde buffered to pH 7.2 with 0.1 M phosphate and fixed at 4C for 2 hours. After rinsing in several changes of phosphate buffer, the specimens were placed in a veronal acetate buffered (pH 7.2) 2% solution of osmiumtetrahydroxide at 4 C for 2 hours. Dehydration was performed in a graded series of ethanol at 4 C, followed by embedding in araldite CY 212. Sections were cut on an LKB ultramicrotome, stained with both uranyl acetate and lead citrate. The urothelial biopsies were examined in an EM-10 Zeiss electron microscope.

Student's t test was used for statistical significance evaluation between two groups.

RESULTS

Of the 45 patients with recurrent stone disease, 19 patients had undergone three operations and 26 patients had undergone two operations. Patient characteristics and the number of previous operations are presented in Table 1. The 20 patients in the control (pyeloplasty) group had no stone operation prior to the pyeloplasty. The majority of these patients had moderate or minimal dilation of the renal pelves.

I. Urinary GAG excretion

Urinary GAG excretion (mg/ml) in patients with recurrent stone disease was 7.02±4.68 (SEM) as compared to 12.78±8.42 (SEM) in the pyeloplasty group (p<0.01). Details are provided in Table 2.

II. Light microscopy and Transmission electron microscopy findings

The integrity of the surface GAG layer was regularly observed in the urothelial biopsies of renal

Table 1. Patients characteristics and the number of previous operations in patients with recurrent stone disease.

	n	%
No.of total patients	65	100
Study group	45	69.2
Control group	20	30.8
Age range (years)	24-46	33.8
Previous stone operation		
Two times	26/45	57.7
Three times	19/45	42.3

Table 2. Evaluation of the urinary glycosaminoglycan excretion between two groups.

	Group 1	Group2	p
Urinary GAG excretion (mg/ml) (±SEM)	7.02±4.68	12.78±8.42	<0.01

*Group 1 Patients with recurrent stone disease
Group 2 Patients with no past history of stone disease (Ureteropelvic junction stenosis)

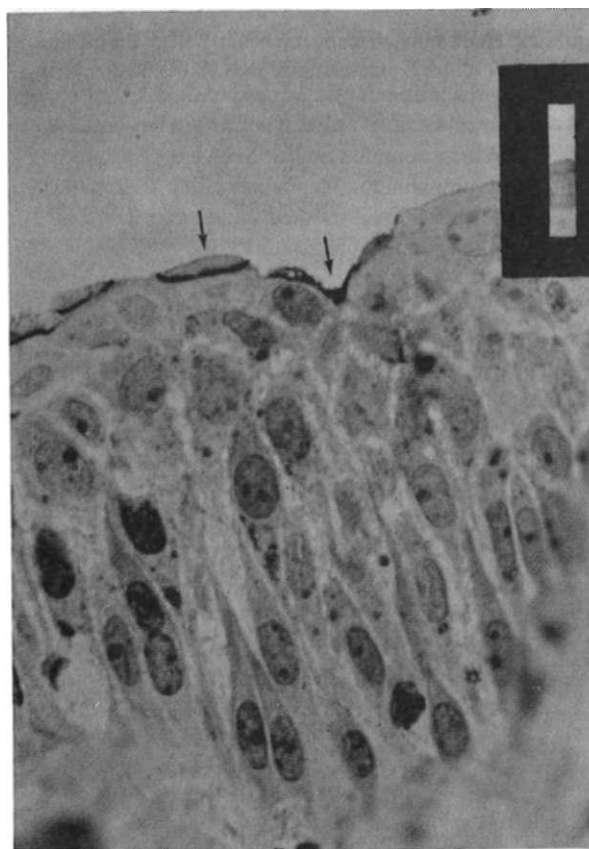


Figure 1. Light microscopy of renal pelvic urothelium of control patient. The surface GAG layer is normal and shows metachromasy with toluidine blue. See arrow (x 40)

pelvis from the control group. Because of sulfonated GAG's we observed metachromasy in some parts of the mucosal layer which was identified as pink lines on a blue surface (Figure 1). On the other hand, SEM evaluation of the controls revealed the structural integrity of cell organelles adjacent to the apical parts. The granular endoplasmic reticulum (GER) and mitochondria were seen regular and fine granular chromatic material was condensed against the inner aspect of the nuclear envelope (Figure 2).

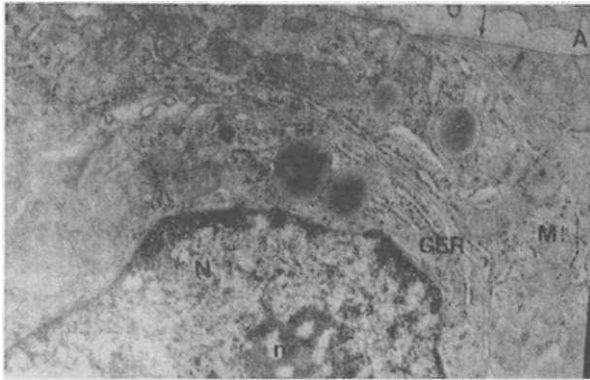


Figure 2. Electron microscopy of renal pelvic urothelium of control patient: Apical membrane of the cell (A), keeps its regularity (See arrow) nucleus (N) is rounded, nucleolus (n), mitochondria (M) and GER with small granules are being well observed, (x 12000)

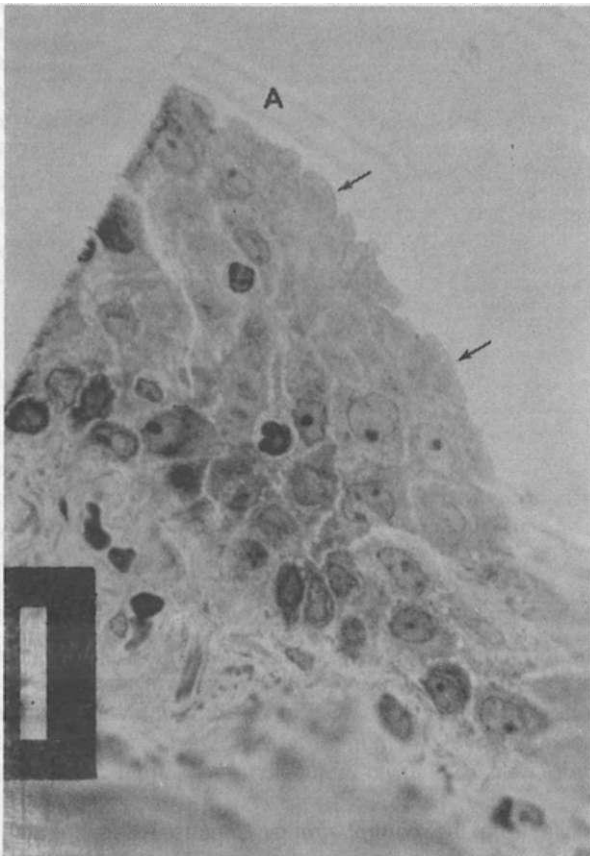


Figure 3. Light microscopic observation of the section of patients with recurrent stone disease: Apical mucine layer (A) seems to be irregular, (See arrow) the mucine layer is disrupted, lost in some parts of the mucosa and the intracellular spaces are widened.(x 40)

On the other hand, evaluation of the biopsies from patients with recurrent stone disease showed the

GAG layer to be irregularly organized and disrupted in some areas. Light microscopy also identified irregularity and loss of the GAG layer in some parts of the mucosa (Figure 3). SEM examination of the same specimens revealed very large vacuoles in the GER and enlarged mitochondria were enlarged. Nucleus were commonly indented (Figure 4). In the apical parts of the cells, the membrane lost its original regularity and there were cellular debris in the lumen.

DISCUSSION

It has been generally accepted that urinary stones result from the aggregation of individual crystals and/or growth into large particles in the urine after nucleation (13,15,16). Inhibitor (7,15,17) substances may play a role in crystal aggregation and/or crystal growth.

In many studies GAG's exhibited an inhibitory effect on the nucleation of urinary crystals (18-21). There is increasing agreement that one or more macromolecular constituents of urine possess major crystal growth inhibitor activity. This inhibitor activity has been particularly attributed to glycosaminoglycans. Although the mechanism of the action is uncertain, the inhibitory effect appears to be related to the binding of the inhibitor (GAG's) on the crystal surface where it inhibits induction of new crystal growth and aggregation (22-25).

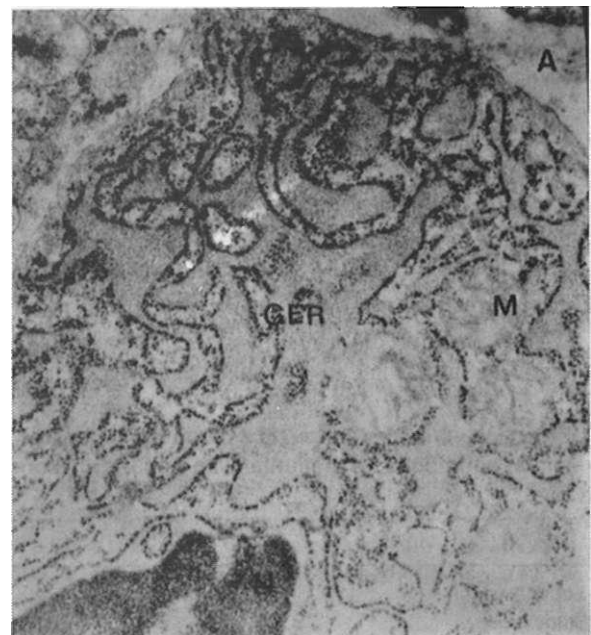


Figure 4. Electronmicroscopic observation of the section of patients with recurrent stone disease: GER seems apparently enlarged and vacuolated, the mitochondria are enlarged (M), nucleus is indented (N), cellular debris are recognized in the apical part of the membrane (A), (x 15000)

Urothelial GAG layers may also prevent calcium from adhering to surface cells and acting as a nidus for stone formation. Urothelial GAG's may also prevent the adherence of other molecules that could act as a matrix for calcium deposition. Inhibitor activity may be directly related to the affinity of the GAG for the crystal surface. GAG layers may alter crystal surface characteristics so that calcium oxalate crystals do not adhere to each other. This proposal has been supported by the observation that the anticrystal adherence property of normal urothelium can be damaged by a variety of GAG damaging agents (1,6,26,27).

Thus it seems logical that the urothelial surface may play a vital role in determining nucleation and whether calcium-oxalate crystals adhere to the urothelium and thus remain in the urinary tract where further fixed particle growth into a macroscopic stone could occur.

Despite all of these proposals, GAG's have not been thoroughly evaluated in terms of their prophylactic effect on stone formation. Although the inhibitory effect against Ca-oxalate crystallization has been demonstrated the urinary excretion of GAG did not seem to be a good marker because of the variability of results (12,22,28-30).

In our present study, determination of urinary GAG excretion levels in terms of mg/ml revealed a statistically significant difference between stone forming and normal patients ($p < 0.05$). Patients with recurrent stone disease seemed to have decreased urinary levels of GAG excretion. Our findings in this aspect supported the proposals on the inhibitory effect of macromolecules on stone formation. Evaluation of renal pelvic mucosal GAG layer integrity in our patients with recurrent stone disease revealed considerable structural defects as compared to the controls. In stone patients this layer was often lost indicating a gate for crystal adhesion and aggregation. Our observation further supports the idea that GAG layer of the urinary tract constitutes an important barrier to the adhesion and aggregation of calcium-oxalate crystals. Evaluation of the patients with ureteropelvic junction obstruction with no episodes of stone formation revealed no defect in the GAG layer. The integrity of this layer in all patients was well preserved.

In conclusion, our results demonstrate that there is a significant difference in urinary GAG excretion between patients with recurrent stones and normal patients. Evaluation of the integrity of renal pelvic mucosal GAG layer further supports the proposal that there may be defects in the GAG layer of stone patients. Further clinical and experimental studies with larger series of patients are needed to substantiate or refuse this hypothesis.

Turk J Med Res 1995; 13 (6)

İdrar glikozaminoglikan ekskresyonunun değerlendirilmesi ve reküran taş hastalığı olan bireylerle normal şahıslarda renal pelvik mukozal glikozaminoglikan katman bütünlüğü

İdrardaki makromoleküllerin kristal adhezyonu, agregasyonu ve büyümesi üzerine olan inhibitör etkisini değerlendirmek için, 24 saatlik idrar glikozaminoglikanların atılımı ile birlikte renal pelvik mukozal glikozaminoglikan katman bütünlüğünü, tekrarlayan kalsiyum oksalat taş hastalığı olan 45 hasta ve daha önceden tekrarlayan taş hastalığı olmayan uretero-pelvik obstrüksiyonu olan 20 hastada değerlendirildi. İdrar glikozaminoglikan atılımı tekrarlayan taş hastalığı olan hastalarda, normal bireylerle karşılaştırıldığında anlamlı fark gösteriyordu ($p < 0.01$). Diğer taraftan renal pelvik mukozal glikozaminoglikan katmanının elektronmikroskopik değerlendirilmesi mukozanın bazı bölümlerinde düzensizlikler ve kesilmeler gösteriyordu. Mukoza glikozaminoglikan katman kaybı aynı zamanda ışık mikroskopisinin önemli bir bulgusuydu. Bu üreteriyal glikozaminoglikan katman bütünlüğü değerlendirilen normal bireylerde koruyucu ve düzenliydi. Bu bulgular, tekrarlayan taş hastalığı olan bireylerde taş oluşumu ve idrarda makromoleküller düzeyiyle ilişkisi olduğuna işaret etmektedir. Renal pelvik mukozal glikozaminoglikan katman bütünlüğü, taş yapan hastalarda kalsiyum oksalat kristallerinin adhezyonu, agregasyonu ve büyümesinde önemli olabilir.

[Turk J Med Res 1995; 13(6): 176-180]

REFERENCES

1. Angel AH and Resnick M. Surface interaction between glycosaminoglycans and calcium oxalate. J Urol 1989; 141:1255.
2. Roberts SD. and Resnick, M.I. Glycosaminoglycans content of stone matrix. J Urol 1986; 135:1078.
3. Ryall RL, Darroch JN. and Marshall VR. The evaluation of risk factors in male stone-formers attending a 8 general hospital out-patients clinic. Br J Urol 1984;56: 116.
4. Baker R and Sison F. Demonstration of altered tissue mucopolysaccharides in renal calculus disease by selective staining techniques. J Urol 1954; 72(6): 1032.
5. Sorensen S, Hansen K, Bak S et al. An unidentified macro-molecular inhibitory constituent of calcium oxalate crystal growth in human urine. Urol. Res 1990; 18:373.
6. Parsons CL, Stauffer C, Schmidt J et al. Bladder surface glycosaminoglycans: An efficient mechanism of environmental adaptation. Science 1980; 208:605.
7. Gambaro G, Cicerello E, Marzao, G et al. A critical evaluation of the urinary inhibiting activity in idiopathic calcium oxalate nephrolithiasis. Urol. Int 1986; 41:418.

8. Grases F, Bauza CA, March JG et al. Glycosaminoglycans, uric acid and calcium oxalate urolithiasis. *Urol. Res* 1991; 19:375.
9. Gill W B, Ruggiero K, Straus II, KA. Crystallization studies in a urothelial-lined living test tube (The catheterized female rat bladder) *J Urol* 1979; 17:257.
10. Khan SR, Cockrell CA, Finlayson B et al. Crystal retention by injured urothelium of the rat urinary ladder. *J Urol* 1984; 132:153.
11. Nesse A, Garbossa G, Romero MC et al. Glycosaminoglycans in Urolithiasis *Nephron* 1992; 62:36.
12. Michelacci YM, Glashan RQ, Schor N. Urinary excretion of glycosaminoglycans in normal and stone forming subjects. *Kidney International* 1989; 36:1022.
13. NikWa MT. Urinary glycosaminoglycan excretion in normal and stone forming subjects: Significant disturbance in recurrent stone formers. *Urol Int* 1989; 44:157.
14. Teller WM, Burke EC, Rosevear JW et al. Determination of uronic acids in human urine. *J Lab Clin Med* 1962; 59:95.
15. Ebisuno S, Kohjimoto Y, Yoshida T, Ohkawa T. Effect of urinary macromolecules on aggregation of calcium oxalate in recurrent calcium stone formers and healthy. *Urol Res* 1993; 21:265.
16. Sidhu H, Hemal AK, Thind SK et al. Comparative study of 24-hour urinary excretion of glycosaminoglycans by renal stone formers and healthy adults. *Eur Urol* 1989; 16:45.
17. Akınca M, Esen T, Koçak T et al. Role of inhibitor deficiency in urolithiasis. *Eur Urol* 1991; 19:240.
18. Conte A, Roca P, Genestar C et al. Uric acid and its relationship with glycosaminoglycans in normal and stone-former subjects. *Nephron* 1989; 52:162.
19. EdyvaneKA, HibberdCM, Harnett RN. Macromolecules inhibit calcium oxalate crystal growth and aggregation in whole human urine. *Clin. Chim. Acta* 1987; 167:329.
20. Goldberg JM and Cotlier E. Specific isolation and analysis of mucopolysaccharides (glycosaminoglycans) from human urine. *Clin. Chim. Acta* 1972; 41: 19.
21. Grases F, Gill JJ and Conte A. Glycosaminoglycans: Inhibition of calcium oxalate crystalline growth and promotion of crystal aggregation. *Colloids and surfaces*. 1989; 36:29.
22. Grover PK, Ryal RL, Marshall, VL. Calcium oxalate crystallization in urine: Role of urate and glycosaminoglycans. *Kidney International* 1992; 41:149.
23. Jensen HB, Tiselius HG et al. Inhibition of calcium oxalate crystallization by urinary macromolecules. *Urol Res* 1991; 19:165.
24. Lama G, Carbone MG, Marrone N, Russo P, Sagnuolo G. Promoters and inhibitors of calcium urolithiasis in children. *Child Nephrol Urol* 1990; 10:81.
25. Kohri K, Garside J, Blacklock J. The effects of glycosaminoglycans of the crystallization of calcium oxalate. *Br J Urol* 1989; 63:584.
26. Gill WB, Jones KW, Riggiero JK. Protective effects of heparin and other sulfated glycosaminoglycans on crystal adhesion to injured urothelium. *J Urol* 1982; 127:152.
27. Martin X, Opgenorth TJ, Werness PG et al. Bladder secretion of inhibitors of calcium oxalate crystal growth. *Kidney International* 1985; 28:636.
28. Francois B, Cahen R, Pascal B. Inhibitor of urinary stone formation in 40 recurrent formers. *Br.J.Urol* 1986; 58:479.
29. Hesse A, Wuzel H, Vahlensieck W. Significance of Glycosaminoglycans for the formation of calcium oxalate stones. *Am. J. Kidney Res* 1991; 4:414.
30. Ryall RL, Harnett RM, Hibbert CM et al. Urinary risk factors In calcium oxalate stone disease: Comparison of men and women. *Br J Urol* 1987; 60:480.