

# Right Upper Abdomen Pain, Pruritus, Fever and Gall Bladder Hydrops in A Child with Kawasaki Disease: Case Report

## Çocukta Karın Ağrısı, Kaşıntı, Ateş ve Safra Kesesi Hidropsu ile Seyreden Kawasaki Hastalığı

Nalan YAZICI, MD,<sup>a</sup>  
Hatice LAKADAMYALI, MD,<sup>b</sup>  
Esra BASKIN, MD,<sup>c</sup>  
Mustafa ÇELİK, MD,<sup>a</sup>  
Kürşad TOKEL, MD,<sup>d</sup>  
Banu ÇELİK, MD,<sup>a</sup>  
Cevahir HABERAL, MD<sup>e</sup>

Departments of

<sup>a</sup>Pediatrics,

<sup>b</sup>Radiology,

<sup>c</sup>Cardiovascular Surgery

Başkent University

Alanya Medical and Research Center,  
Antalya

<sup>d</sup>Department of Pediatric Nephrology  
and Rheumatology

<sup>e</sup>Pediatric Cardiology,

Başkent University Ankara Hospital,  
Ankara

Geliş Tarihi/Received: 23.09.2008

Kabul Tarihi/Accepted: 16.01.2009

Yazışma Adresi/Correspondence:

Nalan YAZICI, MD

Başkent University

Alanya Medical and Research Center,

Department of Pediatrics, Antalya,

TÜRKİYE/TURKEY

nalanyazici@sbkeah.gov.tr

**ABSTRACT** What should be the suspected diagnosis of a physician in a three and a half year-old boy who was admitted to the emergency room with abdominal discomfort on the right upper quadrant of the abdomen with a palpable mass with the history of a fever lasting for more than a week, and additional pruritus for the last 3 days? Kawasaki disease is a clinical diagnosis with special criteria. Abdominal and gall bladder involvement is a relatively rare complication. In the subacute phase of the disease, ultrasonographic appearance of the gall bladder hydrops helped to establish the diagnosis in this case with careful medical history and subacute clinical findings in this puzzle like presentation.

**Key Words:** Kawasaki disease; gallbladder diseases

**ÖZET** Acil servise karında sağ üst kadranda ağrı ve dolgunluk, bir haftadan uzun süredir devam eden ateş ve son 3 gündür kaşıntı ile getirilen üç buçuk yaşındaki erkek hastada acil hekiminin olması ön tanısı ne olabilir? Kawasaki hastalığı özel tanısal kriterleri olan ve iyi klinik değerlendirme ile tanısı konabilen bir hastalıktır. Nadir bir tutulum şekli olarak safra kesesinde ultrasonografi ile saptanan hidropik safra kesesi subakut safhada gelmiş bu küçük çocukta Kawasaki hastalığının batın ve safra kesesi tutulumunu düşündürmüştü ve tanı koydurucu olmuştur. Kawasaki hastalığı çoklu sistem tutulumuna yol açabileceğinden dikkatli öykü ve fizik inceleme ile bu hastada subakut bulgular bulmaca parçaları gibi tanıyı desteklemiştir.

**Anahtar Kelimeler:** Kawasaki hastalığı; safra kesesi hastalıkları

**Türkiye Klinikleri J Pediatr 2010;19(2):148-51**

**K**awasaki disease or mucocutaneous lymph node syndrome is an acute febrile vasculitis of childhood in which 20% of untreated cases develop coronary artery abnormalities.<sup>1,2</sup> The etiology of the disease remains unknown. Acute hydrops of the gall bladder has been reported previously as a component of abdominal crises.<sup>3-7</sup> Herein, Kawasaki disease presenting with hydrops of the gall bladder was reported besides persistent fever and cholestatic hepatic dysfunction in a three and a half year-old boy.

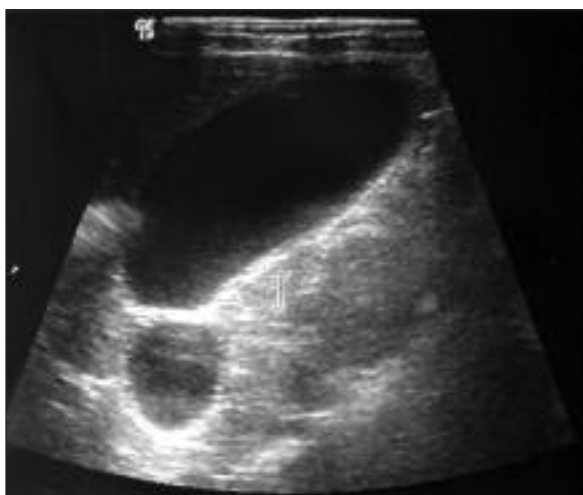
### CASE REPORT

A three and half-year-old boy presented with abdominal distention and discomfort to the emergency room. Fever was permanent for approximately 2 weeks. Pruritus became prominent in the last 3 days before his admission. In his medical history he was treated with suspicion of a streptococcal infec-

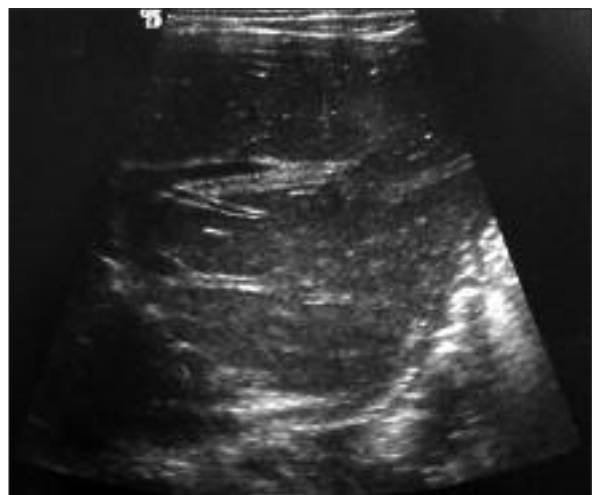
tion with oral sulbactam ampicillin for 10 days before admission to our clinic and fever persisted. When asked, the parents remembered that he had red eyes at the beginning of all his complaints. On initial physical examination, his temperature was 38.5°C, respiratory rate was 36 breaths/min, and pulse rate was 125 bpm and regular. Marked hepatomegaly and tenderness at the right subcostal region was detected. Both the orofarynx and the conjunctiva were all normal in the current admission with no lymphadenopathy. With further physical examination the next day in the sun light, very mild desquamations on the trunk, scrotum, palms and soles pointed out Kawasaki disease in the patient (Figure 1). In laboratory observations complete blood count revealed; Hb: 10.6 g/dL, MCV: 69.4 fl, erythrocytes  $4.53 \times 10^6/\text{mm}^3$ , WBC:  $11600/\text{mm}^3$ , platelets  $529 \times 10^3/\text{mm}^3$  with differential count of 56% polymorphonuclear leucocytes, 30% lymphocytes, and 4% monocytes. Erythrocyte sedimentation rate (ESR) and C-Reactive protein (CRP) were markedly elevated which were 120 mm/hr respectively; serum AST: 285 IU/L, ALT: 166 IU/L, ALP: 1420 IU/L, GGT: 652 IU/L, total bilirubin 1.74 mg/dL, conjugated bilirubin 1.12 mg/dL; serum amylase, lipase, PTT, INR and  $\text{NH}_3$  levels were detected in normal ranges. Cultures of blood, throat and urine were all negative ruling out a bacterial infection. Anti streptolysin O was also detected as

150 Todd Units within normal ranges for the patients age. Hepatic viral serology including antibodies to hepatitis A, B and C virus were all negative except anti-Hbs antibody which was higher than 1000 IU/l regarding the patient had been immunized against hepatitis B. Serological tests for EBV IgM and IgG antibodies and early antigen as well as CMV IgM and IgG were all negative. Abdominal USG showed hepatomegaly, dilatation of the biliary tract in the left lobe of the liver and hydrops of the gall bladder (Figure 2).

The echocardiography was normal at the time of diagnosis. Intravenous Immunoglobulin 2 g/kg was infused over 12 hours. Ursodeoxycholic acid was started. Aspirin treatment was delayed until the decrease of hepatic enzymes and then started at a dose of 5 mg/kg. During treatment, suprapubic pain occurred and lasted for two days. They urinalysis and urinary culture was unremarkable. Two consecutive echocardiographic investigations with an interval of fifteen days showed no coronary abnormalities. Hepatic enzymes returned to normal ranges in a week. Hepatomegaly and hydrops of the gall bladder disappeared in two weeks. Aspirin treatment was planned to be continued for 6 weeks. On the third week hydrops of the gall bladder recurred and remained unchanged with normal hepatic enzyme levels for a month. After the end of the second month from the treatment ALP, GGT

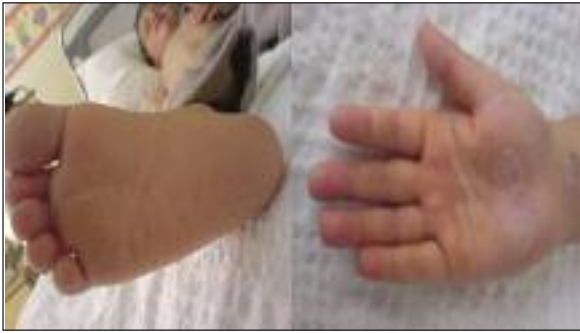

a



b

**FIGURE 1:** Ultrasonographic appearance of acute gall bladder hydrops in the same patient. (1a) Increase in longitudinal and horizontal diameters of the gall bladder with hydrops. (1b). Minimal dilatation of the bile ducts of the left liver lobe.



**FIGURE 2:** Desquamation of palms and soles in the patient with Kawasaki disease.

and ESR were all increased two fold. Pulse methyl prednisolon was started at a dose of 30 mg/kg for 3 days. After 3 days, hydrops was disappeared again. Prednisolon was started at a dose of 0.5 mg/kg/day besides ursodeoxycholic acid and aspirin treatment. Echocardiography was normal at the time of relapse. After a month of follow-up hydrops was again recurred. Prednisolon was stopped by the family out of order during this period and aspirin and ursodeoxycholic acid was continued. Prednisolon was added again to this combination and hydrops of the gall bladder was disappeared after 2 months of treatment. Then, all of his drugs were discontinued and the patient is disease free for 3 months. Informed consent for the report was obtained during the first hospitalization period.

## DISCUSSION

The real incidence of Kawasaki disease in Turkey and Middle East is unknown. It is reported about 3000 annual cases in United States and more than 170.000 cases since 1960s in Japan.<sup>1</sup> Hydrops of the gall bladder during Kawasaki disease were reported relatively rare from different countries and one of these cases was a 5 year old boy who was the only patient reported from our country in the past.<sup>3-8</sup>

The diagnosis of Kawasaki disease depends on classic clinical criteria.<sup>1,9</sup> Findings of at least 4 of the 5 principal criteria have to be present for the diagnosis of Kawasaki disease. These are conjunctival injection, mucosal lesions of oropharynx, changes of peripheral extremities, rash and cervical adenopathy greater than 1.5 cm with persistant fever lasting for more than 5 days and exclusion of

the other diseases causing these clinical features. According to the a general classification which was reported as 'EULAR/PRES endorsed consensus criteria for the classification of childhood vasculitides' by Ozen et al, two modifications were made (Table 1). The presence of perineal desquamation was added to the criterion describing changes in the extremities. Fewer than four of the remaining five principal criteria was agreed to be sufficient for the diagnosis of Kawasaki Disease in the presence of fever and coronary arterial involvement demonstrated by echocardiography (Table 1).<sup>9</sup> In our patient, the diagnosis is only suspected in the subacute phase upon the medical history which revealed the prolonged fever, pharyngeal and conjunctival injection and rash as well as the desquamation of the skin which was detected at the initial physical examination.

Although no specific laboratory test exists for Kawasaki disease, ultrasonographic finding of gall bladder hydrops helped us to suspect the diagnosis in this patient in the subacute phase. Besides, remarkable changes such as mild thrombocytosis, elevation of acute phase reactants and the liver enzymes which are the laboratory signs of a cholestatic liver disease made us to manage this patient as a possible case of Kawasaki disease.<sup>10</sup>

Other causes of gall bladder hydrops in childhood are systemic diseases such as Henoch-Schönlein purpura, sickle cell hemoglobinopathy, polyarteritis nodosa, nephrotic syndrome, leukemia, burn injury, acute pancreatitis and mediterranean fever. Bacterial infections like GABHS (scarlet fever, erysipelas), Group B streptococcus, *Leptospira*, *Pseudomonas*, *Salmonella typhi* and *paratyphi*, *Mycoplasma pneumoniae*; viruses like Epstein-Barr virus, hepatitis A, hepatitis B, *cytomegalovirus* and *human immunodeficiency virus* and other microorganisms like *Ascaris* and *Cryptosporidium* were reported to cause gall bladder hydrops.<sup>11</sup> Clinical and laboratory observations for the majority of infectious and other systemic causes were unremarkable in this patient so Kawasaki disease was suspected.

High dose aspirin and IVIG infusion is the standard care of acute Kawasaki disease as soon as possible and preferably within 10 days of disease

**TABLE 1:** Classification criteria for Kawasaki disease.

Fever persisting for at least five days (mandatory criterion) plus four of the following five features:
Changes in peripheral extremities or perineal area
Polymorphous exanthema
Bilateral conjunctival injection
Changes of lips and oral cavity: injection of oral and pharyngeal Mucosa
Cervical lymphadenopathy
In the presence of coronary artery involvement (detected on echocardiography) and fever, fewer than four of the remaining five criteria are sufficient (the exact number of criteria required is to be defined in the validation phase).

onset.<sup>1</sup> For the treatment of our patient, although in the subacute phase, IVIG infusion was started at a dose of 2 g/kg for 12 hours. High dose and early aspirin use was not possible in this patient because of elevation of liver enzymes. After the recovery of liver enzymes, maintenance dose of 5 mg/kg aspirin was applied and continued. After 3 weeks, when hydrops re-occurred and elevation of acute phase reactants detected, re-treatment with corticosteroids led to resolution of both the liver enzymes, CRP, ESR and findings of USG in the patient. In some cases, high dose methyl prednisolon was reported as a part of management and achieve a good response in some cases of refractory Kawasaki disease.<sup>1</sup> Refractory course in our patient should be due to both late admission of patient to our hospital and ineffective early treatment. Lack of aspirin treatment besides IVIG because of cholestatic liver

disease at the beginning of our follow-up may be an another cause for relapse.

Surgery was an occasional treatment of choice in severe abdominal disease in Kawasaki.<sup>6</sup> But management with serial ultrasonic evaluation and close clinical monitoring is also a safe method for treatment of this entity.<sup>6</sup> Corticosteroids although not a standard management, IVIG in the subacute phase and standard long term aspirin treatment was effective in our case especially in the case of abdominal disease.

Kawasaki disease is important because of severe cardiac complications. Exacerbations of the disease are not infrequent. Abdominal symptoms and cholestatic liver disease should be kept in mind as a relatively rare presenting sign for the emergency room staff and abdominal USG may be helpful for detection and follow-up after medical treatment.

## REFERENCES

- Rowley AH, Shulman ST. Kawasaki Disease. XV rheumatic diseases of childhood (connective tissue diseases, collagen vascular diseases.). In: Behrman RE, Kliegman RM, Jensen HB, Stanton BF, eds. Nelson Textbook of Pediatrics. 18<sup>th</sup> ed. Philadelphia: Saunders; 2007. p.1036-41.
- Serdaroğlu E. [Systemic vasculitis]. *Turkiye Klinikleri J Pediatr Sci* 2008;4(3):79-106.
- Jawad NH, Shaltout A, al-Momem J, Nahar A. Kawasaki disease: clustering in infants and pre-school children in Kuwait. *Ann Trop Paediatr* 1997;17(1):33-7.
- Malik AS. Kawasaki disease in Malaysia. *Ann Trop Paediatr* 1996;16(3):213-20.
- Gururaj AK, Arrifin WA, Quah BS. Hydrops of the gall bladder associated with Kawasaki syndrome. *J Singapore Paediatr Soc* 1989;31(1-2):93-6.
- Suddleson EA, Reid B, Woolley MM, Takahashi M. Hydrops of the gallbladder associated with Kawasaki syndrome. *J Pediatr Surg* 1987;22(10):956-9.
- Wirth S, Baumann W, Keller KM, Dittrich M, Müntefering H. [Kawasaki syndrome with acute gallbladder hydrops--case report and review of the literature]. *Klin Padiatr* 1985;197(1):68-70.
- Coşkun Y, Bayraktaroğlu Z, Gökalp A, Cil A, Ozkutlu S. Kawasaki disease associated with gallbladder hydrops. *Turk J Pediatr* 1995;37(3):269-73.
- Ozen S, Ruperto N, Dillon MJ, Bagga A, Baron K, Davin JC, et al. EULAR/PRReS endorsed consensus criteria for the classification of childhood vasculitides. *Ann Rheum Dis* 2006; 65(7):936-41.
- Newburger JW, Takahashi M, Gerber MA, Gewitz MH, Tani LY, Burns JC, et al.; Committee on Rheumatic Fever, Endocarditis, and Kawasaki Disease, Council on Cardiovascular Disease in the Young, American Heart Association. Diagnosis, treatment, and long-term management of Kawasaki disease: a statement for health professionals from the Committee on Rheumatic Fever, Endocarditis, and Kawasaki Disease, Council on Cardiovascular Disease in the Young, American Heart Association. *Pediatrics* 2004;114(6):1708-33.
- Abdullah A, Singer JI, Koontz S. Right upper quadrant mass. *Pediatr Emerg Care* 2007; 23(7):495-7.