

# Aggressive Extra-Ocular Sebaceous Carcinoma Originating from Lumbar Skin with Disseminated Lymphadenopathies: A PET-CT Evaluation: Case Report

## Lomber Deriden Köken Alan ve Yaygın Lenfadenopatilerle Seyreden Agresif Ekstra-Oküler Sebese Karsinoma: PET-BT Değerlendirmesi

Emel YAMAN, MD,<sup>a</sup>  
Uğur COŞKUN, MD,<sup>a</sup>  
Levent GÜNER, MD,<sup>b</sup>  
Özlem ERDEM, MD,<sup>c</sup>  
Banu ÖZTÜRK, MD,<sup>a</sup>  
Süleyman BÜYÜKBERBER, MD,<sup>a</sup>  
Mustafa BENEKLİ, MD,<sup>a</sup>  
Mehmet KİTAPCI, MD<sup>b</sup>

Departments of  
<sup>a</sup>Medical Oncology,  
<sup>b</sup>Nuclear Medicine,  
<sup>c</sup>Pathology,  
Gazi University Faculty of Medicine,  
Ankara

Geliş Tarihi/Received: 17.10.2008  
Kabul Tarihi/Accepted: 19.02.2009

Yazışma Adresi/Correspondence:  
Emel YAMAN, MD  
Gazi University Faculty of Medicine,  
Department of Medical Oncology, Ankara,  
TURKEY/TURKEY  
emelyaman@hotmail.com

**ABSTRACT** Sebaceous carcinoma (SC) is a malignant adnexal tumor, usually originating from eyelids. Extra-orbital sebaceous carcinoma is a rare carcinoma localized commonly in head and neck region. Although extra-orbital SC has an indolent course, it may have highly invasive properties and may cause distant metastases rapidly. We report a 46 year-old-woman with extra-orbital SC originating from lumbar skin. Just after two months from the excision of primary lesion, patient readmitted with axillary lymphadenopathies. positron emission tomography (PET-CT) was used for evaluation of both extent of disease and treatment response. Partial remission was observed with docetaxel treatment. This case illustrates how extra-ocular SC can behave aggressively despite the traditional belief. PET-CT can help to evaluate the extent of disease and response to therapy.

**Key Words:** Sebaceous gland neoplasms; lumbosacral region; positron-emission tomography

**ÖZET** Sebese karsinom, genellikle göz kapaklarından köken alan malign deri eki tümürüdür. Ekstra-oküler sebese karsinomlar nadir olup, sıklıkla baş-boyun bölgesinde gözlenirler. Her ne kadar yavaş seyirli olarak bildirilseler de bazı vakalarda yüksek bir invaziv potansiyel gözlenir ve uzak metastaz saptanabilir. Bu vakada lomber deriden köken alan ekstra-oküler sebese karsinomlu 46 yaşında bir kadın hasta takdim edildi. İlk lezyonun cerrahi olarak çıkarımından sadece iki ay sonra hastada aksiller lenfadenopatiler saptandı. Pozitron emisyon tomografi (PET-BT) hem hastalık yaygınlığını hem de tedavi yanıtını değerlendirmek amacıyla kullanıldı. İkinci basamak tedavide kullanılan dositaksel rejimi ile parsiyel yanıt gözlemlendi. Bu vaka, ekstra-oküler sebese karsinomun zaman zaman nasıl bir agresif seyir izleyebileceğini göstermektedir. PET-BT hastalık yaygınlığını ve tedavi yanıtını değerlendirmede etkin bir yöntem olabilir.

**Anahtar Kelimeler:** Sebese karsinoma; lomber bölge; pozitron emisyon tomografi

**Türkiye Klinikleri J Med Sci 2010;30(4):1395-8**

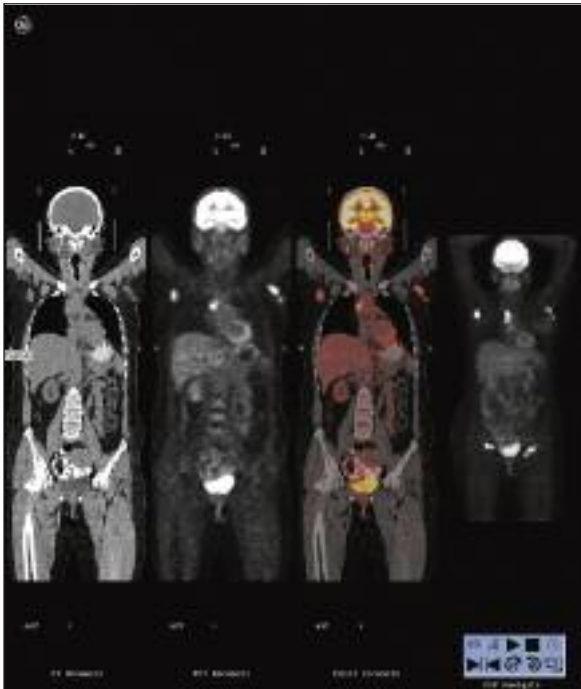
Sebaceous carcinoma (SC) is a malignant adnexal tumor with variable sites of origin, histological patterns and clinical presentations. Eyelid SC is the most common type of SC and comprises 1-5.5% of all eyelid tumors.<sup>1</sup> Extra-orbital SC accounts only 25% of all cases, arising mostly from the head and neck region.<sup>2</sup> It typically presents as a slow growing mass and is believed to be an indolent tumor with better prognosis compared to its ocular counterpart<sup>1</sup>, although there are some reports claiming the contrary.<sup>3</sup> To our knowledge, this is the first report of SC originating from lumbar region. Moreover, this case is associated with generalized involvement of lymph nodes which is exceedingly rare.

There are not only limited data available on the use of positron emission tomography with computerized tomography (PET-CT) in non-melanoma cutaneous cancers;<sup>4-6</sup> but there is also only one case report utilizing PET-CT in the follow-up of ocular SC.<sup>7</sup> We present a patient with very aggressive SC developing rapidly disseminated lymphadenopathies shortly after the excision of the primary lesion on the back. The diagnosis of the disseminated disease and response to treatment was evaluated with PET-CT.

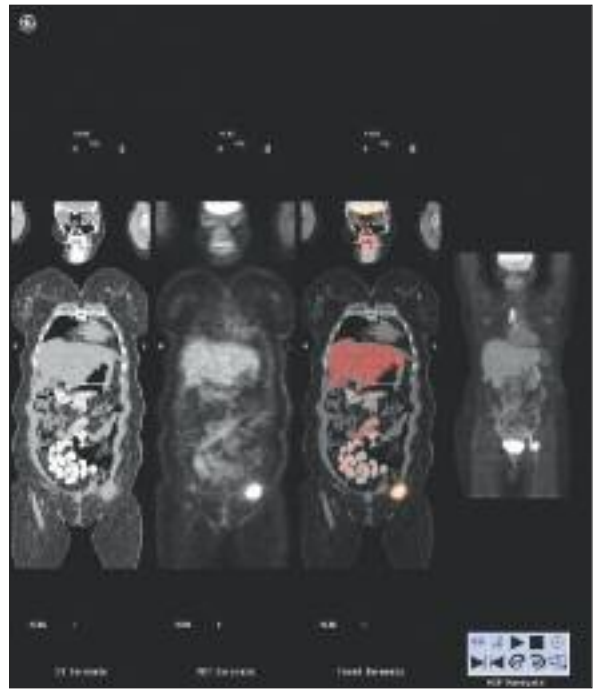## CASE REPORT

A 46-year-old woman was admitted to our hospital with a rapidly growing nodular mass on her lower back. The lesion was present for about ten years; however, it grew up from 1 cm to 6 cm in the last three months. On physical examination, the lesion was fixed, non-tender and yellowish in color. Wide surgical excision of the lesion was performed. Diagnosis of SC was made. Although tumor was well differentiated, it had a high mitotic activity. By immunohistochemistry, tumor cells were positively stained with EMA and LMWK; however, Melan A, S 100, CEA, CD 15 and mucin were negative.

One month later, she noticed a new mass on her left axillary region. Physical examination revealed multiple fixed lymphadenopathies in her left axillary and inguinal regions; the biggest one was 4x3 cm in diameter. The tru-cut biopsy of the inguinal lymph node revealed SC infiltration. To exclude the Muir-Torre syndrome, abdominopelvic and thorax CT were done which revealed no visceral pathologies. The extent of disease was evaluated with PET-CT. After overnight fasting, 0.15 m Ci/kg intravenous 18-FDG glucose was injected. Two hours and sixteen minutes after the injection, pathological increased uptake of 18-FDG glucose uptake was observed in paratracheal, mediastinal, subcarinal lymph nodes and bilateral inguinal lymph nodes (Figure 1). Initial SUV maximum of lesions were 13. There was no pathological uptake in the pulmonary nodule. Chemotherapy regimen with cisplatin 75 mg/m<sup>2</sup> on day 1, and tegafur 300 mg/m<sup>2</sup> on days 1-14 for every 21 day cycle was started. After two cycles of the chemotherapy, progressive disease was noted and docetaxel 100 mg/m<sup>2</sup> on day 1, for every 21 day cycle was administered. Response to treatment was evaluated with PET-CT and partial remission was observed (Figure 2). PET-



**FIGURE 1:** PET-CT images showing bilateral inguinal lymph nodes, mediastinal and axillary lymph nodes with 18F-FDG uptake, respectively.



**FIGURE 2:** PET CT images showing increased 18F-FDG activity in the left inguinal region.

CT revealed that pathological uptake of 18-FDG glucose was completely disappeared in bilateral axillary lymph nodes and right inguinal lymph nodes; while other pathological 18-FDG glucose uptakes remained. Written consent of the patient was obtained.

## DISCUSSION

Extra-orbital SC occurs most frequently in older women in their 6<sup>th</sup> and 7<sup>th</sup> decades of life. These tumors usually localize in the head and neck region where most of the sebaceous glands are found.<sup>2</sup> Less common locations include submandibular gland, buccal mucosa, laryngeal and pharyngeal cavities, extremities, sole, the dorsum of great toe and external genitalia.<sup>3,8,9</sup> To our knowledge, this is the first report of extra-ocular SC originating from lumbar region. Moreover, disseminated lymphatic metastases beyond regional lymph nodes have never been reported. Despite the general belief of indolent behavior,<sup>3,10,11</sup> our patient developed disseminated disease within two months.

The association with the Muir-Torre syndrome should be also considered, because 30% of patients with this syndrome may have synchronous sebaceous carcinoma.<sup>12,13</sup> In our patient, there was no family history of hereditary cancers or sebaceous carcinomas. Gynecological exam revealed no abnormalities. Fecal occult blood tests were performed three times; all were negative. There was no evidence of visceral malignancy detected by CT. Therefore, Muir-Torre Syndrome was thought to be very unlikely.

Diagnosis of sebaceous carcinomas may be difficult and histopathologically, orbital SC must be differentiated from other cutaneous malignant neoplasms and cutaneous metastases of clear cell carcinomas like renal cell, breast, bladder and prostate cancer, and immunohistochemical analysis may be useful in differentiation.<sup>14</sup> Primary cutaneous neoplasms including clear cell squamous carcinoma, apocrine hidradenocarcinoma, clear cell syringoid carcinoma and clear cell porocarcinoma may be confused with SC.

Today, wide surgical excision of tumor with involved regional lymph node removal is the accepted treatment for extra-ocular SC. There was a small lesion on our patient's lower back for ten years, indicating that it was low grade. However, it had grown faster during previous three months and in our opinion; a transformation to higher grade occurred. In our case, relapse occurred only two months later, not only at regional lymph nodes but also at distant sites like mediastinal and axillary lymph nodes, although in literature draining lymph nodes were involved in only a few cases.

There is no standard chemotherapy regimen for metastatic SC except for isolated case reports using cisplatin-based combinations with variable responses. We used cisplatin and an oral 5-FU derivative, tegafur because of the histological origin of the tumor. After two courses of treatment, progression was observed and chemotherapy regimen was changed to docetaxel as a single agent.<sup>11</sup> There was partial response to this treatment, which was also confirmed with PET-CT. Up to now, there was one more case report utilizing PET-CT in the follow-up of SC.<sup>7</sup>

## CONCLUSION

Our case illustrates that extra-ocular SC may show a very aggressive biological manner with rapid spread. The patients with SC must be in a close follow-up and any signs of lymphatic or hematogenous spread must be treated aggressively. Because of this rarity, there is no standard treatment schedule other than surgical excision with involved regional lymph node dissection, where possible. Additionally, in sight of this case report, we may conclude that the ability of FDG-PET to find systemic metastatic sites which could not be detected with conventional imaging is valuable in patients with extra-ocular sebaceous carcinoma, and may result in important changes in staging and management. More studies are needed to delineate to optimum treatment strategy and imaging techniques.

## REFERENCES

1. Pricolo VE, Rodil JV, Vezeridis MP. Extraorbital sebaceous carcinoma. *Arch Surg* 1985;120(7):853-5.
2. Wick MR, Goellner JR, Wolfe JT 3rd, Su WP. Adnexal carcinomas of the skin. II. Extraocular sebaceous carcinomas. *Cancer* 1985; 56(5):1163-72.
3. Nelson BR, Hamlet KR, Gillard M, Railan D, Johnson TM. Sebaceous carcinoma. *J Am Acad Dermatol* 1995;33(1):1-15.
4. Belhocine T, Pierard GE, Frühling J, Letesson G, Bolle S, Hustinx R, et al. Clinical added-value of 18FDG PET in neuroendocrine-merkel cell carcinoma. *Oncol Rep* 2006;16(2):347-52.
5. Cho SB, Chung WG, Yun M, Lee JD, Lee MG, Chung KY. Fluorodeoxyglucose positron emission tomography in cutaneous squamous cell carcinoma: retrospective analysis of 12 patients. *Dermatol Surg* 2005;31(4):442-6.
6. Tsai EY, Taur A, Espinosa L, Quon A, Johnson D, Dick S, et al. Staging accuracy in mycosis fungoides and sezary syndrome using integrated positron emission tomography and computed tomography. *Arch Dermatol* 2006;142(5):577-84.
7. Krishna SM, Finger PT, Chin K, Lacob CE. 18-FDG PET/CT staging of ocular sebaceous cell carcinoma. *Graefes Arch Clin Exp Ophthalmol* 2007;245(5):759-60.
8. Oppenheim AR. Sebaceous carcinoma of the penis. *Arch Dermatol* 1981;117(5):306-7.
9. Escalonilla P, Grilli R, Cañamero M, Soriano ML, Fariña MC, Manzarbeitia F, et al. Sebaceous carcinoma of the vulva. *Am J Dermatopathol* 1999;21(5):468-72.
10. Moreno C, Jacyk WK, Judd MJ, Requena L. Highly aggressive extraocular sebaceous carcinoma. *Am J Dermatopathol* 2001;23(5):450-5.
11. Duman DG, Ceyhan BB, Celikel T, Ahiskali R, Duman D. Harrington Extraorbital sebaceous carcinoma with rapidly developing visceral metastases. *Dermatol Surg* 2003;29(9):987-9.
12. Harrington CR, Egbert BM, Swetter SM. Extraocular sebaceous carcinoma in a patient with Muir-Torre syndrome. *Dermatol Surg* 2004;30(5):817-9.
13. Paraf F, Sasseville D, Watters AK, Narod S, Ginsburg O, Shibata H, et al. Clinicopathological relevance of the association between gastrointestinal and sebaceous neoplasms: the Muir-Torre syndrome. *Hum Pathol* 1995; 26(4):422-7.
14. Tiftikçioğlu YÖ, Karaaslan Ö, Aksoy HM, Ozdemir R, Onuk N, Koçer U. [Sebaceous carcinoma: is skin trauma among the etiologic factors?: case reports]. *Türkiye Klinikleri J Med Sci* 2005;25(4):600-2.