

Unusual Tumor in an Interesting Site: Vascular Leiomyoma Originating from the Internal Jugular Vein: Case Report

İnternal Jugular Ven Kökenli Vasküler Leiomyom: Farklı Bir Bölgede Nadir Bir Tümör Olgusu

Sema ZER TOROS, MD,^a
Barış NAİBOĞLU, MD,^a
Çınar AKKAYNAK, MD,^a
Şerike AKKAYNAK MD,^b
Hülya NOSHARI, MD,^a
Özlem YÜKSEL, MD^a

Departments of
^aOtorhinolaryngology/
Head and Neck Surgery,
^bPathology,
Haydarpaşa Numune Hospital,
İSTANBUL

Geliş Tarihi/Received: 08.02.2007
Kabul Tarihi/Accepted: 28.03.2007

Yazışma Adresi/Correspondence:
Sema ZER TOROS, MD
Haydarpaşa Numune Hospital,
Department of Otorhinolaryngology/
Head and Neck Surgery, İSTANBUL
semazertoros@yahoo.com

ABSTRACT Angioleiomyoma is a benign tumor arising from the vascular smooth muscle (tunica media). Most of them are found in the uterus, skin and alimentary tract. It is rarely found in the head and neck area. Occurrences in the ear, the lip, the nasal cavity, the ethmoid sinus, the parotid gland and the larynx have been reported. We presented an unusual case of vascular leiomyoma originating from the left internal jugular vein in a 32 year-old man. To the best of our knowledge this is the first report of vascular leiomyoma originating from the internal jugular vein. All rare tumors like vascular leiomyoma should be kept in mind in the differential diagnosis of neck masses although physical examination findings are relevant with a simple benign mass.

Key Words: Angiomyoma; lymphangiomyoma; jugular veins

ÖZET Anjiyoleiyomiyom, damarsal düz kaslardan köken alan benign bir tümördür. Çoğunlukla uterus, deri ve sindirim kanalında yerleşir. Baş ve boyun bölgesinde görülmesi çok nadirdir. Kulak, dudak, nazal kavite, etmoid sinüs, parotis bezi ve larenks yerleşimli olgular bildirilmiştir. Biz, 32 yaşında erkek hastada sol internal jugular venden köken alan bir vasküler leiomyom olgusu sunduk. Literatürden edindiğimiz bilgilere göre, bu olgu internal jugular venden köken aldığı bildirilen ilk vasküler leiomyom olgusudur. Baş ve boyun kitlelerinin değerlendirilmesinde, fizik muayene bulguları basit benign kitle ile uyumlu olsa da, vasküler leiomyom gibi tüm nadir tümörler akılda tutulmalıdır.

Anahtar Kelimeler: Anjiyomiyom; lenfanjiyomiyom; juguler ven

Türkiye Klinikleri J Cardiovasc Sci 2008, 20:36-40

Vascular leiomyoma (VL) is an uncommon benign tumor composed of smooth muscle cell and vascular endothelium. It originates from the tunica media of veins.¹⁻³ They are also known as angiomyoma, angioleiomyoma or dermal angioma. It can occur anywhere in the body where smooth muscle is found.² According to Enzinger and Weiss, 95% of 7748 leiomyomas occurred in the female genitalia, 3% in the skin, 1.5% in the gastrointestinal tract and the remainder in various other sites.⁴ Those in the head and neck area are rare and occur less than 1%.⁵ Occurrences in the ear, the lip, the nasal cavity, the ethmoid sinus, the parotid gland and the larynx have been reported.⁶

In 1973, Morimoto classified angioleiomyomas into three histological types: solid, cavernous, and venous types. The solid type is more common

in females, and the venous type is more common in males. The cavernous type is the least common type of the three.²

Clinically, VL presents as a solitary, small, painful cutaneous mass of the solid type.¹ It causes pain in 60% of patients.² This tumor is rarely diagnosed before surgery. The usual treatment is excision of the mass and ligation of the feeding vessel.² We present a case of a vascular leiomyoma which was adherent to the upper third of the internal jugular vein.

CASE REPORT

A 32 year-old man presented with a 1 year history of a slowly enlarging nontender left neck swelling. Physical examination showed a 3x2,5 cm. mass located along the anterior edge of the left sternocleidomastoid muscle near the angle of mandible. It was smooth, firm, mobile and nontender. There were no abnormal findings in the head and neck examination. Computed tomography scan with contrast showed an enhanced mass located at the bifurcation of the left carotid artery (Figure 1). Due to its perceived vascular origin, MR angiography was performed. It showed that the mass was not vascular (Figure 2). So it was thought as a simple benign mass and excisional biopsy was planned under general anesthesia. During surgery, the solitary mass was found to be adherent to the adventitia of the left internal jugular vein at the level of bifurcation of the carotid artery. The mass and its capsule were delicately dissected from the internal

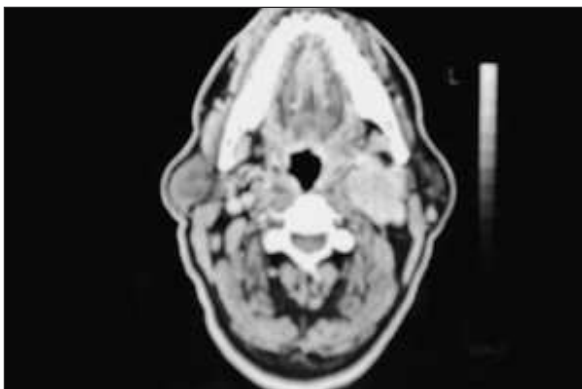


FIGURE 1: Contrast computed tomography scan showing an enhancing left neck mass in the region of the carotid bifurcation.

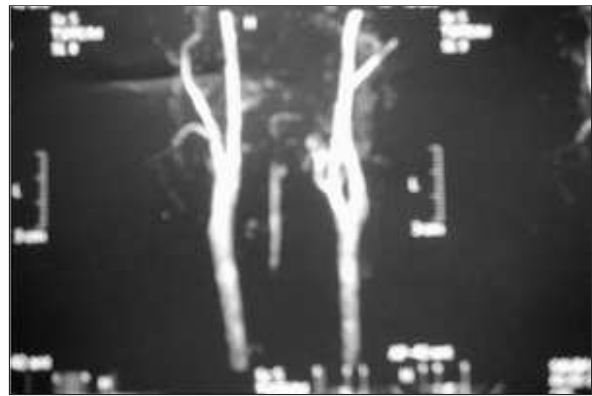


FIGURE 2: MR angiography scan showing the nonvascular mass and differentiating the mass from the paragangliomas arising at carotid bifurcation.

jugular vein, but the jugular vein needed to be repaired because of an injury. There was no postoperative complication. No recurrence is observed.

PATHOLOGY

Grossly the specimen showed an ovoid, firm mass measuring 1.5x1x0.5 cm. The cut surface was solid and pale tan. Histologically, it consisted of a well demarcated nodule of smooth muscle tissue, punctuated with thick walled vessels with partially patent lumina. The inner layers of vessels' smooth muscle were arranged in an orderly circumferential fashion, the outer layers were arranged perpendicular to the inner layers. Areas of myxoid change were seen. The vessels within these tumors lacked internal and external elastic lamina. The tumor was made up predominantly venous vessels, consistent with a venous type of angioleiomyoma. (Figures 3 and 4).

Immunohistochemistry using a peroxidase-antiperoxidase method (PAP) for both alpha smooth muscle actin and CD34 tested positive, confirming the diagnosis of venous type angioleiomyoma. (Figures 5 and 6)

DISCUSSION

Leiomyomas are rare, benign, soft tissue tumors arising from smooth muscle. Smooth muscle tumors arising from the muscle layer of blood vessels are known as vascular leiomyoma or angioleiomyoma.

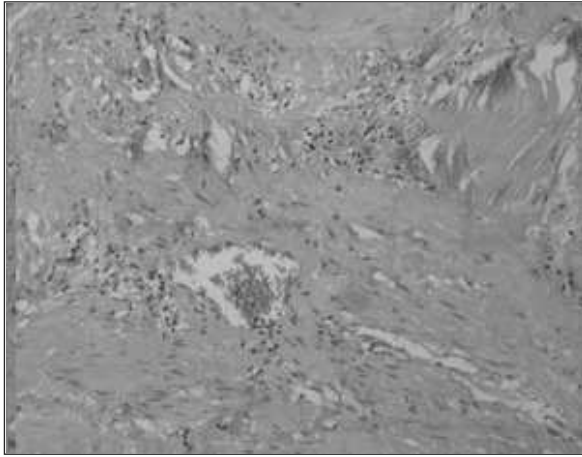


FIGURE 3: The tumor has rich vascular channels with thick muscular vessel walls and intervascular smooth muscle bundle (H&E stain, Magnification X 200).

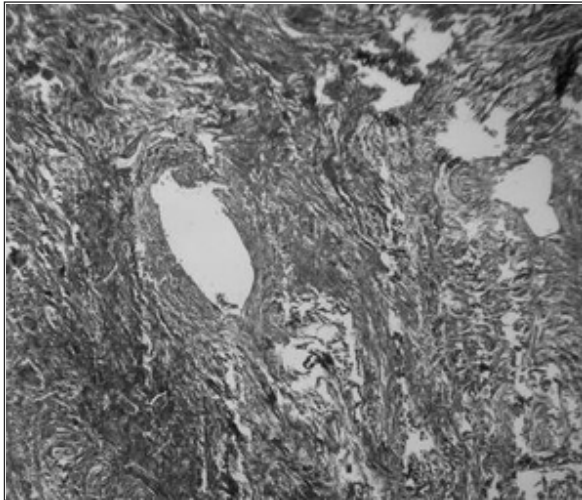


FIGURE 4: Vascular leiomyoma (Mason's Trichrome stain, Magnification X 200)

yoma.^{6,7} It usually occurs in adults, but has been described a few times in children.⁶ A male preponderance was noted in patients with VL of the head and neck.¹

It most commonly arises from the smooth muscle of the female genital tract. The next most common site is smooth muscle of the gastrointestinal system.⁷ Of all leiomyomas in the human

body, less than 1% occur in the head and neck area. Vascular leiomyomas are even less common.⁵

VL can develop in the oral or nasal mucosa, larynx, deep spaces such as parotid space, submandibular space, carotid sheath, facial bones or retropharyngeal space. The auricle and oral and sinonasal cavities are the most commonly reported sites of occurrence in the head and neck.^{1,8}

Most commonly, patients with a leiomyoma present with a slowly enlarging mass that sometimes may be tender.⁶ In our case, there was a 1 year history of a slowly enlarging, nontender mass.

The histogenesis is unclear. Duhig and Ayer proposed that proliferation of smooth muscle wit-

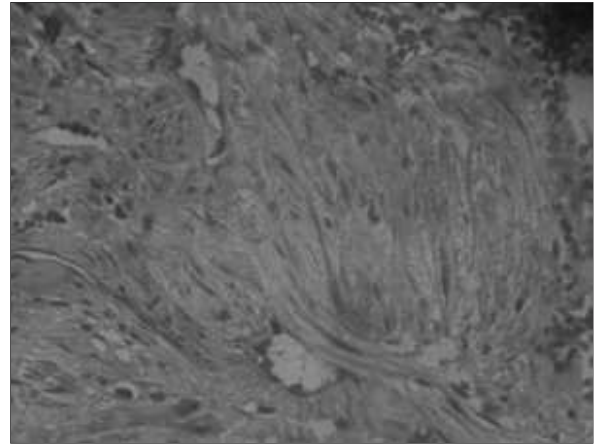


FIGURE 5: Vascular leiomyoma (CD 34 immunohistochemical stain, Magnification X100).



FIGURE 5: Vascular leiomyoma (CD 34 immunohistochemical stain, Magnification X100).

hin a hemangioma produces a vascular leiomyoma and further proliferation produces a simple leiomyoma.⁹ This may explain why some of these tumors may be hypervascular, whereas the more common leiomyoma is more solid and less vascular. It is possible that the lesion may represent a hamartoma rather than a true neoplasm.⁵

On histological examination, smooth muscle bundles and vascular channels surrounded by a thin capsule are seen. Numerous vessels of various sizes, having muscular walls of varying thickness were encompassed by interlacing bundles of smooth muscle. Muscle cells were disposed tangentially from the periphery of the blood vessels to merge with and form a part of the intervascular muscle fascicles. The stroma contained varying amounts of collagen, indicating myxomatous degeneration.¹⁰ Fine needle aspiration is not sufficient to diagnose angioleiomyoma.^{2,8} So, the diagnosis of a leiomyoma is often difficult to make before a histological examination.

In the case we present, the histological diagnosis was done after excisional biopsy.

Morimoto classified these tumors into three histologic subtypes: solid or capillary, cavernous, and venous. The most common type found in the head and neck area is the venous type. *The solid type* has smooth muscle bundles that intertwine and surrounds the vascular channels. *The cavernous type* has dilated vascular channels with less smooth muscle. *The venous type* has vascular channels with thick muscular walls that are easily discerned from smooth muscle bundles.⁷

The presence of pain is related to the histological type of the tumor. The solid type is usually painful, and the venous or cavernous type is painless. If a vascular leiomyoma is deeply seated, it can grow large because of the absence of symptoms. But most vascular leiomyomas are small in size du-

e to their superficial location and are slow growing in nature.¹ Hasegawa et al. suggested that the pain in these tumors may be mediated by the nerve fibers located within the tumor parenchyma. Small nerve fibers were identified within the stroma of 69% of painful tumors.²

Malignant variants of this neoplasm have been reported in rare cases. The distinction between benign and malignant smooth muscle tumors in extra-uterine sites can be difficult. Size, infiltration, bone erosion in significant sites and mitotic index are valuable diagnostic aides.² The most useful histologic indicator of a benign lesion is the absence of mitoses. Several stains such as desmin, vimentin, Masson's trichrome, actin and myosin have been used to identify vascular leiomyomas. However, this spectrum of stains typically is not required for the diagnosis.⁷

Fine needle aspiration cytological examination and imaging studies such as sonography, computed tomography (CT), or magnetic resonance imaging (MRI) have no characteristic findings for preoperative diagnosis. Surgical excision with histological analysis is the only way to make a diagnosis.¹

The histopathologic differential diagnosis for these lesions includes hemangiomas, nasal angiofibromas, fibromyoma, leiomyoblastoma, angioyolipoma, and vascular leiomyosarcoma.⁷ Only one case of vascular leiomyoma located at the carotid bifurcation has been reported by Reiner et al.⁶ Our case is the first report of vascular leiomyoma originating from the internal jugular vein.

Although very rarely seen, vascular leiomyoma must be kept in mind in the differential diagnosis of head and neck masses. Simple excision biopsy is often curative. Recurrence rates are reported to be very low.^{1,2,5,6} In the review by Hachisuga et al, only 2 of 562 angioleiomyomas recurred.¹¹ In our case, there was no recurrence within two years.

REFERENCES

1. Wang CP, Chang YL, Sheen TS. Vascular leiomyoma of the head and neck. *Laryngoscope* 2004;114:661-5.
2. Ramesh P, Annapureddy SR, Khan F, Sutaria PD. Angioleiomyoma: a clinical, pathological and radiological review. *Int J Clin Pract* 2004; 58:587-91.
3. Murano S, Ohmura T, Sugimori S, Furukawa M. Vascular Leiomyoma with abundant adipose cells of the nasal cavity. *Am Jour Otolaryngol* 1998;19: 50-3.
4. Enzinger FM, Weiss SW: *Soft Tissue Tumors* (ed 4). St Lois, MO, Mosby, 2001.p.695-701.
5. Ardekian L, Samet N, Talmi YP, Roth Y, Bendet E. Vascular leiomyoma of the nasal septum. *Otol Head Neck Surg* 1996;114:798-800.
6. Reiner SA, Medina J, Minn KW. Vascular leiomyoma of the carotid sheath simulating a carotid body tumor. *Am Jour Otolaryngol* 1998;19:127-9.
7. Nall AV, Stringer SP, Baughman RA. Vascular leiomyoma of the superior turbinate: First reported case. *Head Neck* 1997;19: 63-7.
8. Shetty SC, Kini U, D'Cruz MN, Hasan S. Angioleiomyoma in the tonsil: An uncommon tumour in a rare site. *British Jour Oral Maxil Surg* 2002;40:169-71.
9. Duhig JT, Ayer JP. Vascular leiomyoma: A study of sixty-one cases. *Arc Pathol Lab Med* 1959; 68: 424-30.
10. Kido T, Sekitani T. Vascular leiomyoma of the parotid gland. *ORL Jour Otorhin Relat Spec* 1989;51:187-91
11. Haschisuga T, Hashimoto H, Munetomo E. Angioleiomyoma-A clinicopathologic reappraisal of 562 cases. *Cancer* 1984; 54: 126-30.