

# An Iliopsoas Abscess Spreading Through an Unusual Location: Case Report

## NADİR LOKALİZASYONA YAYILAN İLİOPSOAS ABSESİ

Hakan ATALAR, MD,<sup>a</sup> Aslı KÖKTENER, MD,<sup>b</sup> Osman Y. YAVUZ, MD,<sup>a</sup>  
İsmail URAŞ, MD,<sup>a</sup> Mikat BOZER, MD<sup>c</sup>

<sup>a</sup>Department of Orthopaedic Surgery, Medical Faculty of Fatih University,

<sup>b</sup>Department of Radiology, Medical Faculty of Fatih University,

<sup>c</sup>Department of General Surgery, Medical Faculty of Fatih University, ANKARA

### Abstract

Iliopsoas abscess is an uncommon and a potentially fatal condition. It is a rarely encountered form of retroperitoneal infection. Primary iliopsoas abscess has an increasing frequency and tends to be present in immunocompromised patients. Although secondary abscess was traditionally associated with tuberculosis of the spine, it is now more commonly related to gastrointestinal disease. Early diagnosis is hindered by a nonspecific presentation. The resulting delays in therapy increase morbidity and mortality. Iliopsoas abscess usually has a paraspinal location and occasionally extends within the fascia to the hip and thigh. Computed tomography scanning should be performed to see the retroperitoneal region in patients who have thigh abscesses since iliopsoas abscess may spread through the femur diaphysis. We report a case of iliopsoas abscess spreading through the femur diaphysis in a patient who had undergone total hip arthroplasty 6 years earlier.

**Key Words:** Psoas abscess, diagnosis, differential tomography scanners, X-ray computed

### Özet

İliopsoas absesi az görülen ve hayatı tehdit eden bir durum olup retroperitoneal enfeksiyonların nadir görülen bir formudur. Primer iliopsoas absesinin sıklığı artmakta olup özellikle immün yetmezlikli hastalarda ortaya çıkma eğilimindedir. Uzun yıllardır sekonder absenin omurga tüberkülozu ile ilişkili olduğu bilinmekle birlikte, günümüzde sekonder abse daha çok gastrointestinal hastalıklarla ilişkilendirilmektedir. Hastalığın non-spesifik semptomlar göstermesi erken tanıyı zorlaştırır. Tedavide gecikme morbidite ve mortaliteyi artırır. İliopsoas absesi genellikle paraspinal lokalizasyonlu olup bazen fasyanın içinden ilerleyerek kalça ve uyluğa doğru yayılır. İliopsoas absesi femur diyafizine doğru ilerleyebildiği için uyluk absesi olan kişilerde retroperitoneal bölgeyi görmek için BT yapılmalıdır. Bu makalede, 6 yıl önce total kalça artroplastisi uygulanmış olan hastada femur diyafizine yayılan iliopsoas absesini tartıştık.

**Anahtar Kelimeler:** İliopsoas absesi, ayırıcı tanı, bilgisayarlı tomografi

Türkiye Klinikleri J Med Sci 2007, 27:290-293

Iliopsoas abscess is an uncommon condition with variable and non-specific presenting features. Primary abscesses are those with no obvious aetiologic cause. In developed countries many cases of secondary iliopsoas abscess recently occur as a complication of Crohn's disease. Previously, Pott's disease was the cause of the majority of iliopsoas abscesses and it still remains an important source of secondary abscesses in

underdeveloped countries. Appropriate therapy for iliopsoas abscess is extraperitoneal drainage and a full course of effective antibiotic treatment.<sup>1</sup> Iliopsoas abscess generally spreads along the muscle sheath. Thus, in some cases it may be palpable below the inguinal ligament on the medial aspect of the inguinal region. In this article we report a case of iliopsoas abscess spreading through an unusual location.

Geliş Tarihi/Received: 12.08.2005

Kabul Tarihi/Accepted: 07.03.2006

**Yazışma Adresi/Correspondence:** Hakan ATALAR, MD  
Medical Faculty of Fatih University,  
Department of Orthopaedic Surgery, ANKARA  
atalarhakan@yahoo.com

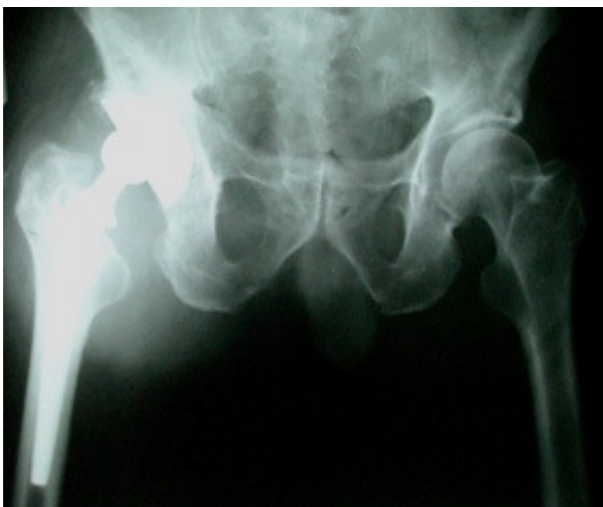Copyright © 2007 by Türkiye Klinikleri

### Case Report

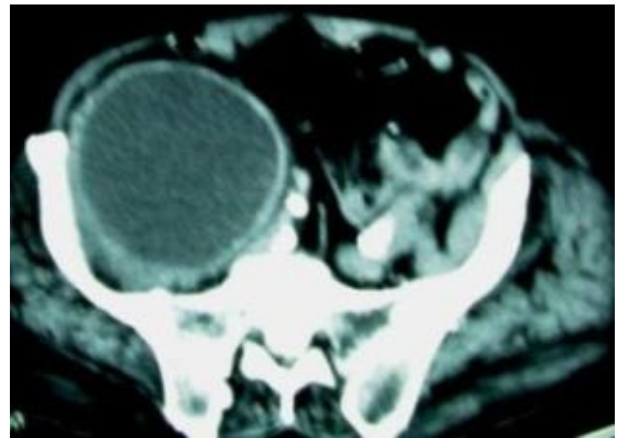
An 82-year-old male presented with a 2 month history of a painful mass in his right groin. Additional symptoms included malaise and weight loss

of 8 kg. The pain was exacerbated with physical activity. The patient's medical history included primary osteoarthritis of the right hip treated with uncemented total hip arthroplasty (THA) by an anterolateral approach at another institution in 1998.

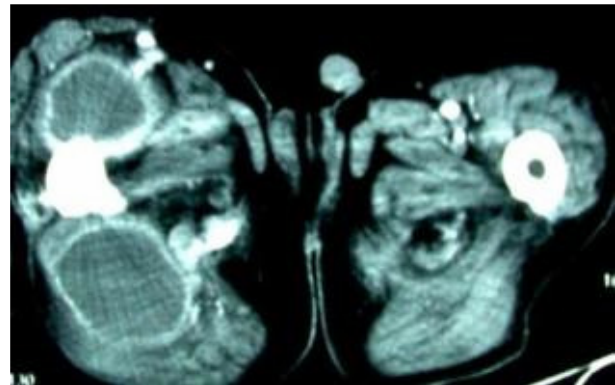
On physical examination the patient was afebrile with right hip tenderness, pain on motion, and a flexion contracture of 20 degrees. In his right groin there was a palpable mass approximately 15 cm in diameter. The patient had a positive iliopsoas sign. Laboratory findings were as follows: Hemoglobin 9.1 g/dL; white blood cell count  $11.000/\text{mm}^3$  with a predominant left shift; erythrocyte sedimentation rate 83 mm/h, C-reactive protein 115 mg/dL. Urinalysis was normal and urine cultures yielded no growth. A barium colon radiograph was obtained to rule out other possible sources of infection with no pathological findings. Parasitological assay of the feces and serological reactions for brucellosis, salmonella, HIV, HBV, and HBC were negative. Tuberculin reaction for tuberculosis was also negative. Plain abdominal radiographs revealed loss of the iliopsoas shadow and radiographs of the hip joint showed no loosening of the hip prosthesis or



**Figure 1.** Radiographs of the hip joint showed no loosening of the hip prosthesis.



**Figure 2.** CT scan showed a 34 x 11 x 12 cm fluid collection in the right groin adjacent to the iliopsoas muscle, extending toward the iliac vessels.



**Figure 3.** CT scan showed a fluid collection extending toward the femoral diaphysis.

bone destruction (Figure 1). Computed tomography (CT) scan revealed a 34 x 11 x 12 cm fluid collection in the right groin adjacent to the iliopsoas muscle, extending toward the iliac vessels and femoral diaphysis (Figures 2 and 3). Magnetic resonance imaging of the spine showed no pathological findings except spondyloarthrosis. The lesion was visualized and aspirated under ultrasound guidance and 2000 mL of purulent material was drained. A catheter was inserted percutaneously into the abscess cavity for further drainage of purulent material and the cavity was irrigated with antiseptic solution. The catheter was removed 2 weeks later. Cultures of the aspi-

rate yielded *Staphylococcus aureus*. The patient received intravenous antistaphylococcal penicillin (nafcillin 1 g 4 times a day) for 6 weeks. Two months later, he remained asymptomatic without evidence of infection and a follow-up CT scan showed recurrence of fluid collection. Follow-up laboratory findings were as follows: Hemoglobin 9 g/dL; white blood cell count 9.700/mm<sup>3</sup>, erythrocyte sedimentation rate 50 mm/h, C-reactive protein 15 mg/dL. We planned surgical drainage but the patient rejected it because he had no medical insurance. We obtained informed consent from the patient for publication of this report.

### Discussion

Iliopsoas abscesses are classified as primary or secondary. Primary abscesses have no obvious source of infection.<sup>2</sup> In contrast, secondary iliopsoas abscesses occur as a consequence of direct extension of an adjacent infected organ. Iliopsoas abscesses may also occur as a complication of femoral nerve block or epidural anaesthesia.<sup>2,3</sup>

A history of trauma and suppurative lymphadenitis may be predisposing factors for iliopsoas abscess, and *S. aureus* is isolated in 90% of primary abscesses.<sup>4</sup> Secondary iliopsoas abscesses are usually caused by enteric bacteria.<sup>1,4</sup> Lymphogranuloma venereum and brucellosis were reported in 2 patients with iliopsoas abscess.<sup>5</sup> Pott's disease still remains an important source of secondary iliopsoas abscess in underdeveloped countries. Common causes for the spread of the infection to the retroperitoneum are Crohn's disease, carcinoma of the intestine, pyelonephritis, pleural empyema, renal disease, and complications of abdominal, urologic, or spinal surgery.<sup>1,4,6</sup> In our patient we could not determine the exact cause of infection. Although may be directly related to the previous surgery, we considered this unlikely since the abscess appeared 6 years after the operation. However, due to the surgical intervention the normal relationships between muscle groups may have changed and as a result the iliopsoas abscess may have spread through the femoral diaphysis.

Ultrasonography is less expensive and is easily performed; however CT scanning has a detection sensitivity of nearly 100% and is considered to be the gold standard.<sup>1</sup> Rarely retroperitoneal tumors such as schwannoma or lymphoma are misdiagnosed as iliopsoas abscess based on ultrasound and CT scans.<sup>7</sup>

In our patient, aspirate cultures yielded *S. aureus*. The patient received intravenous antistaphylococcal penicillin (nafcillin 1 g 4 times a day) for 6 weeks. We continued medical therapy for 4 weeks after cessation of drainage. However, 2 months later a follow-up CT scan showed recurrence of fluid collection.

In normal radiographs, there was no evidence of prosthesis loosening or bone changes related to the infection (Figure 1). For this reason, we did not consider prosthesis infection for the diagnosis.

### Conclusion

Iliopsoas abscess usually remains localized in a paraspinal location, and typically follows the iliopsoas muscle to a point below the inguinal ligament on the medial aspect of the upper thigh and hip.<sup>8</sup> We report a patient with iliopsoas abscess that extended to the hip joint and around the femoral diaphysis. The patient had undergone THA operation 6 years earlier. In this operation the iliopsoas tendon could have been detached from the lesser trochanter. So, any pus tracking along the iliopsoas muscle would therefore extend to the femoral diaphysis. CT should be performed to see the extent of the abscess in the groin or thigh.

### Acknowledgement

*The authors wish to thank Greg Hammond for editorial assistance.*

### REFERENCES

1. Melissas J, Romanos J, de Bree E, Schoretsanitis G, Askoxylakis J, Tsiftsis DD. Primary psoas abscess. Report of three cases. *Acta Chir Belg* 2002;102:114-7.
2. Adam F, Jaziri S, Chauvin M. Psoas abscess complicating femoral nerve block catheter. *Anesthesiology* 2003;99:230-1.

3. Aota Y, Onari K, Suga Y. Iliopsoas abscess and persistent radiculopathy: A rare complication of continuous infusion techniques of epidural anesthesia. *Anesthesiology* 2002;96:1023-5.
4. Buttaro M, Gonzalez Della Valle A, Piccaluga F. Psoas abscess associated with infected total hip arthroplasty. *J Arthroplasty* 2002;17:230-4.
5. Capar Y, Cesur S, Yuksel O, Kurt H, Sozen TH. Case report: Psoas abscess due to brucellosis. *Mikrobiyol Bul* 2002;36:219-21.
6. Korovessis P, Petsinis G, Papazisis Z. Unilateral psoas abscess following posterior transpedicular stabilization of the lumbar spine. *Eur Spine J* 2000;9: 588-90.
7. Kishi Y, Kajiwara S, Seta S, Kawauchi N, Suzuki T, Sasaki K. Retroperitoneal schwannoma misdiagnosed as a psoas abscess: report of a case. *Surg Today* 2002;32: 849-52.
8. Napier-Hemy RD, Jarratt JW, O'Flynn KJ. An "orthopaedic" psoas abscess. *Br J Urol* 1997;79:291-2.