

Femoral Artery Stenosis Due to Perivascular Mass: Endovascular Treatment of an Intraoperatively Detected Condition

Perivasküler Yumuşak Doku Kalsifikasyonuna Bağlı Femoral Arter Stenozu: Operasyon Esnasında Tespit Edilen Durumun Endovasküler Tedavisi

^{1b} Hamit Serdar BAŞBUĞ^a, ^{1b} Volkan KIZILGÖZ^b

^aDepartment of Cardiovascular Surgery, Kafkas University Faculty of Medicine, Kars, TURKEY

^bDepartment of Radiology, Kafkas University Faculty of Medicine, Kars, TURKEY

ABSTRACT Through the past decade, the increased experience and technical advances in endovascular procedures enabled the use of percutaneous approaches more frequently to manage the peripheral arterial disease. However, despite endoluminal treatments' success in arterial lesions, their application in some unique circumstances is still debatable. These unfavorable conditions include anatomical location, functional impairment, and the factors affecting the intravascular flow dynamics. In this case report, an endovascular intervention of a patient who applied with intermittent claudication symptoms on his right leg was reported. Upon realizing the lesion was extravascular instead of being intravascular during the intraoperative course, the lesion was diagnosed with detailed imaging techniques. In diagnosis, a soft tissue calcification compressing the superficial femoral artery with a mass effect causing stenosis was detected. This case report is original for being the first case in the current literature and reported with detailed images.

Keywords: Femoral artery; soft tissue neoplasms; calcinosis; endovascular procedures

ÖZET Son 10 yılda endovasküler yöntemlerde artan tecrübe ve teknik gelişimler, periferik arter hastalığı yönetiminde perkütan yaklaşımların daha sık kullanılmasını mümkün kılmıştır. Fakat endoluminal tedavilerin, arteriyel lezyonlardaki başarısına rağmen bazı özgün koşullarda kullanılması hâlen tartışmalıdır. Bu istenmeyen durumlar, anatomik konum, fonksiyonel bozukluk ve intravasküler akış dinamiklerini etkileyen faktörleri kapsamaktadır. Bu olgu sunumunda, sağ bacağına intermittan klodikasyo şikâyetiyle başvuran hastaya uygulanan endovasküler girişim sunulmuştur. Lezyonun intravasküler değil de ekstravasküler olduğunun, intraoperatif süreçte farkına varılması üzerine detaylı görüntüleme yöntemleri ile lezyon teşhis edilmiştir. Teşhiste, kitle etkisiyle süperfisiyal femoral artere bası uygulayarak stenoza yol açan bir yumuşak doku kalsifikasyonu tespit edilmiştir. Mevcut literatürde ilk olması ve detaylı görüntülemelerle raporlanması bakımından bu olgu sunumu orijinaldir.

Anahtar Kelimeler: Femoral arter; yumuşak doku neoplazileri; kalsinoz; endovasküler prosedürler

Significant advances have been achieved during the last decade in endoluminal intervention technology to manage peripheral arterial disease (PAD).¹ The endovascular interventions have been widely accepted due to their success in treating the lower extremity's atherosclerotic arterial disease and their minimally invasive nature.² PAD is one of the main manifestations of atherosclerosis, affecting 3% of

people between 40 and 59 years.³ This proportion is increased by 20% over the age of 70.⁴ In about 5% of the PAD cases, the symptoms progress to intermittent claudication and critical limb ischemia during the disease. The risk factors for PAD progression include diabetes mellitus, advanced age, and smoking.¹ PAD is a condition requiring urgent optimized treatment because endoluminal therapies often have a limited

Correspondence: Hamit Serdar BAŞBUĞ

Department of Cardiovascular Surgery, Kafkas University Faculty of Medicine, Kars, TURKEY/TÜRKİYE

E-mail: s_basbug@hotmail.com



Peer review under responsibility of Türkiye Klinikleri Cardiovascular Sciences.

Received: 25 Feb 2021

Received in revised form: 24 Apr 2021

Accepted: 10 May 2021

Available online: 25 May 2021

2146-9032 / Copyright © 2021 by Türkiye Klinikleri. This is an open access article under the CC BY-NC-ND license (<http://creativecommons.org/licenses/by-nc-nd/4.0/>).

life span. Despite a successful intervention with transluminal angioplasty or stenting, postoperative restenosis remains a significant concern in femoropopliteal segments.² This paper reports an extraordinary case of a superficial femoral artery compression due to an external soft tissue mass and its successful endovascular treatment. The radiological images are unique, and the diagnosis is surprising with no similar case in the available literature.

CASE REPORT

A 63-year-old male applied to the cardiovascular surgery outpatient clinic with the symptom of intermittent claudication on his right leg. There was no trauma history in his anamnesis. There were no signs of hypoperfusion or leg ischemia, according to the physical examination. The ankle-brachial index was 0.6, and the distal pulses were slightly palpable. Doppler ultrasound and computerized tomography (CT) angiography images demonstrated a single 90% short segmental solitary lesion in the right superficial femoral artery and a monophasic current pattern in the infrapopliteal arteries. Endovascular intervention was then planned. The patient was monitored in a hybrid operating room, and antisepsis was performed bilaterally. 8F sheath was introduced through the right common femoral artery in an ipsilateral antegrade manner. The dynamic angiography images revealed a single 90% lesion in the right superficial femoral artery (SFA). The lesion was passed with a

micro support catheter over a 0.035/260 cm stiff guidewire, and the angioplasty was performed with a drug-coated (Paclitaxel) 6.0x80 mm balloon under 12 atm pressure (Figure 1A, B).² Although the inflation was successful, a remarkable instant recoil of the stenotic segment during the balloon's deflation was noticed (Figure 1C). A soft tissue mass causing external compression of the artery lying along the SFA was detected with a careful inspection.

Moreover, the control angiography revealed residual stenosis and endovascular indentation due to the external mass effect (Figure 2A). A 6.0x40 mm self-expandable stent was placed (Figure 2B), and a 7.0x60 mm balloon was inflated inside with 16 atm pressure for post-dilatation (Figure 2C, D). The control angiography revealed complete patency of the stented segment of the right SFA. Two cc heparin and 100 cc opaque were infused during the intervention. No complication occurred.

The patient was recalled to be examined radiologically after one month to diagnose the soft tissue mass causing arterial compression. The radiological findings were remarkable. The anteroposterior radiography of the right femur indicated a close relationship of the soft tissue calcification with the SFA stent. The stent indentation due to the soft tissue calcification was observed on the radiography (Figure 3). A cross-sectional imaging study was performed to distinguish a soft tissue calcification and a calcific soft tissue lesion. The femur's CT showed a close rela-

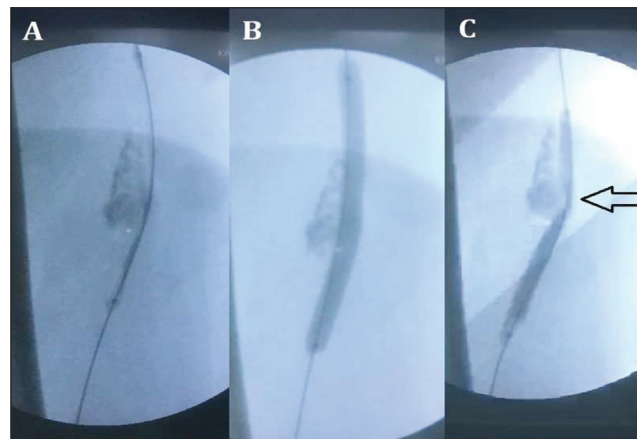


FIGURE 1: Placing the balloon over the guidewire and set in the midst (A). Inflated balloon (B). Deflation of the balloon and the indentation (arrow) due to perivascular soft tissue mass compression remained after the balloon angioplasty (C).

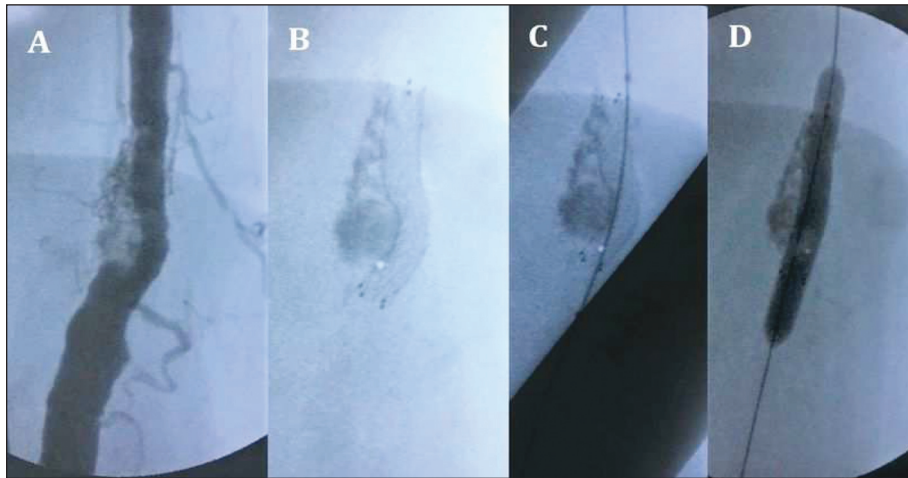


FIGURE 2: Control angiography shows the partial indentation due to the perivascular soft tissue mass (A). A 6.0x40 mm self-expandable stent implanted (B). An oversized (7.0x60 mm) balloon was placed over the wire (C) and inflated for post-dilatation (D).

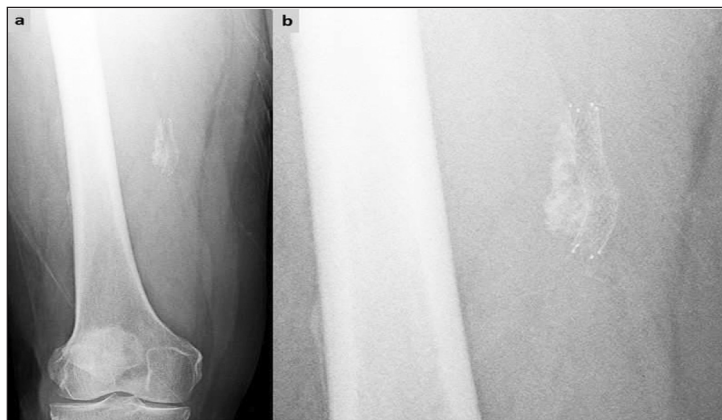


FIGURE 3: Anteroposterior radiography of the femur (a) and magnification of the lesion area (b). Due to the close relationship with the calcific lesion, the superficial femoral artery stent indentation was observed.

tionship between the lesion and the SFA stent in axial images (Figure 4). Although there was no obvious mass lesion, an amorphous soft tissue calcification on the axial plane and reconstructed coronal plane images was observed. Magnetic resonance (MR) imaging was also performed as its superiority over CT imaging in verifying the soft tissue lesions. The MR images depicted heterogenous hypointense signals in the periarterial region in T1 weighted and T2 weighted images at the same levels on axial MR images (Figure 5). Depending on the axial plane CT images, the radiological diagnosis concluded with no signs of a particular lesion, revealing only a simple calcification of the soft tissue in the periarterial location, causing this severe SFA stenosis. No further intervention was needed for the mass as the intravascular

flow dynamics were reinstated with successful endoluminal treatment. To prevent stent restenosis, we prescribed acetyl salicylic acid 100 mg/day, clopidogrel 75 mg/day and atorvastatin 10 mg/day.

Written informed consent was obtained from the patient for publication of this case report and accompanying images. A copy of the written consent is available for review by the Editor-in-Chief of this journal on request.

DISCUSSION

The clinical significance of the early detection of the lower extremity PAD gained an increasing acknowledgment in recent years as it may be a manifestation of a generalized atherosclerotic or atherothrombotic

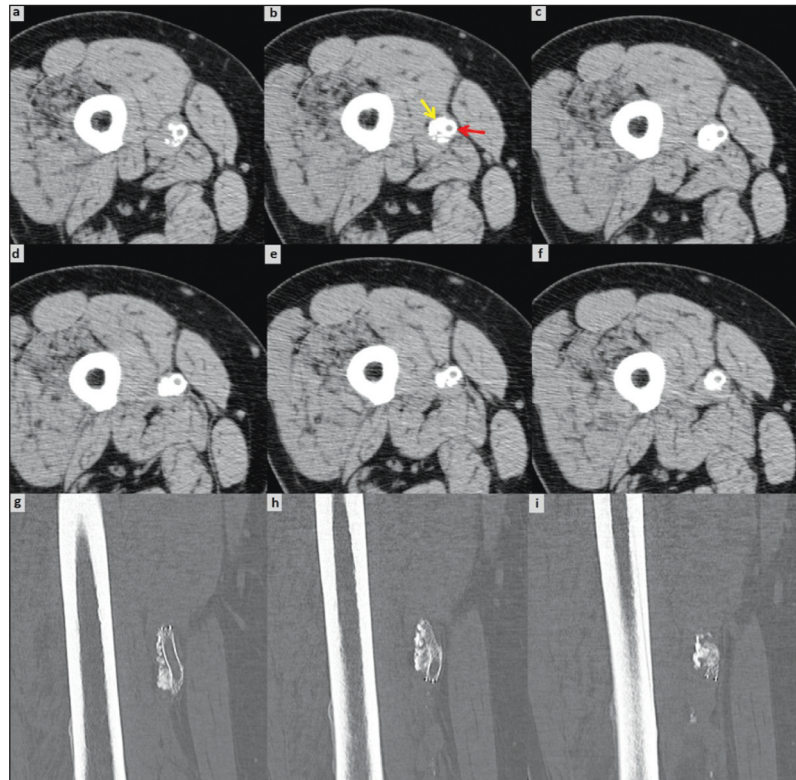


FIGURE 4: Consecutive axial plane computed tomography images (a-f) and reformatted coronal images (g-i) of the femur. Perivascular soft tissue calcification (left yellow arrow) was observed on the lateral side of the superficial femoral artery stent (right red arrow) (b). Coronal computed tomography images showed the indentation of the stent clearly.

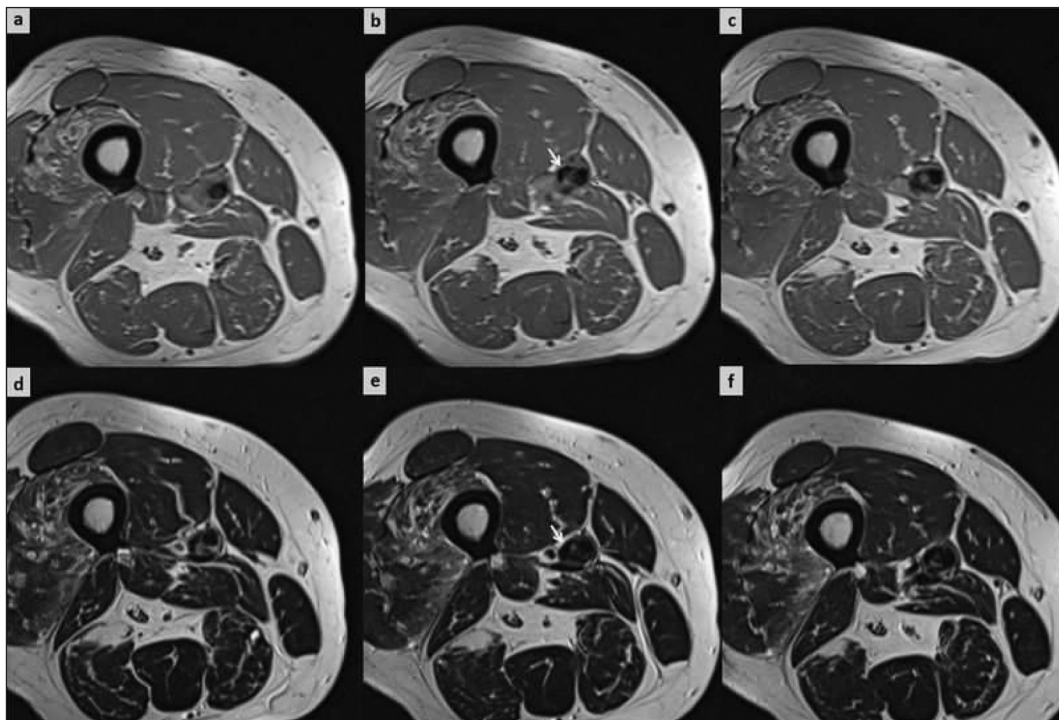


FIGURE 5: Consecutive axial plane T1 weighted (a-c) and T2 weighted (d-f) images of the femur. The left yellow arrow indicates the soft tissue calcification's localization, and the right red arrow depicts the superficial femoral artery (b, e).

disease.⁴ Dotter and Judkins initially performed the catheter-based revascularization technique in 1964.⁵ However, developments in endovascular techniques have revolutionized over the last decade to treat lower-extremity PAD.⁶ These remarkable technological improvements, along with the patients' preferences, have changed the treatment strategies from traditional open surgery toward less invasive lower-morbidity percutaneous endovascular interventions.⁷

Anatomically, arterial lesions are mostly located in the femoropopliteal and tibial arteries (70%), and the rest 30% of the lesions are seen in iliac arteries.¹ Femoropopliteal lesions and their endovascular treatments are complicated because SFA is one of the longest arteries in the body with its 30-centimeter length. SFA is also dynamically active according to the articular movements of hip and knee joints. Besides, low shear stress and spiral blood flow make SFA prone to atherosclerosis.²

In this case, an SFA lesion was detected and treated with endovascular methods, including balloon and stenting. The preliminary diagnosis was made via patient history (intermittent claudication), physical examination (distal pulse deficit), ankle-brachial index (abnormal, <0.9), Doppler ultrasound, and CT angiography. The last two imaging tests' radiologic reports mentioned a 90% SFA lesion, further implying an intraluminal solitary atherosclerotic lesion. These reports mislead and prevented us from evaluating the stenosis correctly before the endovascular intervention. Percutaneous transluminal angioplasty was eventually planned. However, the intraoperative imaging with dynamic angiography revealed the SFA lesion to be extravascular. The inflated balloon and the instant collapse during the early deflation uncovered a perivascular mass constricting the SFA externally. The cause of the stenosis thus became clear. We had two choices of intervention. The first option was stenting the stenosis to maintain the luminal patency and clearance. The second option was to excise the perivascular mass to remove the artery's constriction with open surgery. We preferred the first option as it was less invasive and it would give an instant result. The second option was not selected because it was located deep inside the quadriceps muscles under Hunter's canal. Its removal would be an extensive operation having the risk for ar-

terial injury. Difficulties in the postoperative recovery period and the permanent incision scar are another reason concerning the patient's will. The arterial patency was provided via stenting, and the mass was left in place. The patient's symptoms were subsided, and the pulses returned to normal.

The advanced technology and improved surgical experiences enabled almost all anatomical lesions to be treated via catheter-based methods.⁷ Although intravascular lesions cause most arterial stenoses, extravascular factors may also cause arterial stenosis. In this case, the etiology was a simple calcification with perivascular location. The calcification was heterotopic. The heterotopic calcifications are divided into three groups according to the condition of the tissue and serum calcium phosphate levels; dystrophic, idiopathic and metastatic calcifications.⁸ In differential diagnosis, perivascular epitheloid cell tumors and IgG4-related disease complicated with perivascular lesions should always be assessed.^{9,10} In conclusion, a solitary lesion with no extensive atherosclerosis throughout the artery should always be considered for an extravascular pathology. This case demonstrates that perivascular factors may seldomly cause vascular constriction.

Source of Finance

During this study, no financial or spiritual support was received neither from any pharmaceutical company that has a direct connection with the research subject, nor from a company that provides or produces medical instruments and materials which may negatively affect the evaluation process of this study.

Conflict of Interest

No conflicts of interest between the authors and / or family members of the scientific and medical committee members or members of the potential conflicts of interest, counseling, expertise, working conditions, share holding and similar situations in any firm.

Authorship Contributions

Idea/Concept: Hamit Serdar Başbuğ; **Design:** Hamit Serdar Başbuğ; **Control/Supervision:** Volkan Kızılgöz; **Data Collection and/or Processing:** Volkan Kızılgöz; **Analysis and/or Interpretation:** Hamit Serdar Başbuğ, Volkan Kızılgöz; **Literature Review:** Hamit Serdar Başbuğ; **Writing the Article:** Hamit Serdar Başbuğ, Volkan Kızılgöz; **Critical Review:** Volkan Kızılgöz; **References and Fundings:** Volkan Kızılgöz; **Materials:** Hamit Serdar Başbuğ.

REFERENCES

1. Zeller T. Current state of endovascular treatment of femoro-popliteal artery disease. *Vasc Med.* 2007;12(3):223-34. [[Crossref](#)] [[PubMed](#)]
2. Herten M, Torsello GB, Schönefeld E, Stahlhoff S. Critical appraisal of paclitaxel balloon angioplasty for femoral-popliteal arterial disease. *Vasc Health Risk Manag.* 2016;12:341-56. [[Crossref](#)] [[PubMed](#)] [[PMC](#)]
3. Newman AB, Shemanski L, Manolio TA,ushman M, Mittelmark M, Polak JF, et al. Ankle-arm index as a predictor of cardiovascular disease and mortality in the Cardiovascular Health Study. The Cardiovascular Health Study Group. *Arterioscler Thromb Vasc Biol.* 1999;19(3):538-45. [[Crossref](#)] [[PubMed](#)]
4. Diehm C, Schuster A, Allenberg JR, Darius H, Haberl R, Lange S, et al. High prevalence of peripheral arterial disease and co-morbidity in 6880 primary care patients: cross-sectional study. *Atherosclerosis.* 2004;172(1):95-105. [[Crossref](#)] [[PubMed](#)]
5. Dotter CT, Judkins MP. Transluminal treatment of arteriosclerotic obstruction. description of a new technic and a preliminary report of its application. *Circulation.* 1964;30:654-70. [[Crossref](#)] [[PubMed](#)]
6. Antoniou GA, Chalmers N, Georgiadis GS, Lazarides MK, Antoniou SA, Serracino-Inglott F, et al. A meta-analysis of endovascular versus surgical reconstruction of femoropopliteal arterial disease. *J Vasc Surg.* 2013;57(1):242-53. [[Crossref](#)] [[PubMed](#)]
7. White CJ, Gray WA. Endovascular therapies for peripheral arterial disease: an evidence-based review. *Circulation.* 2007;116(19):2203-15. [[Crossref](#)] [[PubMed](#)]
8. Elgazzar AH. Diagnosis of soft tissue calcification. *Orthopedic Nuclear Medicine.* 1st ed. Berlin, Heidelberg: Springer; 2004. p.323-45. [[Crossref](#)]
9. Tan Y, Zhang H, Xiao EH. Perivascular epithelioid cell tumour: dynamic CT, MRI and clinicopathological characteristics--analysis of 32 cases and review of the literature. *Clin Radiol.* 2013;68(6):555-61. [[Crossref](#)] [[PubMed](#)]
10. Ebe H, Tsuboi H, Hagiya C, Takahashi H, Yokosawa M, Hagiwara S, et al. Clinical features of patients with IgG4-related disease complicated with perivascular lesions. *Mod Rheumatol.* 2015;25(1):105-9. [[Crossref](#)] [[PubMed](#)]