

Acute Repair of Traumatic Lumbar Hernia: Case Report

Travmatik Lumbar Herninin Erken Onarımı

Nezih AKKAPULU,^a
İskent ATAMAN,^b
Belma KIYMAZASLAN^c

Departments of
^aGeneral Surgery,
^bOrthopedics and Traumatology,
^cRadiology,
Muş State Hospital, Muş

Geliş Tarihi/Received: 08.04.2013
Kabul Tarihi/Accepted: 30.08.2013

Yazışma Adresi/Correspondence:
Nezih AKKAPULU
Muş State Hospital,
Department of General Surgery, Muş,
TÜRKİYE/TURKEY
akkapulu@gmail.com

ABSTRACT Traumatic lumbar hernia occurs very infrequently and is due to blunt abdominal trauma. Its diagnosis depends on clinical evaluations and the aid of imaging tests such as computed tomography. The timing and approach of definitive treatment is controversial because of the risks of strangulation and recurrence. We present a 53-year-old man who sustained a crushing injury and herniation of the sigmoid colon within Petit's triangle as revealed by computed tomography. To repair the herniation, a polypropylene mesh was fixed inferiorly to the iliac crest via laparotomy under emergency circumstances. There was no evidence of recurrence at one year after this procedure. This technique may be useful in preventing the recurrence of traumatic lumbar hernia after repair.

Key Words: Hernia; lumbosacral region; surgical mesh; wounds and injuries

ÖZET Travmatik lumbar fıtık künt karın travmasına bağlı gelişebilen nadir bir hastalıktır. Travmatik lumbar fıtık tanısı klinik değerlendirme ve bilgisayarlı tomografi gibi yardımcı görüntüleme yöntemleri ile konulur. Kesin tedavi cerrahi olmakla birlikte, rekürrens ve strangülasyon riski nedeniyle cerrahinin zamanlanması ve şekli tartışmalıdır. Trafik kazası sonrası bilgisayarlı tomografi yardımıyla Petit Üçgeni'nden sol kolonun fıtıklaşması saptanan 53 yaşında erkek hasta olgu olarak sunulmuştur. Fıtık tamiri, acil şartlarda yapılan laparotomi ile ilyak çıkıntının inferioruna polipropilen yama konularak sağlandı. Ameliyattan 1 yıl sonra yapılan değerlendirmede tekrarlama bulgusu yoktu. Bu teknik, travmatik lumbar fıtığın onarım sonrası rekürrensi önlemede kullanışlı bir yöntem olabilir.

Anahtar Kelimeler: Fıtık; lumbosakral bölge; cerrahi ağ; yaralar ve yaralanmalar

Türkiye Klinikleri J Case Rep 2013;21(4):179-81

Traumatic lumbar hernia (TLH) refers to the migration of the intraperitoneal or extraperitoneal contents through an acquired defect in the posteriolateral abdominal wall due to trauma. TLH occurs very rarely and the literature contains fewer than 100 cases. Many treatment methods have been described, yet there is a lack of consensus about the definitive treatment of TLH.¹⁻⁵ We report a case of TLH that is in early repair with a mesh placed inferiorly in the iliac crest.

CASE REPORT

A 53-year-old man presented to emergency service after a motor vehicle accident. The accident caused the patient's body to be compressed between an agrimotor and the ground after the agrimotor fell onto the patient. He was awake and alert, complaining only of left flank pain, and his vital signs were normal and stable (blood pressure 120/70 mmHg, heart beat 85 bpm). His physical examination was unremarkable, although the patient's left

flank area was bruised and ecchymotic. Laboratory tests revealed a hemoglobin level of 13 g/dL and a white blood cell count of 14000/mm³. Abdominal and pelvic computed tomography (CT) was performed. CT scans revealed a flank hematoma, a left lumbar hernia with separation of the oblique muscles from the iliac crest, and partial herniation of the left colon (Figure 1).

An emergency laparotomy was performed as there was no pathological finding without herniation. The lateral peritoneum was incised, the left colon segment was reduced, its color was palely and mesentery was edematous. The colon segment's color returned normally after reduction, and then the borders of the defect were cleared. A 4x6 cm defect underlying the iliac crest was identified. The inner surface of the iliac crest was cleared and prepared rigorously for mesh replacement. Three holes in the iliac crest at 2 cm intervals were created by a 5-mm drill bit. The polypropylene mesh was placed on the inner surface of the iliac crest and fixed to the holes with nonabsorbable sutures inferiorly. Then, the mesh was overlapped with the musculofacial defect and was fixed by nonabsorbable sutures in an interrupted fashion superiorly, anteriorly and posteriorly. A hemovac drain was placed over the mesh and the lateral peritoneum was closed over them. The patient had an uneventful recovery, as the drain was removed on the second postoperative day and he was discharged on the fourth postoperative day. At one year review, there was no evidence of recurrence by clinical evaluation or CT scans (Figure 2).

DISCUSSION

The first traumatic lumbar hernia was reported by Selby in 1906.⁶ After the first report to the review of this case, there have been exactly 82 adult cases of TLH reported in the English literature.^{1,5,7-17} The pathophysiology of TLH contains lateral shearing forces in addition to a suddenly increased intra-abdominal pressure due to deceleration that could be caused by a fall or a high speed motor vehicle collision.³⁻⁵ These mechanisms may lead to a rupture of the muscles in anatomically weak areas, particularly in Petit's triangle inferiorly and in Grynfeltt's trian-

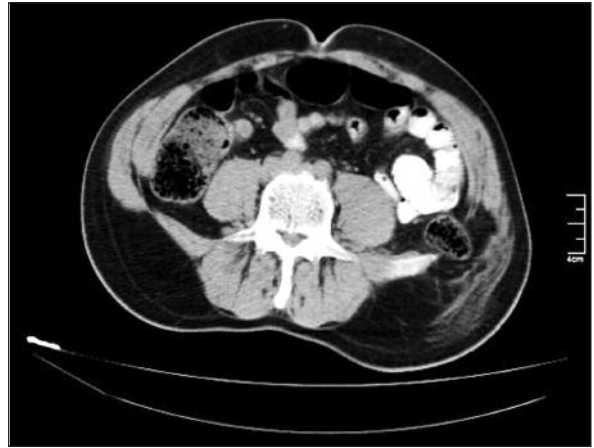


FIGURE 1: Computed tomography showed a colon segment herniated through the wall defect.

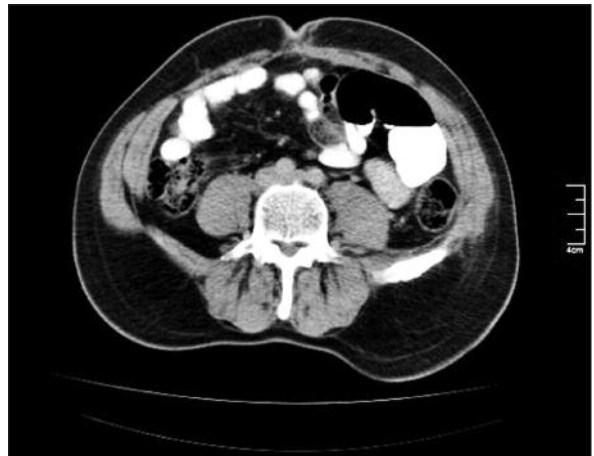

FIGURE 2: A computed tomography scene of the patient at six months after repair.

gle superiorly. A recent review suggests that TLH occurs more often in Petit's triangle than in Grynfeltt's triangle, with rates of 70% and 9%, respectively.⁵

The diagnosis of TLH requires a high level of clinical evaluation because there are no specific symptoms. Thirty-one percent of cases reported had a palpable flank hernia, while other symptoms may include skin bruising, ecchymosis, or hematoma. Therefore, clinicians cannot rely just on the physical examination to establish a diagnosis.^{3,5,13,14} Abdominal and pelvic CT scans have accurately guided surgeons during hemodynamically stable blunt abdominal trauma cases, as these scans allow for the evaluation of the anatomy of the ruptured muscle layers, the hernia contents, and any coexisting intra-abdominal injury.¹⁸

The management strategy of TLH varies widely. There currently is no consensus about the timing and approaches of surgery. A recent review reported that the rates of immediate and delayed repair are similar (41% and 40%, respectively), but follow-up data are insufficient for a conclusion.⁵ Some authors suggest that patients with incarceration and strangulation risks and who have a high incidence of coexistent intra-abdominal injuries (as high as 61%) should undergo immediate repair, and in similar with our case, Esposito and Fedorak suggested that the presence of a TLH alone is an indication for laparotomy.^{4,7,13,19} Another dilemma is whether to go with open or laparoscopic approaches. A prospective study by Moreno-Egea et al. compared laparoscopic and open repair for lumbar hernias. The mean operating time, analgesic consumption, hospital stay, and the time to return to normal activity were significantly less in the laparoscopic group. There were patients with higher ASA scores, diffuse hernias, and longer follow-ups in the open surgery group, while morbidity and recurrence rate are similar in both of groups.²

Repair methods are widely varied for both la-

paroscopic and open surgery and for both extraperitoneal or transperitoneal approaches. Primary repair is often not possible, and though it might be preferred for small defects, repair of musculofacial flaps should be delayed and repaired extraperitoneally.^{4,11} In spite of scant data for long term follow-up for recurrence, mesh repair seems to be the best way to definitively treat TLH and is the standard treatment for other types of lumbar hernias.^{2,5} However, the placement of mesh is still a challenge for surgeons, and the use of iliac crest sutures to fix mesh during TLH repair have been described earlier.^{8,16} This is a safe method for TLH repair, although injury to the lateral femoral cutaneous nerve and the S1 nerve root must be avoided during mesh placement.¹⁶ Recurrence of this type of repair was reported in 2 of 30 patients by Yee et al.²⁰

In conclusion, these hernias are rare, need a suspicion for early diagnosis, and are a challenge to treat. We report a new and different technique for a mesh fixation to the iliac crest to repair a TLH. This method is safe and can decrease the risk of recurrence even for immediate repair of TLH.

REFERENCES

- Bathla L, Davies E, Fitzgibbons RJ Jr, Cemaj S. Timing of traumatic lumbar hernia repair: is delayed repair safe? Report of two cases and review of the literature. *Hernia* 2011;15(2): 205-9.
- Moreno-Egea A, Alcaraz AC, Cuervo MC. Surgical options in lumbar hernia: laparoscopic versus open repair. A long-term prospective study. *Surg Innov* 2013;20(4):331-44.
- Crandall M, Popowich D, Shapiro M, West M. Posttraumatic hernias: historical overview and review of the literature. *Am Surg* 2007;73(9): 845-50.
- Stamatiou D, Skandalakis JE, Skandalakis LJ, Mirilas P. Lumbar hernia: surgical anatomy, embryology, and technique of repair. *Am Surg* 2009;75(3):202-7.
- Burt BM, Afifi HY, Wantz GE, Barie PS. Traumatic lumbar hernia: report of cases and comprehensive review of the literature. *J Trauma* 2004;57(6):1361-70.
- Selby C. Direct abdominal hernia of traumatic origin. *JAMA* 1906;47:1485-6.
- Shuhaiber J, Dunn T, Evans A, Fishman D, Meroletti G, Salzman S. Traumatic lumbar hernia with ureteropelvic junction disruption: case report and review of the literature. *J Trauma* 2003;55(5):985-8.
- Ipek T, Eyuboglu E, Aydingoz O. Laparoscopic management of inferior lumbar hernia (Petit triangle hernia). *Hernia* 2005;9(2):184-7.
- Henry LR, Rizzo A, Gunther W, McCoy K, Wang D, Jordan M. Meningitis complicating traumatic lumbar herniation. *J Trauma* 2006;60(6):1342-3.
- Madan AK, Ternovits CA, Speck KE, Pritchard FE, Tichansky DS. Laparoscopic lumbar hernia repair. *Am Surg* 2006;72(4):318-21.
- Di Carlo I, Toro A, Sparatore F, Corsale G. Lumbar hernia repaired using a new technique. *Am Surg* 2007;73(1):54-7.
- Iannitti DA, Biffi WL. Laparoscopic repair of traumatic lumbar hernia. *Hernia* 2007;11(6): 537-40.
- Torer N, Yildirim S, Tarim A, Colakoglu T, Moray G. Traumatic lumbar hernia: report of a case. *Int J Surg* 2008;6(6):e57-9.
- Uzun MA, Köksal N, Onur E, Günerhan Y, Şahin ÜY, Çelik A. [Traumatic lumbar hernia]. *Ulus Trauma Acil Cerrahi Derg* 2008;14(3): 253-5.
- Alaedein D. Laparoscopic trans-abdominal preperitoneal repair of a traumatic Petit lumbar hernia with mesh. *Am Surg* 2011;77(12): E292-3.
- Links DJ, Berney CR. Traumatic lumbar hernia repair: a laparoscopic technique for mesh fixation with an iliac crest suture anchor. *Hernia* 2011;15(6):691-3.
- Kim J, Oh MM, Kim JJ, Moon du G. Delayed repair of a traumatic lumbar hernia with renal rupture. *Am Surg* 2012;78(5): E295-6.
- Killeen KL, Girard S, DeMeo JH, Shanmuganathan K, Mirvis SE. Using CT to diagnose traumatic lumbar hernia. *AJR Am J Roentgenol* 2000;174(5):1413-5.
- Esposito TJ, Fedorak I. Traumatic lumbar hernia: case report and literature review. *J Trauma* 1994;37(1):123-6.
- Yee JA, Harold KL, Cobb WS, Carbonell AM. Bone anchor mesh fixation for complex laparoscopic ventral hernia repair. *Surg Innov* 2008;15(4):292-6.