

Intramuscular Lipoma Occurring Within the Pectoralis Major Muscle: Case Report

Pektoralis Major Kasından Gelişen İntramusküler Lipom

Dursun Özgür KARAKAŞ,^a
Özgür DANDİN,^b
Ahmet Ziya BALTA,^c
Batuhan HAZER,^a
Tuncer ERGİN^d

^aClinic of General Surgery,
Kasımpaşa Military Hospital,
İstanbul
Clinics of

^bGeneral Surgery,

^dRadiology,
Bursa Military Hospital, Bursa

^cClinic of General Surgery,
GATA Haydarpaşa Training Hospital,
İstanbul

Geliş Tarihi/Received: 03.10.2013

Kabul Tarihi/Accepted: 31.08.2014

Yazışma Adresi/Correspondence:

Dursun Özgür KARAKAŞ
Kasımpaşa Military Hospital,
Clinic of General Surgery, İstanbul,
TÜRKİYE/TURKEY
drdok1978@hotmail.com

ABSTRACT Lipomas are benign mesenchymal neoplasms that develop from adipose tissue and one of the most common soft tissue neoplasms. They may occur subcutaneously in the extremities and body. Also they occur intramuscular or intermuscular in large muscles. Intramuscular lipomas are rare and they were reported frequently in the extremities and body, or rarely in the head and neck region, but occurring in pectoralis major muscle is very rare. We presented thirty years old woman presenting with intramuscular lipoma occurring in pectoralis major muscle. Physicians must be kept in mind lipomas when evaluating breast mass. Intramuscular lipomas may be confused with breast malignancies or liposarcomas. Computerized Tomography and Magnetic Resonance Imaging are important imaging for differentiation from breast malignancies and liposarcomas.

Key Words: Lipoma; pectoralis muscles

ÖZET Lipomalar adipöz dokudan gelişen ve en sık yumuşak doku tümörlerinden biri olan benign mezenkimal tümördür. Lipomalar ekstremiteler ve gövdede subkutan olarak ya da büyük kaslarda intramusküler ya da intermusküler gibi derin yumuşak dokuda oluşabilir. İntramusküler lipomalar oldukça nadir olup, sıklıkla ekstremiteler, gövde ve nadiren baş ve boyun bölgesinde bildirilirken, pektoralis major kasından gelişen intramusküler lipom çok daha nadir olarak bildirilmiştir. Burada pektoralis major kasından gelişen intramusküler lipom ile başvuran otuz yaşında kadın hastayı sunmaktayız. Doktorlar üst diş kadran meme kitlelerini değerlendirirken lipomaları akılda tutmalıdır. İntramusküler lipomalar meme maligniteleri veya liposarkomalar ile karışabilmektedir. Bilgisayarlı Tomografi ve Manyetik Rezonans Görüntüleme, maligniteler ve liposarkomlardan ayırmada önemli görüntüleme yöntemleridir.

Anahtar Kelimeler: Lipom; pektoralis kasları

Türkiye Klinikleri J Case Rep 2015;23(3):329-31

Lipomas are benign mesenchymal neoplasms consisting of adipocytes and one of the most common encountered soft tissue neoplasms. Although lipomas may occur anywhere of body, frequently they develop subcutaneously at extremities and body or in deep soft tissue as intramuscular or intermuscular in the large muscles. Intramuscular lipomas are rare and they were reported especially in the extremities and body, or rarely in the head and neck region. However occurring lipomas in a pectoralis major muscle is very rare.¹⁻³ Here we presented thirty years old woman presenting with intramuscular lipoma occurring within pectoralis major muscle.

doi: 10.5336/caserep.2013-37791

Copyright © 2015 by Türkiye Klinikleri

CASE REPORT

A thirty-year-old woman admitted to our surgical unit with a chief complaint of a palpable mass in the upper outer quadrant of her left breast over a 6 months period. She was premenopausal and had no family history of cancer, history of trauma or previous surgery. Her physical examination revealed a well-circumscribed, partially mobile 4-cm palpable mass in the upper outer quadrant of the left breast and no axillary lymph nodes were palpable. The ultrasonographic examination demonstrated a 5 cm in size, unencapsulated, mobile mass in of the pectoralis major muscle (Figure 1A). Homogenously hyperintens lesion in front of the pectoralis major muscle was seen at T1 weighted images of magnetic resonance imaging (MRI) (Figure 1B). Complete surgical excision was performed after necessary preparations for the operation and obtaining informed consent form from the patient. A 5x4,2 cm in size well circumscribed, round to oval, multi-lobular, yellowish gray mass was seen in macroscopic examination. In histological examination, it was seen that the lesion comprises mature adipocytes compatible with lipoma. No cellular aplasia, mitosis or any malignant change was observed (Figure 2). Her postoperative recovery was uneventful. Her follow up evaluation was normal at six months from surgery.

DISCUSSION

Lipomas are benign mesenchymal neoplasms consisting of adipocytes and one of the most common

soft tissue neoplasms. Most authors indicated that proliferation of adipose tissue is developed by microtrauma that cause to rupture of fibrous septa and connection between the skin and deep fascia. Endocrine, dysmetabolic and genetic factors stimulates the uncontrolled growth of adipose tissue is the other theory.⁴

Intramuscular lipomas are very rare and 0-5% of benign lipomatous tumours. Generally, they present as a painless, slow-growing mass. Lipomas, as like as intramuscular lipomas are commonly occurred in between 30 and 60 ages. However a 70 years old patient with intramuscular lipoma was reported.¹⁻³ As consistent with the current literature, our case was thirty years old.

Intramuscular lipomas are found most commonly in the lower extremity, trunk, shoulder girdle and upper extremity, respectively. Intramuscular lipomas may be divided into well-circumscribed and infiltrative types. The infiltrative type typically invades the muscle fibers, eventually replacing them and represents 83% of the lipomas. The well-circumscribed type presents with a distinct boundary and it is clearly distinguished from adjacent muscle cells contrarily.⁵

Intramuscular lipoma can be seen a partially margined density with calcification at mammography and anterior displacement of the muscle is a clue for intramuscular lipomas. Lipomas can be seen well-defined encapsulated, homogenously echogenic, intramuscular masses on USG. Infre-

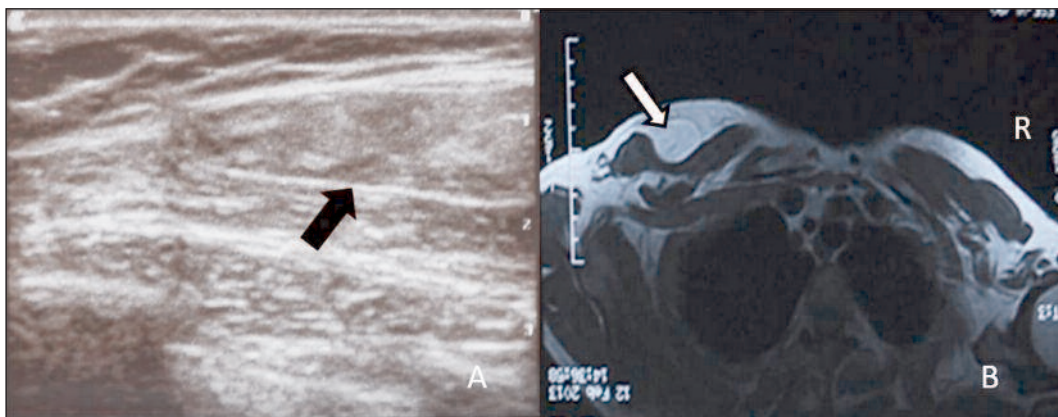


FIGURE 1: A) Ultrasonographic images of the lipoma occurring within pectoralis major muscle. **B)** Magnetic resonance imaging of homogenously hyperintens lesion in front of the pectoralis major muscle.

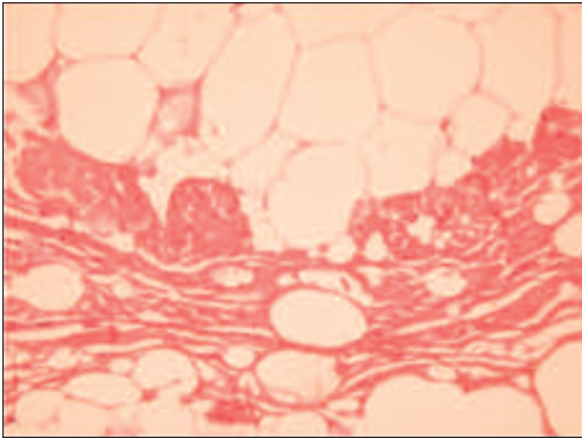


FIGURE 2: x100 microscopic magnification of hematoxylin-eosin stained mature adipocytes within muscle cells.

quently lipomas diffusely infiltrate the muscle. CT and MRI can identify accurately intramuscular lipomas. Lipomas can be seen as homogeneously hypodense on CT and hyperintense in T1 and T2 weighted images, and hypointense in fat-suppressed T1 weighted sequences on MRI.^{2,6} In our case encapsulated, mobile solid mass which is between muscle fascia and anterior side of pectoralis major muscle was seen on USG. Also this lesion was showing similarities with subcutaneous adipose tissue. Homogeneously hyperintense lesion in front of the pectoralis major muscle was seen at T1 weighted images of MRI.

Subcutaneous lipomas are the most frequent type of lipomas and generally no imaging require. Deep lipomas such as intramuscular lipomas requires imaging for differentiation of malignant tumor, such as a liposarcoma. Despite of liposarcomas are common in men with 56 years average,

lipomas are common in women with 67 years average. CT and MRI are important imaging for differentiation of liposarcomas from lipomas. Larger than 10 cm, presence of thick septa, presence of globular and/or nodular nonadipose areas or masses, and lesion less than 75% fat are the significant features for imaging liposarcomas.⁶ Despite of immature fat cell or lipoblast is the hallmark of liposarcoma and lipoblasts have an eccentric, hyperchromatic nucleus, which is indented or scalloped by the presence of one or more fat vacuole, but mature adipocyte was seen in lipomas.^{2,7} In our case a well circumscribed, round to oval multi-lobular, yellowish gray mass was seen at macroscopic examination. Mature adipocytes compatible with lipoma, absence of malignancy or atypic metaplasia was reported at microscopic examination.

The treatment of intramuscular lipomas are complete surgical excision. Recurrence of intramuscular lipoma depends on the sufficiency of excision and recurrence rate was reported as 62.5%.¹ In our case; lipoma was completely excised and there is no evidence of recurrence after 6 months of following.

In conclusion; physicians must be kept in mind lipomas (intramuscular or intermuscular occurring within pectoralis major muscle) when evaluating the upper outer quadrant breast mass. Intramuscular lipomas occurring within pectoralis major muscle are very rare, and may be confused with breast malignancies or liposarcomas. CT and MRI are important imaging for differentiation from breast malignancies and liposarcomas.

REFERENCES

- Gopal U, Patel MH, Wadhwa MK. Intramuscular lipoma of the pectoralis major muscle. *J Postgrad Med* 2002;48(4):330-1.
- Pant R, Poh AC, Hwang SG. An unusual case of an intramuscular lipoma of the pectoralis major muscle simulating a malignant breast mass. *Ann Acad Med Singapore* 2005;34(3): 275-6.
- D'Alfonso TM, Shin SJ. Intramuscular lipoma arising within the pectoralis major muscle presenting as a radiographically detected breast mass. *Arch Pathol Lab Med* 2011;135(8):1061-3.
- Lahrach K, el Kadi KI, Mezzani A, Marzouki A, Boutayeb F. An unusual case of an intramuscular lipoma of the biceps brachii. *Pan Afr Med J* 2013;15:40. doi: 10.11604/pamj.2013.15.40.2654
- Lee JH, Do HD, Lee JC. Well-circumscribed type of intramuscular lipoma in the chest wall. *J Cardiothorac Surg* 2013;8:181. doi: 10.1186/1749-8090-8-181.
- Kransdorf MJ, Bancroft LW, Peterson JJ, Murrey MD, Foster WC, Temple HT. Imaging of fatty tumors: distinction of lipoma and well-differentiated liposarcoma. *Radiology* 2002; 224(1):99-104.
- Weiss SW. Lipomatous tumors. *Monogr Pathol* 1996;38:207-39.