

Chest Physiotherapy in a Neonatal Infant After Congenital Diaphragmatic Hernia Surgery

Konjenital Diyafragmatik Herni Cerrahisi Sonrası Yenidoğanda Göğüs Fizyoterapisi

^{ID} Hatice ADIGÜZEL^a, ^{ID} Mehmet EĞİLMEZ^a, ^{ID} Ünal SARIKABADAYI^b, ^{ID} Bülent ELBASAN^c,
^{ID} Arzu DEMİRGÜÇ^a, ^{ID} Nevin ERGUN^a

^aDepartment of Physiotherapy and Rehabilitation, SANKO University Faculty of Health Sciences, Gaziantep, TURKEY

^bDepartment of Pediatrics, SANKO University Faculty of Medicine, Gaziantep, TURKEY

^cDepartment of Physiotherapy and Rehabilitation, Gazi University Faculty of Health Sciences, Ankara, TURKEY

ABSTRACT Congenital diaphragmatic hernia (CDH) is a rare congenital anomaly. It is characterized by the structural defect of the diaphragm in the intrauterine period. A male neonate with diagnosis of CDH was hospitalized after vaginal delivery at 39 weeks' gestation. The case was resuscitated and referred to our Neonatal Intensive Care Unit (NICU) on the second day, diagnosed with Bochdalek hernia and underwent surgery. Chest physiotherapy (CP) was started on postoperative 24th day. CP was applied for a total of 24 sessions, twice a day, four days/week, for three weeks, each 30-40 minutes. CP was started with bilateral vibration to the upper apical lobes in modified drainage positions and passive mobilization of the upper limb. CP, performed by positioning the lung lobes in need, consisted of vibration and gentle percussion for 3-5 minutes with distal finger phalanges. Due to the chest X-ray findings, the posterior or lower basal lobes were studied more intensively. Aspiration was performed after physiotherapy in each session. The sessions were ended by placing the patient in side-lying position or a prone position to increase oxygenation. The patient's vital signs, the type and color of secretion, chest radiography, respiratory sounds, nutritional type, and respiratory pattern were evaluated before, during, and after CP. No complications were observed during CP. It was observed that secretion excretion improved, weaning from the mechanical ventilator accelerated, drainage in the chest tube got easier, oral feeding increased, and vital signs didn't change. Respiratory sounds and chest X-rays showed that the infiltration and atelectasis areas decreased towards the discharge process.

ÖZET Konjenital diyafragmatik herni (KDH) nadir görülen bir konjenital anomali. KDH intrauterin dönemde diyafragmanın yapısal defekti ile karakterizedir. KDH tanısı alan erkek olgu, gebeliğin 39. haftasında vaginal yoldan doğurtulduktan sonra hastaneye yatırıldı. Dış serviste doğum sonrasında resusitasyon yapılarak, hastanemiz yenidoğan yoğun bakım ünitesi'ne (YYBÜ) sevk edilen hasta 2. gün Bochdalek herni tanısı alarak cerrahiye alınmıştır. Post operatif 24. günde başlanarak üç hafta boyunca günde iki defa 30-40 dk, toplam 12 gün/24 seans, haftada dört gün göğüs fizyoterapisi (GF) uygulanmıştır. GF'ne modifiye drenaj pozisyonlarında üst apikal loblara proprioseptif stimülasyonlarla bilateral vibrasyon ve üst ekstremitenin pasif mobilizasyonu ile başlandı. Akciğer loblarına göre pozisyonlamayla yapılan GF'si, distal parmak falanksı ile 3-5 dakika boyunca vibrasyon ve nazik perküsyondan oluştu. Akciğer röntgen sonucuna göre arka veya alt bazal loblara yoğunlaşıldı. Her GF seans sonrasında aspirasyon yapıldı. Seanslar, hastanın yan yatış pozisyonuna veya oksijenlenmeyi arttırmak için yüzüstü pozisyona getirilmesiyle sonlandırıldı. Hastanın vital bulguları, sekresyonun tipi ve rengi, akciğer grafisi, solunum sesleri, nutrisyon şekli ve solunum tipi GF öncesi, esnası ve sonrasında değerlendirilmiştir. GF sırasında hastanın hiçbir komplikasyon gelişmedi. Sekresyon atılımının kolaylaştığı, mekanik ventilatörden ayrılma sürecinin hızlandığı, göğüs tüpünde drenajın kolaylaştığı, oral beslenmesinin arttığı ve vital bulgularında ani değişimlerin olmadığı gözlenmiştir. Solunum sesleri ve akciğer filmleri değerlendirildiğinde olgunun taburculuk sürecine doğru infiltrasyon ve atelektazik alanlarının azaldığı gözlenmiştir.

Keywords: Congenital diaphragmatic hernia; chest physiotherapy; Bochdalek

Anahtar Kelimeler: Konjenital diyafragma hernisi; göğüs fizyoterapisi; Bochdalek

Diaphragmatic hernia is the shifting of the abdominal organs on one or both sides from the weak points on the diaphragm into the chest cavity.¹ Con-

genital diaphragmatic hernia (CDH) is a rare congenital anomaly with high mortality and morbidity rates with an incidence of 1/2,200.^{2,3} In Bochdalek

Correspondence: Hatice ADIGÜZEL

Sanko University Faculty of Health Sciences, Department of Physiotherapy and Rehabilitation, Gaziantep, TURKEY/TÜRKİYE

E-mail: fzthatis@gmail.com



Peer review under responsibility of Türkiye Klinikleri Journal of Health Sciences.

Received: 14 Feb 2020

Received in revised form: 20 Mar 2020

Accepted: 17 Apr 2020

Available online: 24 Apr 2020

2536-4391 / Copyright © 2021 by Türkiye Klinikleri. This is an open access article under the CC BY-NC-ND license (<http://creativecommons.org/licenses/by-nc-nd/4.0/>).

hernia, which constitutes more than 95% of CDHs, a posterolateral hernia, where different abdominal organs are displaced towards the thoracic cavity and pulmonary hypoplasia, is observed. The most important factors of early survival in CDH are pulmonary hypoplasia and pulmonary hypertension.³⁻⁶ Structural anomalies can be seen not only on the lesion side but also on the opposite side lung.

Symptoms of respiratory difficulties are frequently encountered in newborns with CDH. In some cases, mechanical ventilation support is required.⁷⁻⁹ Physiotherapists working in the neonatal intensive care unit (NICU) provide holistic and consultative neuroprotective treatment to newborns with premature or medical complications, and also perform chest physiotherapy (CP).¹⁰

According to the common definition of the American Respiratory Diseases and European Respiratory Society, CP is a symptomatic and evidence-based intervention in chronic respiratory diseases with reduced daily living activities. When individualized treatment is applied according to the patient, it decreases the symptoms, increases the participation with functional status, stabilizes the systemic effects of the disease, and reduces health expenditures.¹¹⁻¹³ The purpose of CP in neonatal infants connected to a mechanical ventilator (MV) is to provide removal of tracheobronchial secretions, prevent airway obstruction, reduce airway resistance, increase gas exchange and reduce respiratory workload.¹³ In CDH, CP may be required when there is secretion retention.¹⁴ Individuals with CDH may also require treatment for chronic lung disease, bronchospasm, pulmonary hypertension, aspiration, pneumonia, and pulmonary hypoplasia.¹⁵ There is no clear data in the literature about the effectiveness of CP in neonates with CDH, its effects on hemodynamic parameters, complications that may occur after CP, and its routine use. For this reason, information about the CP process and physiotherapy responses of a neonate with CDH followed in the NICU is presented in this case report.

CASE REPORT

A male newborn, who was born 39 weeks' gestation via a spontaneous vaginal delivery to a 25-year-old

primipara, was intubated due to respiratory distress and hospitalized in the NICU in an outpatient hospital. The patient was diagnosed with diaphragmatic hernia by lung X-ray and referred to our hospital on the second postnatal day. The patient was followed up with a mechanical ventilator (MV) in the synchronized intermittent mechanical ventilation (SIMV) mode. In the first physical examination, he was diagnosed with tachypnea, intercostal retraction, and a decrease in the left side breathing sounds. Bochdalek hernia was seen on anterior-posterior (AP) chest radiography. Preoperative echocardiography showed that patent ductus arteriosus (PDA) and pulmonary hypertension developed, heart was pushed to the right, PDA was 3 mm, atrial septal defect (ASD) was 4 mm, right structures were wide, and ejection fraction (EF) was found to be 65%. No pathology was detected in the preoperative abdominal and transfontanelle ultrasonography. The patient underwent surgery on the 2nd day of hospitalization. The hernia was approximately 10x10 cm in size and only the intestine was herniated. The patient underwent full surgical correction, and a chest tube was inserted, and then the neonate was continued to be followed in the NICU. The patient was sedated during MV. Also, medical treatment continued.

As of the day of hospitalization, the case was followed up with a Dräger Babylog[®] VN500 MV in the SIMV mode. The chest tube was removed on the 8th post-op day. On the post-op 17th day, marked pleural fluid was detected on the PA radiography and ultrasonography of the patient, whose respiratory distress increased, and chest tube was re-inserted. The patient, who could not be extubated, was included in the CP program after his general condition stabilized on the post-op 24th day. The reason why the patient could not be extubated was thought to be atelectasis in the lower lobes due to respiratory distress and pleural effusion. In our NICU, CDH cases are observed with a frequency of 5-10 cases per year. About half of these cases result in death before or after surgery. In patients who survive, CP is used when necessary. The case was included in the CP program due to the prolonged intubation, acute respiratory distress, accompanying atelectasis in the lower lobes due to pleural effusion, and difficulty in

excretion of secretion. Family signed an informed written consent before starting CP. It was aimed to remove secretions and to increase the ventilation of the lung lobes and pleural fluid drainage in the CP program. CP was started with bilateral vibration to the upper apical lobes in modified drainage positions. It then continued with passive mobilization of the upper limb. Vibration and gentle percussion were applied to each side for 3-5 minutes with segments of the right and left basal lung lobes, posterior upper and lower lobes, with one hand or a ventilator mask without head elevation, and in lying position on either side. Bilateral gentle percussion and vibration were performed with distal finger phalanges. CP to the relevant lobes was first started with proprioceptive stimulation of chest wall. Each CP session was 30-40 minutes. The duration of CP applications was made in accordance with the nutrition and care hours, and CP applications took 25-30 minutes in NICU. However, the time spent with the preparation of the physiotherapist, observing physical evaluation, vital signs, secretion and respiratory parameters of the neonate were observed before and after 5 minutes, the time spent together was 30-40 minutes in total. The total time including the manual active techniques of CP, postural drainage techniques and ventilation positioning applied by the physiotherapist to the baby was 30 minutes on average. This period included resting the baby from time to time and observing the hemodynamic responses of the physiotherapist before and after the session. Also according to the results of lung X-ray in CP sessions, the posterior and/or lower basal lobes were studied more intensively. So percussion and vibrations are applied over the specific segments being treated during tidal breathing or expiration period of the case. The range of the frequency of percussion was 4.6-5.0 Hz (claps per second). Because the oscillation of airflow of percussion is within the physiological range to assist with secretion clearance the physiotherapist aimed to percuss using these frequencies towards the upper end of this range. When the percussion seemed uncomfortable and painful for the case, it was terminated. Painful signs were observed by facial expressions. Chest wall vibrations were involved the application of fine oscillatory movements combined with chest wall compression,

initiated at the end of inspiration and applied throughout expiration. Vibrations were applied by the physiotherapist's hands and distal finger phalanges according to the lobe. Vibrations were in a sufficient intensity to compress the rib cage and increase expiratory flow, while being comfortable for the case. Both the compressive and oscillatory forces applied during vibration are transmitted through the lung to the airways. CP was applied for a total of 24 sessions (12 days/twice a day), four days/week for three weeks. Aspiration was performed after each session. After aspiration, the type and color of the secretion was noted by the physiotherapist. The sessions were ended by placing the patient in side-lying position or a prone position to increase oxygenation. Physiotherapy was terminated in case of any signs of intolerance (such as oxygen saturation/SPO₂)<80-85%, heart rate (HR)>200 beats/min (bpm) or<100 beats/min) lasting longer than 4 seconds. Routine daily aspirations were performed according to the needs of the case. Respiratory pattern, vital signs [HR, (blood pressure (BP)], SPO₂ by pulse oximeter, ventilator mode and parameters, secretion characteristics (type, density, color) were recorded before and 5 minutes after CP. In addition, chest X-ray, daily respiratory sounds, and nutritional type and amounts were noted before, after, and during the CP program. The patient's transition from the SIMV mode MV to nasal continuous positive airway pressure (nCPAP) occurred on post-op 35th day. On the post-op 37th day, incubator oxygen support was started. Oxygen therapy was stopped on the post-op 40th day.

Pre-CP chest X-ray showed a lack of ventilation, bilateral ground glass appearance, and possibility of edema on the left side of the lungs. On the AP chest X-ray on the 5th day of CP, infiltration was considered in the bilateral basal lobes. On the AP chest X-ray on the 7th day of CP, lack of ventilation in the bilateral lung lobes and infiltration in the right upper and lower lobes were considered. On the AP chest X-ray on the 14th day of CP, it was observed that ventilation was increased and infiltrations decreased in both lobes of the lungs. On the AP chest X-ray on the 21st day of SP, the patient was extubated after observing that the ventilation and infiltrations were significantly improved in both lungs (Figure 1).

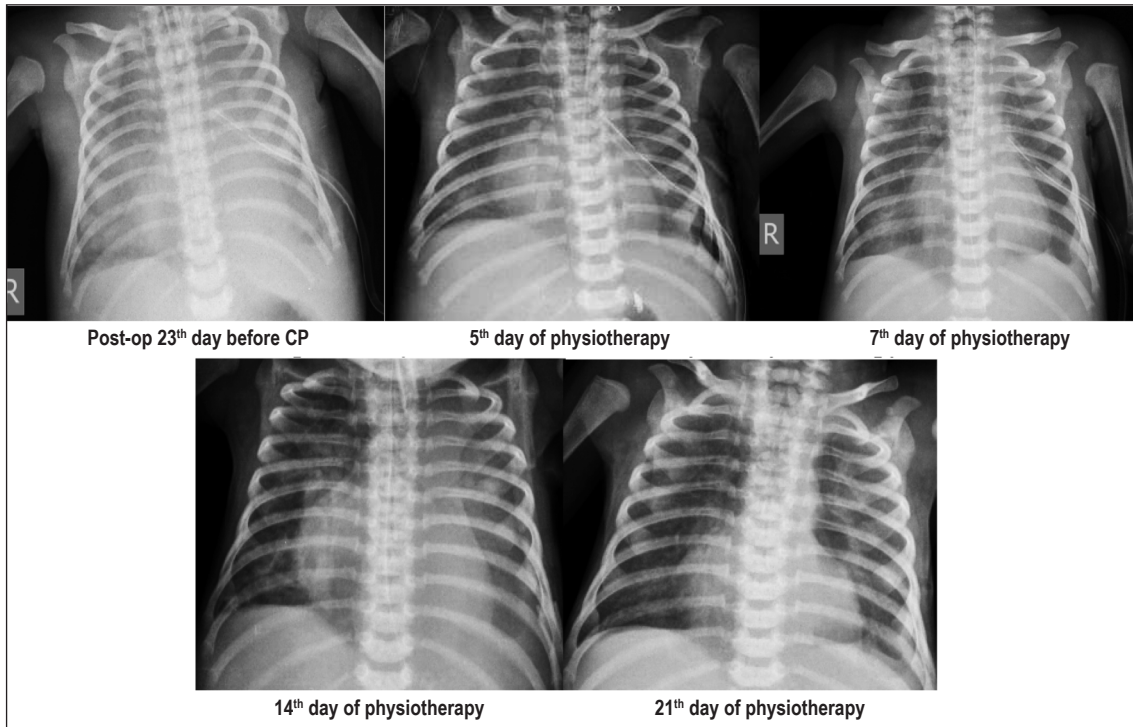


FIGURE 1: AP chest X-rays before and after chest physiotherapy (CP).

On the first day of CP, bilateral rales were heard more on the left side. In physiotherapy follow-up, it was observed that the respiratory sounds and rales in both lungs gradually improved in the follow-up.

BP averages, pulse, and SPO_2 values before and after 5 minutes were recorded. It was observed that after each CP session, BP, pulse, and SPO_2 increased at similar rates compared to pre-CP values. Also there was a similar increase in HR values compared to pre-CP values. Towards the last half of the CP period, there was a decrease in HR values. (Table 1, Table 2).

In the first days of the sessions, while the secretions were dark and nutrient-containing, or dark white and sticky, it was observed that they became more transparent towards the last sessions, its amount decreased, and it was less sticky.

Considering the respiratory type assessment, basal right hemithorax and mixed type respiration pattern in left hemithorax were recorded. Although asymmetry persists during the sessions, it was noted that the diaphragmatic and mixed type respiratory pattern is increasing bilaterally. In the last session,

mixed type respiratory pattern was observed, with excessive bilateral diaphragmatic respiration.

During CP sessions, only a small amount of dark vomiting and brown aspiration secretion were observed for one day. No complications were observed during the CP sessions. The absence of sudden changes in the vital signs of the patient during CP and increased fluid drainage from the chest tube suggested that CP was well tolerated by the patient.

DISCUSSION

This is the first study to show the effects of CP with CDH in a newborn. In the patient who was diagnosed with CDH and had difficulty weaning from MV, it was seen that the use of CP sessions accelerated weaning from MV, and CP techniques were found to be safe. After the CP sessions, oxygen saturation levels and bilateral lung ventilation increased, infiltration areas decreased, pleural fluid drainage and secretion excretion was facilitated, and improvements were observed in the quality of respiratory sounds. It was observed that the respiratory pattern became more

TABLE 1: BP, HR, and SPO₂ values before/after CP.

	1. day	2. day	3. day	4. day	5. day	6. day	7. day	8. day	9. day	10. day	11. day (NCPAP)	12. day (incubator O ₂)
	BP/AP	BP/AP	BP/AP	BP/AP	BP/AP	BP/AP	BP/AP	BP/AP	BP/AP	BP/AP	BP/AP	BP/AP
SPO ₂ (M)	96/99	96/100	96/99	98/100	100/98	98/99	94/99	98/98	97/95	100/100	93/95	97/91
SPO ₂ (A)	96/99	95/100	100/100	98/100	96/100	94/97	94/100	91/99	95/96	100/100	94/96	97/100
HR (M)	130/140	131/143	136/143	139/144	121/145	120/140	129/145	138/132	140/162	120/125	150/156	108/115
HR (A)	130/140	130/143	148/173	138/145	130/145	132/140	133/145	152/155	138/138	120/125	138/132	110/115
BP (mean) (M)	56/56	56/58	62/62	61/63	52/55	68/58	87/87	83/87	73/71	68/79	66/69	58/64
BP (mean) (A)	56/56	58/58	62/62	58/60	62/64	58/60	86/86	100/91	82/78	68/70	64/60	58/64

HR: Heart rate, SPO₂: Oxygen saturation, CP: Chest Physiotherapy, BP: Blood pressure, M: Morning, A: Afternoon, BP: Before physiotherapy, AP: After physiotherapy.

symmetrical over time with an increase in bilateral lung ventilation. In addition, it was determined that the patient who had only respiratory pattern of chest, changed to abdominal and chest respiratory pattern, too.

CDH patients should be followed up by a multidisciplinary team for a long term.^{16,17} It is targeted to accelerate secretion and to improve the ventilation with the increase of oxygenation with CP sessions in CDH. In this case, which received MV support for a long time, it was aimed to reduce the risk of lung collapse and atelectasis caused by increased secretion with CP and to mobilize secretions from the airway. Respiratory distress can occur due to sepsis, aspiration, pleural effusion, pneumothorax, atelectasis, and reherniation. Clinical signs for respiratory distress can be tachypnea, expiratory grunt, flaring nose, chest retraction, and cyanosis. The radiological diagnosis is based on diffuse reticulogranular infiltrate (ground glass appearance), homogenously distributed in the lungs, and the presence of air bronchogram.¹⁸ After insertion of the chest tube after pleural effusion, atelectasis, tachypnea, chest retraction symptoms, and respiratory distress symptoms were observed in our case. It is important to start CP sessions at the earliest period in infants who develop respiratory distress for any reason. CP also prevents respiratory complications and supports the process of weaning and oxygen therapy.¹⁴ In the study of Abreu et al., it was found that CP performed in patients with acute respiratory distress symptoms had a positive effects on hemodynamic instability in newborns with acute respiratory distress symptoms.¹⁸ In our study, CP had no positive effect on hemodynamic responses. But there was a decrease in HR values compared to pre-CP values towards the last half of the CP period.

Atelectasis of the lung is a rare cause of significant respiratory distress and hypoxemia in neonates. Preterm neonates are at a greater risk due to diffuse microatelectasis with impaired gas exchange, but massive focal collapse is a rare condition. Excessive or thick pulmonary secretions obstructing the small airways are a common problem in neonates. Pulmonary collapse may occur secondary to mucus plug.¹⁹ In our case, a thick mucus plug was observed with atelectasis and respiratory distress symptoms. CP has been used in neonates to clear secretions, reduce atelectasis after extubation, reduce reintubation, and also to assist lung ventilation in newborns with respiratory problems. It is known in the literature that neonates are at a greater risk of diffuse gas exchange and widespread microatelectasis.¹⁹ There is insufficient evidence to determine whether active CP is beneficial in neonates receiving MV treatment.²⁰ This study contributed to the literature in this field that CP applied in MV-related neonates had a positive effect on the extubation process. In the literature, there is insufficient

TABLE 2: BP, HR, and SPO₂ mean values before/after CP.

	Before CP (Mean ±SD)	After CP (Mean ±SD)
BP (mmHg)	66.41±12.70	67.58±11.68
HR (bpm)	130.83±12.10	141.45±13.34
SPO ₂ (mmHg)	96.54±2.35	97.79±2.65

BP: Blood pressure, HR: Heart rate, SPO₂: Oxygen saturation, bpm: beats per minute
CP: Chest Physiotherapy, Mean ± SD: mean ± standard deviation.

evidence for the benefits of active CP in neonatal infants in the MV.²¹ In this neonate, physiotherapy sessions were shown to have positive effects on secretion excretion, pleural fluid drainage, and ventilation support. In addition, it was observed that the secretion quality (color, type, amount) changed over time and bilateral lung ventilation increased by facilitating the removal of thick and dark secretions caused by infection.²⁰

CP approaches in newborns are divided into non-mobility and mobility approaches. Non-mobility approaches include CP, therapeutic handlings, various positioning, massage, and stretching techniques. Mobility approaches consist of mobilization in-bed, range of motion exercises, muscular strengthening, transfer and walking activities. Intra-bed mobilization, passive upper limb movements, and proprioceptive neuromuscular techniques enabled the progression of secretions using proprioceptive stretches. Then, vibration, percussion, and modified postural drainage positioning were applied to each lobe deemed appropriate for the patient's need. In a study using postural drainage and chest percussions in infants with respiratory distress syndrome, these two interventions were shown to significantly increase SPO₂.²¹ In our patient, an increase in SPO₂ values was observed at the end of the physiotherapy sessions. It is recommended that newborns with moderate respiratory distress syndrome be positioned as prone as possible. Ventilation develops due to the increase of oxygenation in the prone position. In our patient, the prone position and side-lying position were frequently preferred for ventilation. It was observed that this position positively affects the infiltration areas and contributes to increasing the amount

of chest and abdominal respiratory pattern by removing secretion. Flenady et al. reported that active CP programme of pre- post extubation CP may result in lower incidence of lobar collapse and reintubation within 24 hours.²²

In previous studies, it was stated that percussion and vibration made by positioning in CP, the secretions move from small airways to large airways, and then it got easier to remove by aspiration. It was also reported that the patient's sidelying on both sides allowed the lungs to expand sufficiently, enhancing secretion drainage and oxygenation. Studies have shown that physiological changes such as an increase in SPO₂ after positioning are due to improved ventilation/perfusion (V/P) ratio and delayed airway closure. In intubated newborns, there was a significant improvement in SaO₂/FiO₂, and SPO₂ rates with CP.^{23,24} In our study, it was observed that secretion excretion was facilitated, ventilation of the lungs was improved, and the breathing pattern was improved with postural drainage, positioning, percussion, and vibration techniques.

In another similar study examining the effect of secretions in newborns, it was reported that increased secretions clinically result in atelectasis and hypercapnia caused by pneumonia, meconium aspiration, and bronchopulmonary dysplasia.²²⁻²⁵ In our patient, it was observed that the secretions were dark in the first few days until the fluid drainage in the left lung was achieved, and then it got lighter and less dense. As the sessions progressed, the secretions were observed to be less dense and sticky, and lighter. This result also suggested that there was a decrease in the severity of infection and caused positive changes in bilateral lung ventilation.

Pleural effusion can be seen in neonates as inflammatory diseases, cardiac causes, and lymphatic system and lung malformations. In addition, they can be seen with genetic syndromes secondary to hydrops fetalis or as an isolated primary pleural effusion.²⁶ In most cases, as in our case, the effusion is seen 60% unilateral and on the right/left hemithorax. Pleural effusion, which causes pulmonary hypoplasia, is also a risk factor for postpartum respiratory failure.²⁷ Anomalies such as underlying congenital

cystic adenomatoid malformation, bronchopulmonary dysplasia, diaphragm hernia, chest wall hamartoma, and pulmonary vein atresia are often found in patients with serous feature pleural effusion.^{28,29} In our case, pleural effusion was observed due to CDH. Prenatal treatment methods of pleural effusion are excretory and thoracoamniotic shunt operations. These interventions aim to facilitate the expansion of the lungs by eliminating the pressure effect of the pleural fluid, eliminate the possibility of pulmonary hypoplasia, as well as reduce the pressure on the venous system and increase the risk of heart failure by increasing venous return.²⁷ In our study, along with the insertion of a chest tube for pleural fluid drainage of the patient with CDH, drainage was facilitated by CP methods, and thereby ventilation increased in the lung lobes.

There is no study in the literature regarding CP approaches applied in patients with CDH. Therefore, we think that the CP results applied in this patient may contribute to the literature. The absence of any complications in the vital signs of the patient during CP made the sessions easier. Increased chest tube drainage and decreased infiltration area in the lungs are considered as a positive response to physiotherapy. Further studies with randomized controlled, long-term follow-ups are needed to determine the effects of these results in all infants with CDH.

Acknowledgement

We would like to thank Osman Topac for language review.

Source of Finance

During this study, no financial or spiritual support was received neither from any pharmaceutical company that has a direct connection with the research subject, nor from a company that provides or produces medical instruments and materials which may negatively affect the evaluation process of this study.

Conflict of Interest

No conflicts of interest between the authors and / or family members of the scientific and medical committee members or members of the potential conflicts of interest, counseling, expertise, working conditions, share holding and similar situations in any firm.

Authorship Contributions

Idea/Concept: Hatice Adıgüzel, Mehmet Eğilmez; **Design:** Hatice Adıgüzel, Mehmet Eğilmez, Arzu Demirgüç; **Control/Supervision:** Ünal Sarıkabadayı, Mehmet Eğilmez, Hatice Adıgüzel; **Data Collection and/or Processing:** Hatice Adıgüzel, Mehmet Eğilmez, Ünal Sarıkabadayı; **Analysis and/or Interpretation:** Hatice Adıgüzel, Arzu Demirgüç, Ünal Sarıkabadayı, Nevin Ergun, Bülent Elbasan; **Literature Review:** Hatice Adıgüzel, Mehmet Eğilmez, Bülent Elbasan; **Writing the Article:** Hatice Adıgüzel, Arzu Demirgüç, Ünal Sarıkabadayı, Nevin Ergun, Bülent Elbasan; **Critical Review:** Hatice Adıgüzel, Arzu Demirgüç, Bülent Elbasan, Nevin Ergun; **References and Fundings:** Mehmet Eğilmez, Ünal Sarıkabadayı; **Materials:** Hatice Adıgüzel, Mehmet Eğilmez, Ünal Sarıkabadayı.

REFERENCES

- Erikçi V, Karaman N, Arikan A. [Congenital Diaphragmatic Hernia]. SSK Tepecik Eğitim Hast Derg. 2003;13(1):11-7. [Crossref]
- Grisaru-Granovsky S, Rabinowitz R, Ioscovic A, Elstein D, Schimmel MS. Congenital diaphragmatic hernia: review of the literature in reflection of unresolved dilemmas. Acta Paediatr. 2009;98(12):1874-81. [Crossref] [PubMed]
- Hedrick HL. Management of prenatally diagnosed congenital diaphragmatic hernia. Semin Fetal Neonatal Med. 2010;15(1):21-7. [Crossref] [PubMed]
- Congenital Diaphragmatic Hernia Study Group, Lally KP, Lally PA, Lasky RE, Tibboel D, Jaksic T, Wilson JM, et al. Defect size determines survival in infants with congenital diaphragmatic hernia. Pediatrics. 2007;120(3):e651-7. [Crossref] [PubMed]
- van den Hout L, Sluiter I, Gischler S, De Klein A, Rottier R, Ijsselstijn H, et al. Can we improve outcome of congenital diaphragmatic hernia? Pediatr Surg Int. 2009 Sep;25(9):733-43. [Crossref] [PubMed] [PMC]
- dos Santos LR, Maksoud-Filho JG, Tannuri U, Andrade WC, Maksoud JG. [Prognostic factors and survival in neonates with congenital diaphragmatic hernia]. J Pediatr (Rio J). 2003;79(1):81-6. [Crossref] [PubMed]
- Aschcraft KW. Congenital diaphragmatic hernia. In: Aschcraft KW, Holcomb GW, Murphy JP, eds. 4th ed. Pediatric Surgery. Philadelphia: Saunders Elsevier Inc; 2005. p:304-23.
- Moss TJ. Respiratory consequences of preterm birth. Clin Exp Pharmacol Physiol. 2006;33(3):280-4. [Crossref] [PubMed]
- Sivaslı E, Tekinalp G. Ventilatöre bağlı bebeğin bakımı. Yurdakök M, Yiğit Ş, Tekinalp G, editörler. Yenidoğanda Solunum Desteği. Ankara: Güneş Kitabevi; 2005. p.219-33.
- Sturdivant C. A collaborative approach to defining neonatal therapy. Newborn and Infant Nursing Reviews. 2013;13(1):23-6. [Crossref]
- Rous MG, Diez-Betoret J. Is pulmonary rehabilitation really implemented today? Clinical Pulmonary Medicine. 2010;17(2):57-60. [Crossref]
- Christian SP. Chest physiotherapy for infants. Int J Physiother Res. 2014;2(5):699-05. [Link]

13. Diwate A, Khatri S. Effectiveness of chest physiotherapy in prone position on respiratory functions in ventilated neonates: a case series. *Int J Clin and Biomed Res.* 2016;2(4):75-8. [\[Link\]](#)
14. Main E, Denehy L. Pediatric intensive care. In: Main E, Spittle JA, eds. *Cardiorespiratory Physiotherapy: Adults and Pediatrics.* 5th ed. Toronto: Elsevier; 2016. p.455-505.
15. American Academy of Pediatrics Section on Surgery; American Academy of Pediatrics Committee on Fetus and Newborn, Lally KP, Engle W. Postdischarge follow-up of infants with congenital diaphragmatic hernia. *Pediatrics.* 2008;121(3):627-32. [\[Crossref\]](#) [\[PubMed\]](#)
16. Grivell RM, Andersen C, Dodd JM. Prenatal interventions for congenital diaphragmatic hernia for improving outcomes. *Cochrane Database Syst Rev.* 2015;(11):CD008925. [\[Crossref\]](#) [\[PubMed\]](#)
17. Çelmeli F, Palancı AN, Şahin M, Saz EU, Türkahraman D. [Late onset congenital diaphragmatic hernia; presentation of three cases]. *J Pediatr Res.* 2015;2(2):105-8. [\[Crossref\]](#)
18. de Abreu LC, Valenti VE, de Oliveira AG, Leone C, Siqueira AA, Herreiro D, et al. Chest associated to motor physiotherapy improves cardiovascular variables in newborns with respiratory distress syndrome. *Int Arch Med.* 2011;4:37. [\[Crossref\]](#) [\[PubMed\]](#) [\[PMC\]](#)
19. Kamalammal R, Venkatamurthy M, Niranjani M. Recurrent atelectasis in a preterm neonate. *Int J Contemp Pediatr.* 2016;3(2):662-4. [\[Link\]](#)
20. Giannantonio C, Papacci P, Ciarniello R, Tesfagabir MG, Purcaro V, Cota F, et al. Chest physiotherapy in preterm infants with lung diseases. *Italian Journal of Pediatrics.* 2010; 36(1):65. [\[Crossref\]](#) [\[PubMed\]](#) [\[PMC\]](#)
21. Ufuk Yurdalan S. [Pulmonary rehabilitation in newborns]. *Toraks Cerrahisi Bülteni.* 2015;6: 61-8. [\[Crossref\]](#)
22. Flenady VJ, Gray PH. Chest physiotherapy for preventing morbidity in babies being extubated from mechanical ventilation. *Cochrane Database Syst Rev.* 2002;(2):CD000283. [\[Crossref\]](#) [\[PubMed\]](#) [\[PMC\]](#)
23. Rocha G, Soares P, Gonçalves A, Silva AI, Almeida D, Figueiredo S, et al. Respiratory care for the ventilated neonate. *Can Respir J.* 2018;2018:7472964. [\[Crossref\]](#) [\[PubMed\]](#) [\[PMC\]](#)
24. Hough JL, Flenady V, Johnston L, Woodgate PG. Chest physiotherapy for reducing respiratory morbidity in infants requiring ventilatory support. *Cochrane Database Syst Rev.* 2008;(3):CD006445. [\[Crossref\]](#) [\[PubMed\]](#)
25. Smallwood CD, Haynes JM, Carlin BW, Hess DR. Respiratory care year in review 2013: neonatal respiratory care, pulmonary function testing, and pulmonary rehabilitation. *Respir Care.* 2014;59(5):777-87. [\[Crossref\]](#) [\[PubMed\]](#)
26. May DA, Barth RA, Yeager S, Nussbaum-Blask A, Bulas DI. Perinatal and postnatal chest sonography. *Radiol Clin North Am.* 1993;31(3):499-516. [\[PubMed\]](#)
27. Chernick V, Reed MH. Pneumothorax and chylothorax in the neonatal period. *J Pediatr.* 1970;76(4):624-32. [\[Crossref\]](#) [\[PubMed\]](#)
28. Labarge JM, Crombleholme TM, Longaker MT. The fetus with pleural effusions. In: Harrison MR, Golbous MS, Filly RA, eds. *The Unborn Patient.* 2nd ed. Philadelphia: WB Saunders; 1990. p.314-9.
29. Hagay Z, Reece A, Roberts A, Hobbins JC. Isolated fetal pleural effusion: a prenatal management dilemma. *Obstet Gynecol.* 1993;81(1):147-52. [\[PubMed\]](#)