

# Evaluation of the Size of Embryonic Rhombencephalon in Normal Pregnancies

## Normal Gebeliklerde Embriyonik Rombansefalon Büyüklüğünün Değerlendirilmesi

Sinan TAN, MD,<sup>a</sup>  
Ali İPEK, MD,<sup>a</sup>  
Suat KESKİN, MD,<sup>a</sup>  
Hüseyin Levent KESKİN, MD,<sup>b</sup>  
Aydın KURT, MD,<sup>a</sup>  
Halil ARSLAN, MD<sup>a</sup>

Department's of

<sup>a</sup>Radiology,

<sup>b</sup>Obstetrics and Gynecology,

Ankara Atatürk Education Hospital,  
Ankara

Geliş Tarihi/Received: 19.04.2010

Kabul Tarihi/Accepted: 04.11.2010

Yazışma Adresi/Correspondence:

Sinan TAN, MD

Ankara Atatürk Education Hospital,

Department of Radiology, Ankara,

TÜRKİYE/TURKEY

drsinantan@gmail.com

**ABSTRACT Objective:** Rhombencephalon, which is responsible for the development of the cerebellum, cerebellar vermis and cisterna magna, comprises the posterior part of the three brain sacs in the embryo. In this study, we investigated whether the size differences of the rhombencephalon in the first trimester had any influence on the development of the posterior fossa structures. **Material and Methods:** In 87 healthy embryos, rhombencephalon was evaluated using high frequency (7.5 MHz) probe through the transabdominal ultrasonography between 7-10<sup>th</sup> weeks of pregnancy. Rhombencephalon was measured in sagittal planes and the mean diameter was calculated. In addition, the subjects were re-evaluated ultrasonographically in the second trimester in order to detect the development of the cerebellum, cerebellar vermis and cisterna magna, which are formed from the rhombencephalon between 18-24<sup>th</sup> weeks of pregnancy. **Results:** Between the 7<sup>th</sup> and 10<sup>th</sup> gestational weeks, the minimum, maximum and mean rhombencephalon diameters were 1.8 mm, 4.5 mm and 2.9 mm, respectively. **Conclusion:** The size of the rhombencephalon may vary within the same week or from week to week. In the present study, no adverse effect of these differences was established in size on posterior fossa structures.

**Key Words:** Rhombencephalon; embryonic structures; ultrasonography

**ÖZET Amaç:** Serebellum, serebellar vermis ve cisterna magnanın gelişiminden sorumlu olan rombansefalon embriyodaki üç beyin kesesinden en arka bölümünü oluşturur. Bu çalışmada birinci trimesterde rombansefalon büyüklüğündeki farklılıkların posterior fossa yapılarının gelişiminde herhangi bir etkisinin olup olmadığını araştırmak amaçlanmıştır. **Gereç ve Yöntemler:** Seksen yedi sağlıklı embriyoda rombansefalon gebeliğin 7-10. haftaları arasında transabdominal yaklaşımda yüksek frekanslı prob (7.5 MHz) ile ultrasonografik olarak değerlendirildi. Rombansefalon sagittal planda ölçülerek ortalama çap hesaplandı. Ek olarak bu olgular gebeliğin 18-24. haftalarında rombansefalondan gelişen serebellum, serebellar vermis ve cisterna magnanın gelişimini belirlemek amacıyla ultrasonografik olarak yeniden değerlendirildi. **Bulgular:** Gebeliğin 7. ve 10. haftaları arasında minimum, maksimum ve ortalama rombansefalon çapları, sırasıyla, 1.8, 4.5 ve 2.9 mm olarak belirlendi. **Sonuç:** Rombansefalonun büyüklüğü aynı hafta içinde ve haftadan haftaya değişmektedir. Bu çalışmada büyüklükteki bu farklılıkların posterior fossa yapıları üzerine olumsuz etkisi saptanmadı.

**Anahtar Kelimeler:** Rombansefalon; embriyo yapıları; ultrasonografi

Turkiye Klinikleri J Med Sci 2011;31(4):785-9

doi:10.5336/medsci.2010-18827

Copyright © 2011 by Türkiye Klinikleri

**D**uring prenatal development, the human brain is at first resembles a hollow neural tube and develops three swellings at its front end about four weeks after conception. During early development of the central nervous system, the prosencephalon (forebrain), the mes-

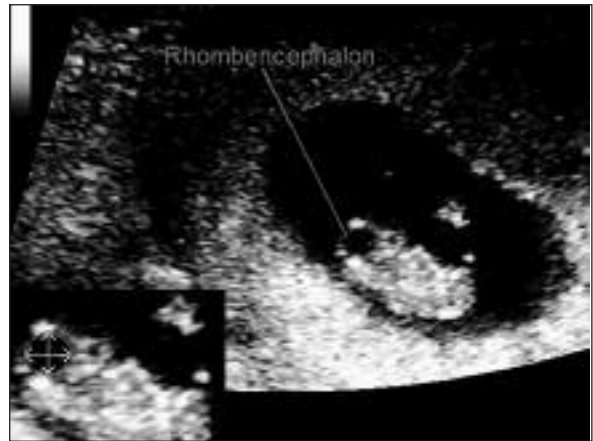encephalon (midbrain), and rhombencephalon (hindbrain) are the three primary portions of the brain. Rhombencephalon, which appears in the form of a cyst in the posterior of the cranium in early pregnancy, is an important structure, which the cerebellum, cerebellar vermis and cisterna magna are derived from.<sup>1,2</sup> The depth and the width of rhombencephalon shows a wide range of variations.<sup>3</sup> Therefore, it is important to evaluate this structure in the first trimester.<sup>4</sup> Although it is a small structure, the more advanced devices and the constant increase in the resolution of images enables to observe rhombencephalon in early pregnancy by transabdominal ultrasonography (US).<sup>5</sup> In this study, our aim was to investigate whether the size differences of the rhombencephalon in the first trimester had any influence on the development of the posterior fossa structures.

## MATERIAL AND METHODS

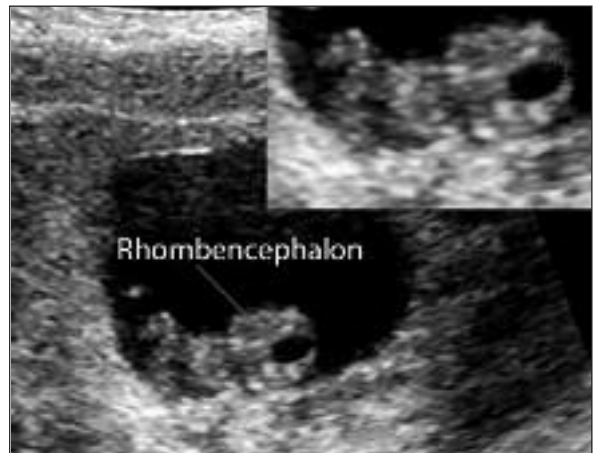This research was approved by the institutional human ethics committee of our hospital.

Pregnant ladies in their first trimester (ages between 18-38), who had referred to our clinic for obstetric ultrasonography, were included in the study. The inclusion criteria were gestational age between 7 and 10 weeks (namely, from 7 weeks 0 days to 10 weeks 6 days) and the existence of cardiac activity. Exclusion criteria were ectopic pregnancies, those with yolk sac and gestational sac abnormalities, fetus not located in the appropriate position for rhombencephalon measurement and those in whom the fetal heart beat could not be visualized. The remaining 87 women were assessed using Logic9 sonographic equipment with a 7.5 MHz convex transabdominal probe (General Electric, Milwaukee, WI, USA). The ultrasonographic images were reviewed by two radiologists who were experienced in obstetric ultrasonography. The patients' urinary bladders were distended, during sonographic examination. The fetal heart beat was examined using Doppler US, and subjects in whom the viability of the embryo was confirmed were included in evaluation.

In the examination, the gestational week was determined based upon crown-rump length (CRL)<sup>6</sup> measurements in the first trimester. Fetal biometry parameters with the average biparietal diameter<sup>7</sup>, abdominal circumference,<sup>8</sup> and femur length<sup>9</sup> measurements were adopted from Hadlock et al. and humerus length<sup>10</sup> measurements were adopted from Jeanty et al. in the second trimester (18<sup>th</sup>-24<sup>th</sup> weeks of pregnancy). Rhombencephalic cavity was evaluated in the embryo between 7<sup>th</sup>-10<sup>th</sup> weeks of pregnancy. Rhombencephalon was measured from internal sides at sagittal plane. The anteroposterior length and cranio-caudal length were also measu-



**FIGURE 1:** Sagittal section of the rhombencephalon with a diameter of 2.6 x 2.6 mm and its borders are seen on the close up image in the embryo with a crown-rump length of 17 mm (consistent with 8 weeks 1 days).



**FIGURE 2:** Sagittal section of the rhombencephalon with a diameter of 3.4 x 2.1 mm and its borders are seen on the close up image in the embryo with a crown-rump length of 17.7 mm (consistent with 8 weeks 2 days).

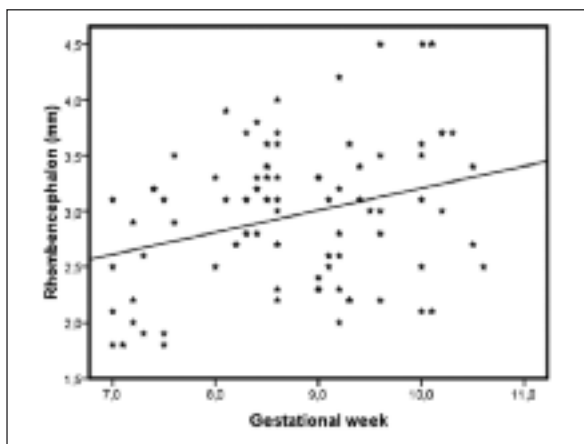
red in this plane and the mean diameter was taken into consideration (Figures 1 and 2). The rhombencephalon size was measured directly via a magnified scan using an incorporated electronic caliper with 0.1 mm accuracy. SPSS software version 13.0 was used for the statistical analysis. The distributions of these values according to the weeks of pregnancy were plotted on a graph (Figure 3). Except for the pregnancies that resulted in abortion, the pregnant subjects underwent screening for congenital abnormalities in the second trimester (18<sup>th</sup>-24<sup>th</sup> weeks of pregnancy). During the screening the development of the cerebellum, cerebellar vermis and cisterna magna that arise from the rhombencephalon were carefully examined. Any abnormal appearance in these structures was identified and noted.

## RESULTS

The cystic rhombencephalon was always visible from the beginning of the 7<sup>th</sup> week. However, the embryos were not included in the study if a suitable sagittal plane could not be obtained for the measurement.

Of 87 embryos; 17 were at the 7<sup>th</sup> week, 29 were at the 8<sup>th</sup> week, 26 were at the 9<sup>th</sup> week, and 15 were at the 10<sup>th</sup> week of gestation.

Considering 7<sup>th</sup>-10<sup>th</sup> weeks of pregnancy, mean rhombencephalon diameter of 87 embryos was



**FIGURE 3:** The distribution of the mean diameters of the rhombencephalon among the embryos according to the week of gestation.

**TABLE 1:** The distribution of the rhombencephalon sizes according to the week of gestation

Gestational week	(n)	Cystic rhombencephalome diameter (mm)		
		Mean (SD)	Smallest	Largest
7th week	17	2.5 (0.6)	1.8	3.5
8th week	29	3.1 (0.5)	2.2	4.0
9th week	26	2.9 (0.6)	2.0	4.5
10th week	15	3.2 (0.7)	2.1	4.5

measured as  $2.9 \pm 0.6$  mm (1.8 mm-4.5 mm) (Table 1). At 7<sup>th</sup>, 8<sup>th</sup>, 9<sup>th</sup> and 10<sup>th</sup> weeks of pregnancy, the mean diameters of rhombencephalon were  $2.5 \pm 0.6$  mm (1.8-3.5 mm),  $3.1 \pm 0.5$  mm (2.2-4.0 mm),  $2.9 \pm 0.6$  mm (2.0-4.5 mm) and  $3.2 \pm 0.7$  mm (2.1-4.5 mm), respectively.

During follow-up examinations, spontaneous abortion occurred in two of the 87 embryos. In all of the 85 pregnancies reaching the second trimester, the sizes of the cerebellum and cisterna magna were found to be normal according to the week of gestation, and the cerebellar vermis was found to be intact. Furthermore, no major central nervous system abnormality was found in these pregnant women. Only in two patients, choroid plexus cysts were observed, but all of them disappeared during the follow-up examinations. Postpartum evaluation, which included physical examination and baseline laboratory tests (blood counts, biochemistry panel, and thyroid function tests), was performed by pediatricians. All children were considered as healthy and their development was considered as normal.

## DISCUSSION

The sophistication of US devices along with the consistent increase in the resolution of images enables the observation of cystic rhombencephalon easily by using a high frequency probe through a transabdominal approach. The person who utilized US in the first trimester should be aware of the general variation in the embryonic cranium. At 6<sup>th</sup>-7<sup>th</sup> weeks of gestation, the rhombencephalic cavity may be seen in the embryonic cranium as a small anechoic structure.<sup>11, 12</sup>

In literature, investigations on the development and measurement of embryonic cranial structures were carried out using transvaginal, intrauterine and three-dimensional US.<sup>13-18</sup> Blaas et al. evaluated embryonic development between the 7<sup>th</sup> and 12<sup>th</sup> weeks of pregnancy using transvaginal US.<sup>3</sup> They demonstrated that the rhombencephalon could be invariably visualized at the 7<sup>th</sup> week, and they measured the size of the rhombencephalic cavity. The mean diameter was 2.46 mm at the 7<sup>th</sup> week and 3.14 mm at the 10<sup>th</sup> week. In addition, in post partum follow up of 29 pregnancies, they established that all infants were developed normally and were healthy.

Cyr et al. detected cystic rhombencephalic structure at the size of 3-4 mm on the posterior aspect of the cranium in 25 patients between the 8<sup>th</sup> and 10<sup>th</sup> weeks of pregnancy.<sup>1</sup> On US examination and postpartum follow-up of these 25 embryos, abnormal posterior fossa structures or neurological deficits were not observed. Tanaka et al. examined embryonic brain vesicles in 51 pregnant women undergoing therapeutic abortion using a high resolution miniature probe (20 MHz), and during follow-ups, rhombencephalon showed a daily increase of 0.1 mm in the size.<sup>12</sup> In our study, we measured the mean diameter of the rhombencephalon as 2.5 mm at the 7<sup>th</sup> week, and

3.2 mm at the 10<sup>th</sup> week. It was also determined that the size of the rhombencephalon varied within the same week and between different weeks. During follow-up, except for two abortions we observed normal development in the cerebellum, cerebellar vermis and cisterna magna between the 18-24<sup>th</sup> weeks of pregnancy in all of the 85 embryos.

In our study, we did not perform US examination with the transvaginal approach and this could be considered as a limitation. Transvaginal approach provides detailed examination of the embryonic and extraembryonic structures. However, optimal imaging of rhombencephalic cavity could be obtained in this study by using a high-frequency probe and magnified scan, so that the examinations could be performed via transabdominal US approach.

## CONCLUSION

In the development process of embryonic brain, the rhombencephalon can be measured using a high frequency probe through a transabdominal US approach. The size of the rhombencephalon may vary within the same week or from week to week. This study shows no adverse impact of these size differences on posterior fossa structures.

## REFERENCES

- Cyr DR, Mack AL, Nyberg AT, Shepard TH, Shuman WP. Fetal Rhombencephalon: Normal US findings. *Radiology* 1988;166(3):691-2.
- Müller F, O'Rahilly R. The human rhombencephalon at the end of the embryonic period proper. *Am J Anat* 1990;189(2):127-45.
- Blaas HG, Eik-Nes SH, Kiserud T, Hellevik LR. Early development of the hindbrain: a longitudinal ultrasound study from 7 to 12 weeks of gestation. *Ultrasound Obstet Gynecol* 1995;5(3):151-60.
- van Zalen-Sprock RM, van Vugt JM, van Geijn HP. First-trimester sonographic detection of neurodevelopmental abnormalities in some single-gene disorders. *Prenat Diagn* 1996; 16(3):199-202.
- Koyuncu FM. [Ultrasonography screening of fetal malformation in the first trimester]. *Turkiye Klinikleri J Gynecol Obst* 2002;12 (4):325-36.
- Hadlock FP, Shah YP, Kanon DJ, Lindsey JV. Fetal crown-rump length: reevaluation of relation to menstrual age (5-18 weeks) with high-resolution real-time US. *Radiology* 1992;182 (2):501-5.
- Hadlock FP, Deter RL, Harrist RB, Park SK. Fetal biparietal diameter: a critical re-evaluation of the relation to menstrual age by means of real-time ultrasound. *J Ultrasound Med* 1982;1(3):97-104.
- Hadlock FP, Deter RL, Harrist RB, Park SK. Fetal abdominal circumference as a predictor of menstrual age. *AJR Am J Roentgenol* 1982; 139(2):367-70.
- Hadlock FP, Harrist RB, Deter RL, Park SK. Fetal femur length as a predictor of menstrual age: sonographically measured. *AJR Am J Roentgenol* 1982;138(5):875-8.
- Jeanty P, Kirkpatrick C, Dramaix-Wilmet M, Struyven J. Ultrasonic evaluation of fetal limb growth. *Radiology* 1981;140(1):165-8.
- Fong KW, Toi A, Salem S, Hornberger LK, Chitayat D, Keating SJ, et al. Detection of fetal structural abnormalities with US during early pregnancy. *Radiographics* 2004;24(1): 157-74.
- Tanaka H, Senoh D, Yanagihara T, Hata T. Intrauterine sonographic measurement of embryonic brain vesicle. *Hum Reprod* 2000; 15 (6):1407-12.
- Timor-Tritsch IE, Peisner DB, Raju S. Sonoembryology: an organ-oriented approach using a high-frequency vaginal probe. *J Clin Ultrasound* 1990;18(4):286-98.

14. Cullen MT, Green J, Whetham J, Salafia C, Gabrielli S, Hobbins JC. Transvaginal ultrasonographic detection of congenital anomalies in the first trimester. *Am J Obstet Gynecol* 1990;163(2):466-76.
15. Hata T, Manabe A, Aoki S, Miyazaki K, Yoshino K, Yamamoto K. Three-dimensional intrauterine sonography in the early first-trimester of human pregnancy: preliminary study. *Hum Reprod* 1998;13(3):740-3.
16. Fujiwaki R, Hata T, Hata K, Kitao M. Intrauterine ultrasonographic assessments of embryonic development. *Am J Obstet Gynecol* 1995;173(6):1770-4.
17. Hata T, Manabe A, Makihara K, Hata K, Miyazaki K, Senoh D. Assessment of embryonic anatomy at 6-8 weeks of gestation by intrauterine and transvaginal sonography. *Hum Reprod* 1997;12(9):1873-6.
18. Feichtinger W. Transvaginal three-dimensional imaging. *Ultrasound Obstet Gynecol* 1993;3(6):375-8.