

An Investigation of the Stiffness and Thickness of Abdominal Muscles in Early/Mild Stage Multiple Sclerosis Patients: A Primary Study

Erken/Hafif Evre Multipl Skleroz Hastalarında Karın Kasları Sertliğinin ve Kalınlığının Araştırılması: Birincil Çalışma

¹Nezhat Özgül ÜNLÜER^a, ²Seval YILMAZ^b, ³Serkan TAŞÇI^c, ⁴Alp ÇETİN^d

^aDepartment of Physiotherapy and Rehabilitation, Ankara Yıldırım Beyazıt University Faculty of Health Sciences, Ankara, TURKEY

^bDepartment of Physiotherapy and Rehabilitation, Yalova University Faculty of Health Sciences, Yalova, TURKEY

^cDepartment of Physiotherapy and Rehabilitation, Toros University Faculty of Health Sciences, Mersin, TURKEY

^dDepartment of Physical Medicine and Rehabilitation, Hacettepe University Faculty of Medicine, Ankara, TURKEY

ABSTRACT Objective: Loss of strength in abdominal muscles causes functional problems. Morphological features such as thickness and stiffness of the muscle give an idea about muscle strength. The morphological features of the abdominal muscles of early/mild multiple sclerosis (MS) patients are unknown. The study aimed to compare the thickness and stiffness of the abdominal muscles of early/mild MS patients with healthy individuals. **Material and Methods:** Seventeen patients with MS between the ages of 19-56 years and 17 healthy individuals between the ages of 22-50 years participated in this study. The disability level was determined by the Expanded Disability Status Scale. Thickness and stiffness of lateral abdominal muscles consisting of external oblique (EO), internal oblique (IO) and transversus abdominis (TrA) muscles were evaluated with ACUSON S3000 (Siemens Medical Solution, Mountain View, CA, USA) ultrasonography device using linear ultrasonography probe (9L4, 4-9 MHz). The stiffness measurements of the muscles were evaluated by shear wave elastography (SWE) method. **Results:** The thickness of the IO (p=0.892), EO (p=0.260), and TrA (p=0.865) muscles were similar in both groups. In addition, IO (p=0.317), EO (p=0.357), TrA (p=0.573) muscle stiffness were found to be similar in both groups. **Conclusion:** In early / mild MS patients, the thickness and stiffness of the IO, EO and TrA muscles were similar to healthy individuals. There was no change in the morphological features of the lateral abdominal muscles of early/mild MS patients.

ÖZET Amaç: Abdominal kaslarda görülen kuvvet kaybı fonksiyonel problemlere neden olmaktadır. Kasın kalınlığı ve sertliği gibi morfolojik özellikleri kas kuvveti ile ilgili fikir vermektedir. Erken/hafif evre multiple skleroz (MS) hastalarının abdominal kaslarının morfolojik özellikleri bilinmemektedir. Bu çalışmanın amacı, erken/hafif evre MS hastalarının karın kaslarının kalınlık ve sertliğini sağlıklı bireylerle karşılaştırmaktır. **Gereç ve Yöntemler:** Bu çalışmaya, 19-56 yaş aralığında 17 MS hastası ve 22-50 yaş aralığında 17 sağlıklı birey katıldı. MS hastalarının özür düzeyi Genişletilmiş Engellilik Durum Ölçeği ile belirlendi. Eksternal oblik (EO), internal oblik (IO) ve transversus abdominis (TrA) kaslarından oluşan lateral abdominal kasların kalınlığı ve sertliği ACUSON S3000 (Siemens Medical Solution, Mountain View, CA, USA) ultrasonografi cihazı ile lineer ultrasonografi probu (9L4, 4-9 MHz) kullanılarak değerlendirildi. Lateral abdominal kasların sertlik ölçümleri shear wave elastografi yöntemi ile değerlendirildi. **Bulgular:** Her iki grupta IO (p=0.892), EO (p=0.260), ve TrA (p=0.865) kaslarının kalınlığı benzerdi. Ayrıca, her iki grupta IO (p=0.317), EO (p=0.357), TrA (p=0.573) kas sertliğinin de benzer olduğu bulundu. **Sonuç:** Erken/hafif evre MS hastalarında, IO, EO ve TrA kaslarının kalınlığı ve sertliği sağlıklı bireylerle benzerdi. Erken/hafif evre MS hastalarının lateral abdominal kaslarının morfolojik özelliklerinde değişim olmadığı tespit edildi.

Keywords: Multiple sclerosis; abdominal muscles; thickness; stiffness; ultrasound; shear wave elastography

Anahtar Kelimeler: Multiple skleroz; abdominal kaslar; kalınlık; sertlik; ultrason; shear wave elastografi

Multiple sclerosis (MS) is an autoimmune central nervous system disease characterized with inflammation, demyelination, and axon damage. The spreading of plaques over time results in many signs and symptoms

in the extremities and trunk.¹ Particularly, insufficiency in maintaining body stability and impaired body control result in impaired balance and a decrease in physical performance.

Correspondence: Nezhat Özgül ÜNLÜER

Department of Physiotherapy and Rehabilitation, Ankara Yıldırım Beyazıt University Faculty of Health Sciences, Ankara, TURKEY/TÜRKİYE

E-mail: nunluer80@yahoo.com



Peer review under responsibility of Türkiye Klinikleri Journal of Health Sciences.

Received: 01 Apr 2020

Received in revised form: 07 Aug 2020

Accepted: 28 Aug 2020

Available online: 21 Jan 2021

2536-4391 / Copyright © 2021 by Türkiye Klinikleri. This is an open access article under the CC BY-NC-ND license (<http://creativecommons.org/licenses/by-nc-nd/4.0/>).

The stability of the trunk is maintained by front side-abdominal muscles, back side-paraspinal muscles, top part-diaphragm, and bottom part-hip muscles and pelvic floor muscles.² Trunk muscles are important for maintaining vertical posture and balance during various functional activities, such as walking, and for controlling extremity movements.^{3,4} For all these functions to be performed and good body stability, the strength and endurance of the local and global abdominal muscles, together with the neural control and adequate position sense, must be sufficient.^{5,6} In the assessment of the trunk muscle activation, electromyography (EMG), computed tomography (CT), and magnetic resonance imaging (MRI) have been used widely; however, there are no sufficient number of studies dynamically evaluating their mechanical and morphological characteristics. Ultrasound is an easy and reliable method to evaluate muscle morphology. In addition, mechanical structures of the muscle, such as stiffness, can be evaluated with shear wave ultrasonography in a valid and reliable manner.^{7,8}

There exist studies in the literature utilizing ultrasonography in the evaluation of abdominal muscles, namely, internal oblique (IO), external oblique (EO), rectus abdominis (RA), and transversus abdominis (TrA) muscles, in asymptomatic populations, and in patients with low back pain.^{9,10} In previous studies, body muscle strength in MS patients has been evaluated with different clinical evaluation batteries; however, there is not enough study evaluating body muscle thickness and stiffness with an objective method. The purpose of this study was to compare the thickness and stiffness of the abdominal muscles of early-/mild-stage MS patients and those of healthy individuals. The hypothesis of the study was: Trunk muscle thickness and stiffness of the early-/mild-stage MS patients would be lower than those of the healthy individuals. Another hypothesis of the present study was that decrease in thickness and stiffness of the assessed muscles would be related to increase in disability status and disease duration.

MATERIAL AND METHODS

INDIVIDUALS

This case-control study was conducted at Hacettepe University (Ankara, Turkey). A total of 34 individu-

als (12 males, 22 females) between the ages of 19 and 56 years (33.7 ± 9.3 years) were selected for this study. The inclusion criteria were as follows: patients with a confirmed diagnosis of clinically definite MS by the McDonald criteria and physician-administered Expanded Disability Status Scale (EDSS) range of 1-4.0.¹¹ The exclusion criteria were: pregnancy, patients with acute attacks (three months prior to the study), and orthopedic limitations of the trunk, such as back pain, scoliosis, or other neurological disorders. A total of 34 participants were included in the study, 17 in early-/mild-stage MS patients group and 17 in the healthy control group with matching ages and genders. This study was performed according the principles of the Declaration of Helsinki Approval and was approved by the Ethics Committee at the University (Approval date and number: 13.07.2018-GO18/659-08)

ULTRASOUND MEASUREMENT

In the thickness and stiffness measurements of the abdominal muscles, an ACUSON S3000 Ultrasound System (Siemens Medical Solutions, Mountain View, California, USA) along with a linear probe (9L4, 4-9 MHz) was used. The dominant leg side during the rest position was used for all assessments. The leg of dominance was determined by asking the participant to kick a ball. Thickness and stiffness measurements of the abdominal muscle (IO, EO, and TrA) were performed in the supine position while the subjects' arms were near the trunk and the legs were in extension (Figure 1 a,b,c). For abdominal muscle measurements, the dominant leg side of the umbilicus and a point 2 cm inside the mid-axillary line was marked as a reference point.¹² The measurement of the thickness of the abdominal muscles was performed at a distance of 15 mm from the starting points of the muscles over a 2D ultrasound image. This point was approximately in the middle of the muscles. To assess the muscle thickness, longitudinal ultrasound scanning of the muscles was performed using the B-mode of the ultrasound imaging device. Stiffness measurements were attained via the shear wave velocity of muscles and the results were calculated with a software program [Virtual Touch Imaging and Quantification (VTIQ); Siemens Medical Solution]. After taking the VTIQ image, range of images (ROIs), 0.5x0.5 mm boxes, were arranged in the direc-

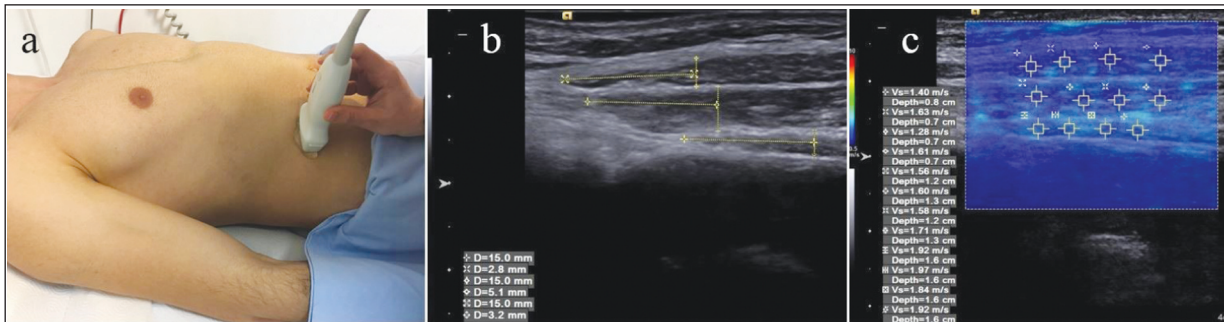


FIGURE 1: (a,b,c) Probe location and ultrasound imaging measurements.

tion of the muscle fibers or tendon line. Average of used ROIs were used to calculate the SWV of assessed VTIQ image. Measurements were made three times and the average value was recorded as the stiffness and thickness values of the muscles.

SAMPLE SIZE CALCULATION

The sample size calculation was made by the SPSS Sample Power 3.0 software (IBM Corporation, Armonk, NY, USA). Based on the calculations, it was found that a minimum of 15 participants were to be included for 80% power and 5% type-I error level to obtain a minimum clinically significant difference of 0.8 mm for TrA thickness (assumed to decrease 20 percent), when the average value in the control group was 3.8 mm, with a standard deviation of 0.8 mm.¹³

STATISTICAL ANALYSIS

A statistics software program (SPSS 21.0, Inc., an IBM Company, Chicago, IL, USA) was used for statistical analyses. The assessed variables were investigated using analytical and visual methods to determine if they were normally distributed. Demographic data and the ultrasonographic parameters were presented using median and minimum-maximum values. As the stiffness and thickness values of the muscles were non-normally distributed, between-group comparisons were made with the Mann-Whitney U test. Correlations between assessed parameters in early-/mild-stage MS patients were investigated using Spearman's test. A p-value of <0.05 was set as the significance level.

RESULTS

No statistically significant difference was observed between groups in terms of age ($p=0.328$), height

($p=0.990$), body mass ($p=0.306$), and body mass index ($p=0.193$). In both groups, the thickness of IO ($p=0.892$), EO ($p=0.260$), and TrA ($p=0.865$) was comparable. Similarly, comparable stiffness of IO ($p=0.170$), EO ($p=0.357$), TrA ($p=0.573$) (Table 1) was observed in both groups.

The relationship analysis showed that both lateral abdominal muscle thickness and lateral abdominal muscle stiffness were not related to the level of disability and disease duration ($p>0.05$) (Table 2).

DISCUSSION

This study aimed to evaluate the changes in morphologic and mechanical features of the abdominal muscles of early-/mild-stage MS patients. The hypothesis of the study was that the thickness of the abdominal muscle would be decreased in early-/mild-stage MS patients. However, it was found that abdominal muscle thickness was comparable in both groups. In addition, the stiffness of abdominal muscles, namely, IO, EO, and TrA, were similar in both groups. At the same time, it was determined that there was no relationship of the stiffness and thickness values of the lateral abdominal muscles of the MS patients with the EDSS levels and disease durations.

The lateral abdominal wall is constituted of three different muscles: the oblique externus (OE), oblique internus (OI), and TrA. All of them have been widely examined by ultrasound imaging mostly in the resting position of the muscle, which is a relatively simple and cost-effective tool allowing reliable assessment of the muscles in different populations^{14,15} In the current study the resting thickness measurements for all imaged muscles for con-

TABLE 1: Median (minimum-maximum) values of the assessed parameters.

Parameters	Control group (n=17)	Patients group (n=17)	p value
	Median (Minimum-Maximum)	Median (Minimum-Maximum)	
Age (years)	33 (22-50)	39 (19-56)	0.328
Height (m)	1.66 (1.51-1.85)	1.67 (1.55-1.81)	0.990
Body mass (kg)	64.80 (49.30-83.40)	70.70 (53.30-93.10)	0.306
BMI (kg/m ²)	23.34 (20.28-28.06)	24.72 (19.11-31.25)	0.193
Gender (male/female)	11/6	11/6	-
EDSS score	-	2.50 (1-4)	-
Disease duration (year)	-	5.00 (1-13)	-
Thickness of selected muscles (mm)			
Abdominal internal oblique	5.80 (9.90-3.10)	6.10 (3.40-10.70)	0.892
Abdominal external oblique	4.10 (2.80-6.70)	4.05 (2.20-5.40)	0.260
Transversus abdominis	3.00 (1.70-5.70)	2.90 (2.30-4.80)	0.865
SWV of selected tissues (m/sec)			
Abdominal internal oblique	5.80 (3.10-9.90)	6.10 (3.40-10.70)	0.170
Abdominal external oblique	4.10 (2.80-6.70)	4.05 (2.20-5.40)	0.357
Transversus abdominis	3.00 (1.70-5.70)	2.90 (2.30-4.80)	0.563

Abbreviations: BMI: Body mass index; EDSS: Expanded Disability Status Scale; SWV: Shear Wave Velocity.

control groups were similar to those obtained in other study¹⁶ but to our knowledge, there is one study investigating the changes in abdominal muscles thickness in MS patients. It was reported in that study that, in parallel with our results, there was no significant difference between the groups in terms of muscle thickness values in resting state in any of the muscles.¹⁷ However, there are some studies reporting changes in different populations with different pathological conditions. For example, İkozoe et al. found that TrA was significantly thinner in the dependent elderly group (2.08±0.51) compared with the young group (4.32±1.49).¹⁸ In the same study, the thickness of the EO was significantly larger in the independent elderly group (4.79±1.75) compared to that of the dependent ones (2.76±1.03). Also, no significant difference was observed in IO thickness between the independent (5.66±1.58) and dependent elderly groups (4.68±1.67). In parallel with our results, Pinto et al. revealed that resting thickness of IO and TrA muscles were almost similar in healthy individuals and low back pain groups.¹³ The present study found that TrA and EO thickness were lower in MS patients compared to healthy individuals, but the decrease in TrA and EO thickness was not statistically significant. In addition, the difference in IO thickness was higher between these two groups, compared to that of the other muscles. However,

TABLE 2: Relationship between disability level and lateral abdominal muscle stiffness and thickness in patients with multiple sclerosis.

	Disability Level (EDSS)		Disease Duration (year)	
	r value	p value	r value	p value
Stiffness				
Abdominal external oblique	0.232	0.370	0.336	0.188
Abdominal internal oblique	-0.018	0.945	0.210	0.420
Transversus abdominis	0.262	0.309	0.119	0.648
Thickness				
Abdominal external oblique	-0.252	0.347	0.334	0.206
Abdominal internal oblique	0.248	0.338	0.009	0.974
Transversus abdominis	-0.282	0.272	-0.210	0.938

Abbreviations: EDSS: Expanded Disability Status Scale; r: Spearman Correlation Coefficient.

there was no statically difference in abdominal muscle thickness, such as EO, IO, and TrA, in the MS group in comparison to the control group. Different from our results, Yoosefinejad et al., who used dynamometers to measure muscle strength, found a significant decrease in muscle strength of core muscles in MS patients compared to healthy individuals.¹⁹ This outcome may be due to the condition that muscle morphology in ambulatory MS patients in the early period is not affected, although they experience a decrease in the ability to produce force. The decrease in force production in early-/mild-stage MS patients may be related to neuromuscular efficiency.

It was reported that neuromuscular efficiency is related to maximal voluntary contraction, and it is decreased in individuals with low physical activity.²⁰ In the present study, evaluations were made in resting position and no extremity movement was involved. The outcome that there was no difference in muscle thickness between MS patients and control groups may be associated with the fact that lateral abdominal muscles, specifically TrA, are responsible for stability during functional activities.²¹ In other words, it may be associated with the fact that the evaluations were made in resting position. The obtained results suggest that task-oriented trainings should be considered rather than strength training programs in early-/mild-stage MS patients.

The other hypothesis of this study was that abdominal muscle stiffness would be lower in early-/mild-stage MS patients compared to healthy individuals. Different from our hypothesis, we found no difference in muscle stiffness between MS patients and healthy individuals. In the literature, there are few studies evaluating the stiffness of the lateral abdominal muscles by the shear wave elastography (SWE) method.²²⁻²⁴ Linek P. et al. used the SWE method to compare the stiffness of the concave and convex side lateral abdominal muscles in individuals with thoracolumbar scoliosis.²² Studies in neurological diseases mostly include elastography evaluations of the upper extremity in poststroke individuals. To the best of our knowledge, this is the first study evaluating the stiffness of the lateral abdominal muscles in MS patients. Results are different in changes in muscle elasticity that is based on the development of spasticity following stroke in early period of stroke. For example, chronic spasticity is largely connected with higher intramuscular adipose and connective tissue resulting in higher echo intensity.²⁵ Therefore, higher muscle stiffness occurring along with chronic spasticity is associated with transformations in tissue composition. To the extent of our knowledge, no published study exists examining the stiffness of abdominal muscles in MS patients. No difference was found between MS patients and healthy individuals, which may be attributed to the fact that the participants were early-/mild-stage MS patients and they did not have spasticity.

In the literature, in order to better understand the lateral abdominal muscle morphology and to determine potential confusions, the relationship between the disease and disability level as well as the demographic features such as age, gender, body mass, and body height are examined.^{26,27} In our study, it was found that there was no relationship of lateral abdominal muscle stiffness and thickness measurements with EDSS levels and disease duration. We think this may be related to the short duration of the disease and low disability level.

Study limitations: This study has a few limitations. Firstly, MS patients with early-/mild-stage disability were included in this study. Therefore, the results would be different in MS groups with severe disability. Secondly, all evaluations in the present study were carried out in the resting position. In further studies, evaluations may be carried out during activity, especially for the lateral abdominal muscles.

CONCLUSION

The obtained results suggest that abdominal muscle morphology may not have changed in early/mild stage MS. In addition, stiffness of abdominal muscles in early-/mild-stage MS patient was similar to healthy individuals. It was thought that the decrease in trunk muscle strength may not be related to morphology and mechanical properties of these muscles, and it may be related to neuromuscular interaction in early/mild-stage MS patients. Consequently, in rehabilitation of the early-/mild-stage MS patients, exercises that increase neuromuscular control may be more meaningful than exercise approaches that increase strength.

Source of Finance

During this study, no financial or spiritual support was received neither from any pharmaceutical company that has a direct connection with the research subject, nor from a company that provides or produces medical instruments and materials which may negatively affect the evaluation process of this study.

Conflict of Interest

No conflicts of interest between the authors and / or family members of the scientific and medical committee members or members of the potential conflicts of interest, counseling, expertise, working conditions, share holding and similar situations in any firm.

Authorship Contributions

Idea/Concept: Nezihat Özgül Ünlüler; **Design:** Nezihat Özgül Ünlüler; **Control/Supervision:** Nezihat Özgül Ünlüler, Alp Çetin; **Data Collection and/or Processing:** Seval Yılmaz, Nezihat Özgül Ünlüler; **Analysis and/or Interpretation:** Serkan Taş;

Literature Review: Alp Çetin; **Writing the Article:** Nezihat Özgül Ünlüler, Seval Yılmaz, Serkan Taş; **Critical Review:** Nezihat Özgül Ünlüler, Seval Yılmaz; **References and Fundings:** Alp Çetin, Nezihat Özgül Ünlüler; **Materials:** Alp Çetin, Seval Yılmaz.

REFERENCES

- O'Connor P; Canadian Multiple Sclerosis Working Group. Key issues in the diagnosis and treatment of multiple sclerosis. An overview. *Neurology*. 2002;59(6 Suppl 3):S1-33.[Crossref] [PubMed]
- Akuthota V, Nadler SF. Core strengthening. *Arch Phys Med Rehabil*. 2004;85(3 Suppl 1):S86-92.[Crossref] [PubMed]
- Verheyden G, Nieuwboer A, Mertin J, Preger R, Kiekens C, De Weerd W, et al. The Trunk Impairment Scale: a new tool to measure motor impairment of the trunk after stroke. *Clin Rehabil*. 2004;18(3):326-34. [Crossref] [PubMed]
- Lanzetta D, Cattaneo D, Pellegatta D, Cardini R. Trunk control in unstable sitting posture during functional activities in healthy subjects and patients with multiple sclerosis. *Arch Phys Med Rehabil*. 2004;85(2):279-83.[Crossref] [PubMed]
- Cholewicki J, Panjabi MM, Khachatryan A. Stabilizing function of trunk flexor-extensor muscles around a neutral spine posture. *Spine (Phila Pa 1976)*. 1997;22(19):2207-12.[Crossref] [PubMed]
- Ebenbichler GR, Oddsson LI, Kollmitzer J, Erim Z. Sensory-motor control of the lower back: implications for rehabilitation. *Med Sci Sports Exerc*. 2001;33(11):1889-98.[Crossref] [PubMed]
- Taş S, Onur MR, Yılmaz S, Soylu AR, Korkusuz F. Shear Wave Elastography Is a Reliable and Repeatable Method for Measuring the Elastic Modulus of the Rectus Femoris Muscle and Patellar Tendon. *J Ultrasound Med*. 2017;36(3):565-70.[Crossref] [PubMed]
- Miyamoto N, Hirata K, Kanehisa H, Yoshitake Y. Validity of measurement of shear modulus by ultrasound shear wave elastography in human pennate muscle. *PLoS One*. 2015; 10(4):e0124311.[Crossref] [PubMed] [PMC]
- Stetts DM, Freund JE, Allison SC, Carpenter G. A rehabilitative ultrasound imaging investigation of lateral abdominal muscle thickness in healthy aging adults. *J Geriatr Phys Ther*. 2009;32(2):60-6. Erratum in: *J Geriatr Phys Ther*. 2009;32(3):110.[Crossref] [PubMed]
- Sions JM, Teyhen DS, Hicks GE. Criterion Validity of Ultrasound Imaging: Assessment of Multifidus Cross-Sectional Area in Older Adults With and Without Chronic Low Back Pain. *J Geriatr Phys Ther*. 2017;40(2):74-9.[Crossref] [PubMed] [PMC]
- Kurtzke JF. Rating neurologic impairment in multiple sclerosis: an expanded disability status scale (EDSS). *Neurology*. 1983;33(11):1444-52. [Crossref] [PubMed]
- Hirayama K, Akagi R, Moniwa Y, Okada J, Takahashi H. TRANSVERSUS ABDOMINIS ELASTICITY DURING VARIOUS EXERCISES: A SHEAR WAVE ULTRASOUND ELASTOGRAPHY STUDY. *Int J Sports Phys Ther*. 2017;12(4):601-6.[PubMed] [PMC]
- Pinto RZ, Ferreira PH, Franco MR, Ferreira MC, Ferreira ML, Teixeira-Salmela LF, et al. The effect of lumbar posture on abdominal muscle thickness during an isometric leg task in people with and without non-specific low back pain. *Man Ther*. 2011;16(6):578-84.[Crossref] [PubMed]
- Linek P, Saulicz E, Wolny T, Myśliwiec A. Reliability of B-mode sonography of the abdominal muscles in healthy adolescents in different body positions. *J Ultrasound Med*. 2014;33(6):1049-56. [Crossref] [PubMed]
- Wilson A, Hides JA, Blizzard L, Callisaya M, Cooper A, Srikanth VK, et al. Measuring ultrasound images of abdominal and lumbar multifidus muscles in older adults: A reliability study. *Man Ther*. 2016;23:114-9.[Crossref] [PubMed]
- Rankin G, Stokes M, Newham DJ. Abdominal muscle size and symmetry in normal subjects. *Muscle Nerve*. 2006;34(3):320-6.[Crossref] [PubMed]
- Freund JE, Stetts DM, Vallabhajosula S. Relationships between trunk performance, gait and postural control in persons with multiple sclerosis. *NeuroRehabilitation*. 2016;39(2):305-17. [Crossref] [PubMed]
- Ikezoe T, Mori N, Nakamura M, Ichihashi N. Effects of age and inactivity due to prolonged bed rest on atrophy of trunk muscles. *Eur J Appl Physiol*. 2012;112(1):43-8.[Crossref] [PubMed]
- Yoosefinejad AK, Motealleh A, Khademi S, Hosseini SF. Lower Endurance and Strength of Core Muscles in Patients with Multiple Sclerosis. *Int J MS Care*. 2017;19(2):100-4.[Crossref] [PubMed] [PMC]
- David P, Mora I, Pérot C. Neuromuscular efficiency of the rectus abdominis differs with gender and sport practice. *J Strength Cond Res*. 2008;22(6):1855-61.[Crossref] [PubMed]
- Hodges PW, Richardson CA. Transversus abdominis and the superficial abdominal muscles are controlled independently in a postural task. *Neurosci Lett*. 1999;265(2):91-4.[Crossref] [PubMed]
- Linek P, Wolny T, Sikora D, Klepek A. Supersonic Shear Imaging for Quantification of Lateral Abdominal Muscle Shear Modulus in Pediatric Population with Scoliosis: A Reliability and Agreement Study. *Ultrasound Med Biol*. 2019;45(7):1551-61.[Crossref] [PubMed]
- Linek P, Wolny T, Myśliwiec A, Klepek A. Shear wave elastography for assessing lateral abdominal muscles in thoracolumbar scoliosis: A preliminary study. *Biomed Mater Eng*. 2020;31(2):131-42.[Crossref] [PubMed]
- Tran D, Podwojewski F, Beillas P, Ottenio M, Voirin D, Turquier F, et al. Abdominal wall muscle elasticity and abdomen local stiffness on healthy volunteers during various physiological activities. *J Mech Behav Biomed Mater*. 2016;60:451-9.[Crossref] [PubMed]
- Lieber RL, Ward SR. Cellular mechanisms of tissue fibrosis. 4. Structural and functional consequences of skeletal muscle fibrosis. *Am J Physiol Cell Physiol*. 2013;305(3):C241-52.[Crossref] [PubMed] [PMC]
- Linek P, Saulicz E, Wolny T, Myśliwiec A. Intra-rater reliability of B-mode ultrasound imaging of the abdominal muscles in healthy adolescents during the active straight leg raise test. *PM R*. 2015;7(1):53-9.[Crossref] [PubMed]
- Linek P. The importance of body mass normalisation for ultrasound measurements of the morphology of oblique abdominal muscles: the effect of age, gender, and sport practice. *Folia Morphol (Warsz)*. 2018;77(1):123-30.[Crossref] [PubMed]