

Granulomatous Hepatitis as a Rare Complication of Intravesical BCG Therapy for Bladder Cancer: Case Report

Mesane Kansesinde İntravezikal BCG Tedavisinin Seyrek Bir Komplikasyonu: Granülomatöz Hepatit

İbrahim Koral ÖNAL, MD,^a
Meral AKDOĞAN, MD,^a
Adalet AYPAK, MD,^b
Perihan OĞUZ, MD,^a
Tülay TEMUÇİN KEKLİK, MD,^c
Erkin ÖZTAŞ, MD^a
Nurgül ŞAŞMAZ, MD^a

Departments of
^aGastroenterology,
^bInfectious Diseases,
^cPathology,
Yüksek İhtisas
Training and Research Hospital,
Ankara

Geliş Tarihi/Received: 05.06.2008
Kabul Tarihi/Accepted: 19.08.2008

Yazışma Adresi/Correspondence:
İbrahim Koral ÖNAL, MD
Turkey Yüksek İhtisas
Training and Research Hospital,
Department of Gastroenterology,
Ankara,
TÜRKİYE/TURKEY
koralonal@yahoo.com

ABSTRACT Although intravesical bacillus Calmette-Guerin (BCG) administration is an effective method in the treatment of superficial urinary bladder carcinoma, some complications such as a granulomatous reaction outside the urinary tract may arise. We report a case of granulomatous hepatitis following intravesical BCG therapy. A fifty eight year-old man admitted with fever and jaundice for ten days. His medical history included superficial bladder carcinoma and three courses of intravesical BCG administration. He had a fever of 39 °C, jaundice and hepatomegaly on physical examination. In the laboratory examination hepatic-laboratory test results were abnormal and anemia and high sedimentation rate were presented. Abdominal ultrasonography revealed hepatomegaly. The liver biopsy showed multiple granulomas. The diagnosis was BCGitis. The clinical and laboratory findings were completely normal at the end of a 6-month antituberculous treatment course. The frequency of hepatitis related to BCG is less than 1% among the cases of intravesical BCG administration. The factors which interfere with the mucosal integrity of the urinary bladder and immunosuppression increase the risk for systemic BCG infection. Hypersensitivity reaction is thought to play an important role in the pathogenesis.

Key Words: *Mycobacterium bovis*; urinary bladder neoplasms; liver diseases

ÖZET İntravezikal bacillus-Calmette-Guerin (BCG) uygulaması süperfisyel mesane karsinomu tedavisinde etkili bir yöntem olmakla birlikte idrar yolları dışında granülomatöz reaksiyon gibi bazı komplikasyonlar gelişebilmektedir. Bu yazıda intravezikal BCG tedavisini takiben gelişen bir granülomatöz hepatit olgusunu takdim etmekteyiz. Elli sekiz yaşında erkek hasta on gündür mevcut ateş ve sarılık yakınmalarıyla başvurdu. Özgeçmişinde süperfisyel mesane karsinomu ve üç kür intravezikal BCG tedavisi mevcuttu. Fizik incelemede 39 °C ateş, ikter ve hepatomegali saptandı. Laboratuvar analizde karaciğer testlerinde bozulma, anemi ve sedimentasyon hızında yükselme tespit edildi. Abdomen ultrasonografi hepatomegali varlığını gösterdi. Karaciğer biyopsisinde multipl granülom saptanan hastaya BCGitis tanısı konularak antitüberküloz tedavi başlandı. Altı ay sonunda klinik ve laboratuvar olarak bulgular normale döndü. İntravezikal BCG uygulanan hastalarda BCG ilişkili hepatit sıklığı %1'den azdır. Mesane mukozasının bütünlüğünü bozan faktörler ve immünsupresyon sistemik BCG enfeksiyonu riskini artırır. Patogeneizde hipersensitive reaksiyonunun önemli rol oynadığı düşünülmektedir.

Anahtar Kelimeler: *Mycobacterium bovis*; mesane neoplazmları; karaciğer hastalıkları

Türkiye Klinikleri J Med Sci 2010;30(3):1092-5

Intravesical Bacillus Calmette Guerin (BCG) is therapeutically and prophylactically used in the management of superficial bladder cancer as the most effective adjuvant treatment.¹⁻³ Clinical trials have shown an

average initial tumor-free-response-rate of 76%.⁴ As BCG has been increasingly used, a number of reports have accumulated regarding its side effects.^{5,6} Local toxicity, most commonly cystitis, is much more common. Flu like symptoms are the most common manifestations of systemic toxicity and they are self limiting.⁵ On the other hand, severe systemic complications are well known. They are hepatitis, sepsis leading to shock, disseminated intravascular coagulation and multiorgan failure.^{6,7}

Cases with granulomatous hepatitis have been more commonly reported in the last years.⁶ The early diagnosis of the BCG-induced hepatitis is important because it may be life saving to stop BCG treatment and to start antituberculosis treatment as soon as possible. Here we report such a case to attract attention to this potential complication of BCG and its management.

CASE REPORT

A 58-year-old man was admitted after a 10-day history of fever and jaundice (12/11/07). His medical history included superficial bladder carcinoma. He was diagnosed one year before. He had a resection surgery and then three courses of intravesical BCG administration. The last course was one month before his admission. He did not have any history of tuberculosis, and preoperative chest radiogram was reported to be normal. He had a fever of 39 °C, jaundice and hepatomegaly on physical examination. The laboratory examination revealed elevated liver enzymes, predominantly cholestatic ones, hyperbilirubinemia, hypoalbuminemia, anemia (hemoglobin 9.3 g/dl), and a high erythrocyte sedimentation rate (50 mm/h) (Table 1). The viral markers for hepatitis A, B and C were negative. The patient was hospitalized for supportive treatment and further diagnostic tests were carried out. No microorganisms were grown in the blood and urine cultures. The chest radiogram was normal. The abdominal ultrasonography revealed no additional abnormalities except hepatomegaly. Tuberculin skin test was negative. A liver biopsy showed multiple granulomas formed by polymorphonuclear and eosinophilic leucocytes, lymphocytes, epithelioid and Langhans type

multinucleated giant cells (Figure 1, 2). The diagnosis was BCGitis. An antituberculous treatment including of isoniazid (300 mg/day), rifampin (600 mg/day) and ethambutol (1500 mg/day) was started (20/11/07). There was a dramatic clinical and laboratory response within one week (Table 1). His sustained fever resolved promptly and his jaundice almost disappeared. He was discharged (28/11/07). He had no complaints and his laboratory findings were completely normal at the control visit after three months and after 6 months of antituberculous treatment. Because there was no tumor relapse in the cystoscopic control, no further intravesical BCG was planned.

DISCUSSION

The exact mechanism of antitumoral effect associated with intravesical BCG treatment is unknown. Among the hypotheses are local inflammation and nitric oxide induction.⁸ Another argument is the immune response to BCG. According to this mechanism, phagocytosis of BCG by antigen presenting cells and recognition of the bacterial antigens by CD4 lymphocytes lead to release of interleukin-2, interferon gamma and other inflammatory cytokines.⁹ Increased cytotoxic populations are thought to be responsible for the antitumoral effect. The same delayed type hypersensitivity reaction was postulated to mediate the development of granulomatous hepatitis. This idea was supported by the fact that addition of steroids to treatment was shown to improve clinical response.¹⁰ There are animal studies of granulomatous hepatitis in which optimal survival could be obtained with combination of antituberculous drugs and steroids.¹¹

Hepatitis occurs in less than 1% of the BCG-treated patients.¹² The factors which interfere with the mucosal integrity of the urinary bladder e.g. transurethral tumor resection, traumatic catheterisation and associated cystitis increase the risk for systemic BCG infection.¹³ Immunosuppression and genetic factors^{14,15} may also increase the susceptibility to infection.

Acid-fast bacilli can be discovered in less than 10% of the samples from liver, bone marrow and blood. The positivity of polymerase chain re-

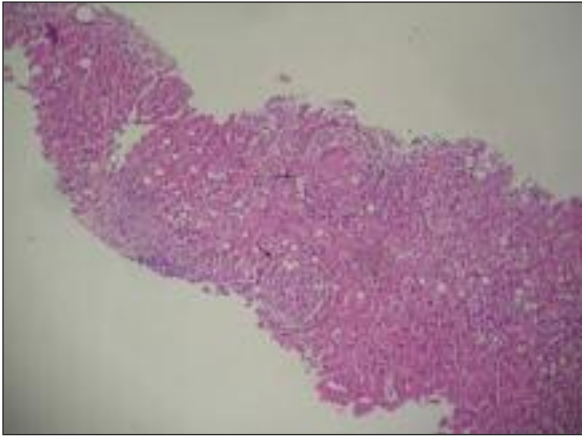


FIGURE 1: Two hepatic granulomas are seen in the pathologic examination of the liver (Hematoxylen-Eosin staining, X40 magnification).

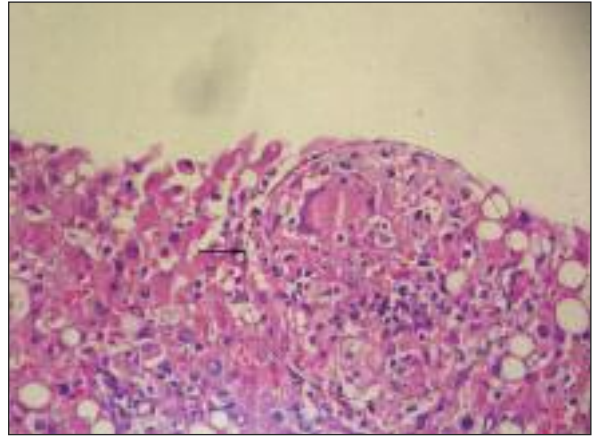


FIGURE 2: Hepatic granuloma: Multinucleated giant cells encircled by polymorphonuclear and eosinophilic leucocytes and lymphocytes (Hematoxylen-Eosin staining, X100 magnification).

TABLE 1: The liver parameters of the patient during his admission and follow up.

Date	ALT	AST	GGT	ALP	T. Bil	D. Bil	Alb
12/11/07	158	456	376	1637	24	18	1.9
23/11/07	51	95	205	1041	3	1	3.6
26/11/07	31	61	109	721	2.4	1.4	3.4
28/11/07	50	56	112	780	2.6	1.7	3.6
08/02/08	12	36	93	333	0.57	0.2	3.8

Normal ranges: ALT(0-40 IU), serum alanine aminotransferase; AST (0-33 IU), serum aspartate aminotransferase; GGT (0-40 IU), serum gamma-glutamyl transpeptidase; ALP (0-129 IU), serum alkaline phosphatase; T. Bil (0-1.1 mg/dl), total bilirubin; D. Bil (0-0.3 mg/dl), direct bilirubin, Alb (3.4-5.4 g/dl), albumin

action for the bacilli is seen in less than 20% of the cases. On the other hand, granulomas can be shown in almost all of the cases in liver biopsy specimens.¹²

A six-month treatment including isoniazid and rifampicin has been suggested in the management.¹² Whether the steroids should be added at the beginning of the therapy is not clear. While some authors prefer the combination after getting suboptimal response to antituberculous treatment, the others initially use steroids together with the antituberculous drugs as suggested in the previous

reports.^{10,11} Although the patients usually improve with treatment, fatal cases have also been reported.⁶

In conclusion, granulomatous hepatitis should be suspected when persistent fever and abnormal hepatic laboratory-test results are observed in a patient with the history of intravesical BCG administration. Early liver biopsy and prompt initiation of the antituberculous treatment may be life saving.

REFERENCES

1. Böhle A, Jocham D, Bock PR. Intravesical bacillus Calmette-Guérin versus mitomycin C for superficial bladder cancer: a formal meta-analysis of comparative studies on recurrence and toxicity. *J Urol* 2003;169(1):90-5.
2. Palayew M, Briedis D, Libman M, Michel RP, Levy RD. Disseminated infection after intravesical BCG immunotherapy. Detection of organisms in pulmonary tissue. *Chest* 1993;104(1):307-9.
3. McParland C, Cotton DJ, Gowda KS, Hoepfner VH, Martin WT, Weckworth PF. Miliary *Mycobacterium bovis* induced by intravesical bacille Calmette-Guérin immunotherapy. *Am Rev Respir Dis* 1992;146(5 Pt 1):1330-3.
4. De Jager R, Guinan P, Lamm D, Khanna O, Brosman S, De Kernion J, et al. Long-term complete remission in bladder carcinoma in situ with intravesical TICE bacillus Calmette Guérin. Overview analysis of six phase II clinical trials. *Urology* 1991;38(6):507-13.
5. Orihuela E, Herr HW, Pinsky CM, Whitmore WF Jr. Toxicity of intravesical BCG and its management in patients with superficial bladder tumors. *Cancer* 1987;60(3):326-33.
6. Ersoy O, Aran R, Aydinli M, Yonem O, Harmanci O, Akdogan B, et al. Granulomatous hepatitis after intravesical BCG treatment for bladder cancer. *Indian J Gastroenterol* 2006;25(5):258-9.
7. Peyrière H, Klouche K, Béraud JJ, Blayac JP, Hillaire-Buys D. Fatal systemic reaction after multiple doses of intravesical bacillus Calmette-Guérin for polyposis. *Ann Pharmacother* 2000;34(11):1279-82.
8. Witjes JA, vd Meijden AP, Debruyne FM. Use of intravesical bacillus Calmette-Guérin in the treatment of superficial transitional cell carcinoma of the bladder: an overview. *Urol Int* 1990;45(3):129-36.
9. Patard JJ, Guillé F, Lobel B, Abbou CC, Chopin D. [Current state of knowledge concerning the mechanisms of action of BCG]. *Prog Urol* 1998;8(3):415-21.
10. Molina JM, Rabian C, D'Agay MF, Modai J. Hypersensitivity systemic reaction following intravesical bacillus Calmette-Guérin: successful treatment with steroids. *J Urol* 1992;147(3):695-7.
11. Lamm DL. Complications of bacillus Calmette-Guérin immunotherapy. *Urol Clin North Am* 1992;19(3):565-72.
12. Lamm DL, van der Meijden PM, Morales A, Brosman SA, Catalona WJ, Herr HW, et al. Incidence and treatment of complications of bacillus Calmette-Guérin intravesical therapy in superficial bladder cancer. *J Urol* 1992;147(3):596-600.
13. Kamphuis JT, Buiting AG, Miséré JF, van Berge Henegouwen DP, van Soolingen D, Rensma PL. BCG immunotherapy: be cautious of granulomas. Disseminated BCG infection and mycotic aneurysm as late complications of intravesical BCG instillations. *Neth J Med* 2001;58(2):71-5.
14. Bellamy R, Ruwende C, Corrah T, McAdam KP, Whittle HC, Hill AV. Variations in the NRAMP1 gene and susceptibility to tuberculosis in West Africans. *N Engl J Med* 1998;338(10):640-4.
15. Uysal G, Doğru U. [Immunology of childhood tuberculosis and recent advances]. *Turkiye Klinikleri J Pediatr* 1999;8(3):158-63.