

Case Study of a Very Early Diagnosed and Successfully Treated Heterotopic Pregnancy

Ali GEMİCİ^a,
Ayşegül ALKILIÇ^b,
Seval YILMAZ ERGANİ^a,
Metin M. ALTAY^a

^aClinic of Obstetrics and Gynecology,
Etlik Women's Health Training and
Research Hospital,
Ankara, TURKEY

^bClinic of Obstetrics and Gynecology,
Ağrı Diyadin State Hospital,
Ağrı, TURKEY

Received: 13.06.2018

Received in revised form: 01.10.2018

Accepted: 01.10.2018

Available online: 05.03.2019

Correspondence:

Ali GEMİCİ
Etlik Women's Health Training and
Research Hospital,
Clinic of Obstetrics and Gynecology,
Ankara, TURKEY
gemiciali@yahoo.com

ABSTRACT Spontaneous heterotopic pregnancy (HP) is rare and defined as combination of intrauterine and ectopic embryo implantation in one pregnancy. Most cases present with acute abdominal pain with hemoperitoneum. During the early stages of pregnancy, a HP diagnosis is uncommon. In the following, we present a case report of spontaneous HP, which was diagnosed before tubal rupture, and discuss methods of early diagnosis. A 27-year-old woman was admitted to the clinic complaining of vaginal spotting. An ultrasonography revealed two corpus luteum cysts, as well as a six-week intrauterine pregnancy together with a right tubal pregnancy with no pelvic free fluid. A laparoscopic right salpingectomy was performed. The pregnancy continued with no complications and ended after a gestation period of 38 weeks and four days with a vaginal delivery. In conclusion, it could be beneficial to use a vaginal ultrasound for examining not only uterus but also both adnexal regions at the early pregnancy period.

Keywords: Early diagnosis; first trimester ultrasound; heterotopic pregnancy

Spontaneous heterotopic pregnancy (HP) is rare and defined as combination of intrauterine and ectopic embryo implantation in one pregnancy. Due to the extreme rarity, HPs may be misdiagnosed, especially in cases where an intrauterine pregnancy has already been detected. The incidence of HP has increased to date due to the extended use of assisted reproductive technologies, but the estimated incidence for spontaneous cycles is 1/30.000.¹⁻³ Unfortunately, in some cases the first presenting symptom of a HP is acute abdominal pain with hemoperitoneum needing emergent approach.³ Nowadays minimally invasive treatment modalities come into forefront at the gynaecologic practice. Early diagnosis may provide less invasive interventions and better outcomes for the uterine pregnancy. The early diagnosis is primarily based on clinical suspicion especially in patients without any complaints. In the following, we present an early-diagnosed spontaneous HP case that was treated by laparoscopy and discuss possible factors that may affect the early diagnosis of HP.

CASE REPORT

A 27-year-old (two gravida, one para) woman presented with a complaining of vaginal spotting. She had previously been informed of an intrauterine pregnancy at another hospital. She was six weeks and three days pregnant according to her last menstrual period, and her b-hCG level was 20,000 mIU/ml (compatible with between four and five weeks of preg-

nancy). Hers was a spontaneous conception. Prior to that, she had had an uneventful pregnancy ending in vaginal delivery. She did not have any risk factors for an ectopic pregnancy. Both her abdominal and vaginal examinations were normal except for brownish vaginal discharge. A vaginal ultrasound was performed by a senior sonographer and showed the intrauterine gestational sac, a crown-rump length of 4 mm and current cardiac activity (Figure 1). She had two corpus luteum cysts (CL) on her left ovary (Figure 2 A). On the contralateral part, there was a mass measuring 13 by 11 mm located on the right tuba with a yolk sac (Figure 2 B). The tuba seemed to be inflamed but serosal integrity was not disrupted. No free fluid was detected in the pelvis. The patient was informed of her medical situation and a laparoscopic right salp-

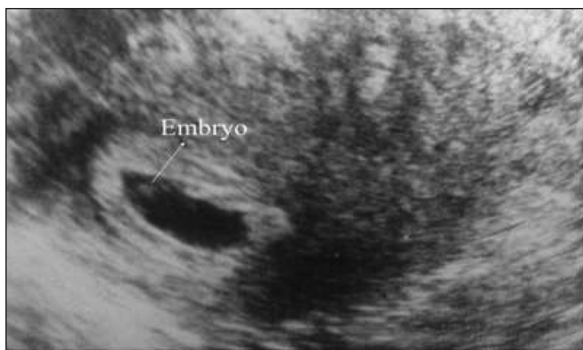


FIGURE 1: Intrauterine pregnancy with embryo.

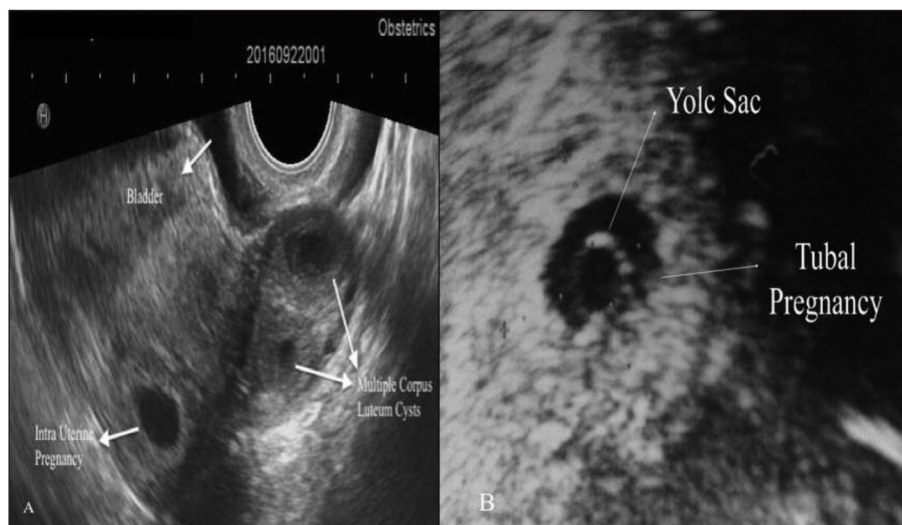


FIGURE 2: A. Demonstrating more than one CL with intra uterine pregnancy. B. Demonstrating extra uterine pregnancy with yolk sac.

ingectomy was performed for the ectopic focus (Figure 3 A, Figure 3 B). The pathology revealed a tubal ectopic pregnancy (Figure 4). On the second day following the operation, foetal cardiac activity was confirmed and the patient was discharged from the hospital for a routine pregnancy follow-up. The patient's first trimester assessment was carried out without problems (Figure 5). Her pregnancy ended at 38 weeks and four days of gestation with a spontaneous labour; a healthy newborn weighing 3.650 grams was delivered vaginally.

DISCUSSION

Spontaneous heterotopic pregnancy is a rare condition.^{1,2} The detection of an intrauterine pregnancy reduces the likelihood of an ectopic pregnancy, but a case of HP may be missed. Due to this state of affairs, most HPs present with acute abdominal pain and hemoperitoneum¹. The early diagnosis of a heterotopic pregnancy is important in order to prevent possible progression of an adverse medical situation and providing minimally invasive treatment approaches. On the other hand, early diagnosis is difficult and is primarily based on clinical suspicion.^{2,3} In the literature, very few cases have been reported as being detected during the first trimester, and only in one case was the baby delivered with no problems at all (Table 1).⁴⁻⁷

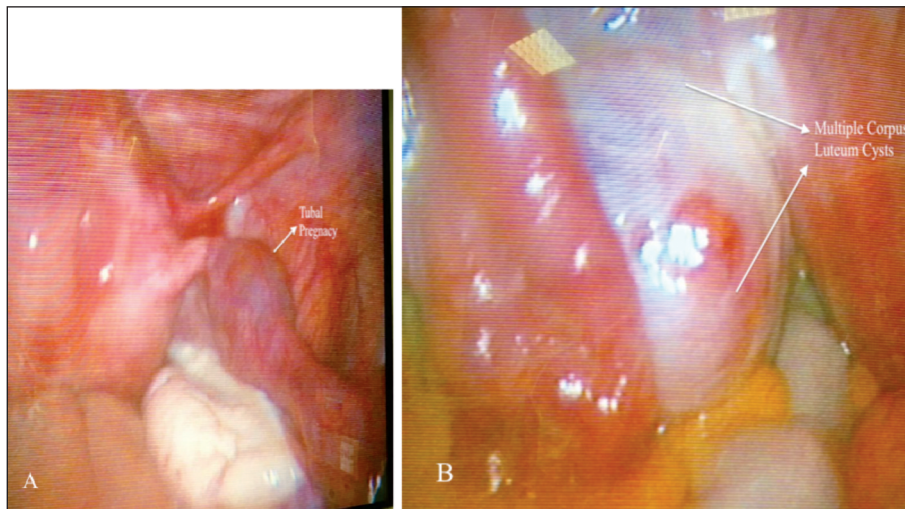


FIGURE 3: A. Intraoperative appearance of tubal pregnancy. B. Intraoperative appearance of multiple corpus luteum (CL) cysts.

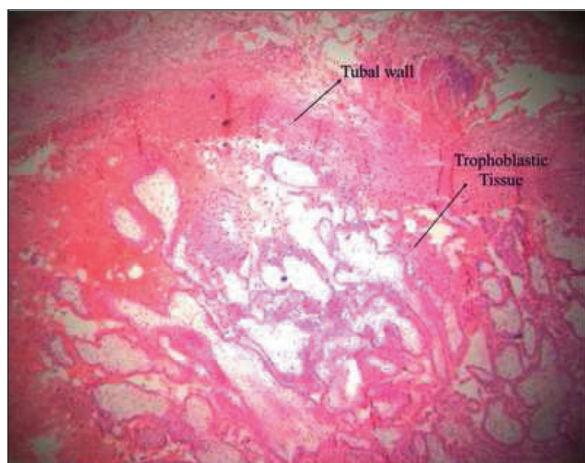


FIGURE 4: Histopathologic view of salpingectomy material.

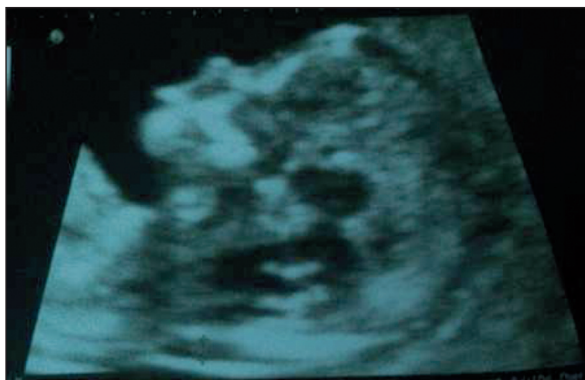

FIGURE 5: First Trimester Ultrasound assessment.

Clinical suspicion for the HP comes into forefront for diagnosing a heterotopic case.¹ Because of higher trophoblastic tissue by comparing to single

pregnancies increased b-hCG levels may be a good indicator for the clinical suspicion. Nevertheless, wide reference range for b-hCG levels detected in the gestational nomogram may impede with inspiring a suspicion to the clinician for differential diagnosis of HP.⁸ In the present case, the b-hCG values were compatible with a five-week pregnancy and this was correlated with the actual gestational week of the patient. Another indicator for suspecting HP may be the pelvic pain.⁹ In cases of heterotopic pregnancy, pelvic pain can be characterized by tubal tension and inflammation, but this pain may also be readily mistaken for the stretching pain arising from the growing uterus. In the absence of abdominal tenderness, it could become more difficult to have suspicion about pelvic pathology. In the present case abdominal examination was normal without creating pelvic pathology.

CL cysts may be a good indicator for the number of ovulation except for the monozygosity. During the early stages of pregnancy, carrying out an adnexal evaluation and determining the CL count by ultrasound can be an objective way for clinicians to confirm their suspicions of HP. In the present case study, the presence of more than one CL led us to suspect of HP. The early diagnosis was given us an opportunity to be manage by minimally invasive approach, besides may have an additive effect for continuing the on going intrauterine pregnancy. To the best of our knowledge, this is the

TABLE 1: Heterotopic cases diagnosis at the first trimester of the gestation.

Author	Risk factors	b-hCG value	Gestational age	Initial symptoms	Total visit number before diagnose	Treatment	Intrauterine pregnancy
Chadee et al. ⁴	Hospitalization for PID	146,864 mIU/mL	9 weeks and 4 days	Vaginal spotting, lower abdominal pain, and nausea	1	Laparotomy was performed	Termination of the intrauterine pregnancy on postoperative day fourteen
Chadee et al. ⁴	no	22995 mIU/mL	7 weeks and 6 days	Vaginal bleeding	3	Laparoscopic excision of left corneal ectopic pregnancy with mini-laparotomy for specimen retrieval	Dilation and curettage (D&C)
Fatema et al. ⁵	no	45,200 mIU/mL	9 weeks	Right lower quadrant, aching, continuous in nature, and associated with two vomiting episodes of clear fluid	2	Right salpingectomy and appendectomy via McBurney's incision	Discharged but had a miscarriage 12 days after the operation
Pratilas et al. ⁶	no	-	11 weeks and 5 days	Severe lower abdominal pain	2	Right oophorectomy via laparotomy	N/A
Peker et al. ⁷	IVF circle	-	11 weeks	Sudden-onset pain at the left groin	N/A	Laparoscopic cornual resection	C-section at 39 weeks

PID: Pelvic inflammatory disease, N/A: Not available, IVF: in vitro fertilization.

earliest case of HP has been diagnosed, treated and ended with live delivery.

CONCLUSION

Detecting an intrauterine pregnancy is usually the main reason for missing a case of HP during the early stages of pregnancy. HP is usually clinically diagnosed after tubal integrity has been disrupted. Following an ultrasound, the detection of more than one CL may be an objective initial sign of HP. This may also raise clinical suspicion of a possible HP, even in cases where an intrauterine pregnancy has been detected, which is the key point for the diagnosis. The early diagnosis may provide better management approaches and outcomes for the ongoing pregnancy. It could be beneficial to use a vaginal ultrasound for examining not only uterus but also both adnexal regions at the early pregnancy period.

Previously reported heterotopic pregnancy cases: initial symptoms and gestational week at the time of diagnosis and pregnancy outcomes are demonstrated.

Informed Consent

Informed consent was achieved from the patient.

Source of Finance

During this study, no financial or spiritual support was received neither from any pharmaceutical company that has a direct connection with the research subject, nor from a company that provides or produces medical instruments and materials which may negatively affect the evaluation process of this study.

Conflict of Interest

No conflicts of interest between the authors and / or family members of the scientific and medical committee members or members of the potential conflicts of interest, counseling, expertise, working conditions, share holding and similar situations in any firm.

Authorship Contributions

Idea/Concept: Ali Gemici; **Design:** Ali Gemici; **Auditing/Consultancy:** Metin M. Altay; **Data Collection and/or Processing:** Seval Yılmaz Ergani; **Analysis and/or Interpretation:** Ayşegül Alkılıç; **Source Search:** Ayşegül Alkılıç; **Writing Article:** Ali Gemici; **Critical Review:** Metin M. Altay; **Resources and Funding:** Ali Gemici; **Ingredients:** Metin M. Altay.

REFERENCES

1. Reece EA, Petrie RH, Sirmans MF, Finster M, Todd WD. Combined intrauterine and extrauterine gestations: a review. *Am J Obstet Gynecol.* 1983;146(3): 323-30. [\[Crossref\]](#)
2. Louis-Sylvestre C, Morice P, Chapron C, Dubuisson JB. The role of laparoscopy in the diagnosis and management of heterotopic pregnancies. *Hum Reprod.* 1997;12(5):1100-2. [\[Crossref\]](#) [\[PubMed\]](#)
3. Rabbani I, Polson DW. Heterotopic pregnancy is not rare. A case report and literature review. *J Obstet Gynaecol.* 2005;25(2):204-5. [\[Crossref\]](#) [\[PubMed\]](#)
4. Chadee A, Rezai S, Kirby C, Chadwick E, Gottimukkala S, Hamaoui A, et al. Spontaneous heterotopic pregnancy: dual case report and review of literature. *Case Rep Obstet Gynecol.* 2016;2016:2145937. [\[Crossref\]](#)
5. Fatema N, Al Badi MM, Rahman M, Elawdy MM. Heterotopic pregnancy with natural conception; a rare event that is still being misdiagnosed: a case report. *Clin Case Rep.* 2016;4(3):272-5. [\[Crossref\]](#) [\[PubMed\]](#) [\[PMC\]](#)
6. Pratilas GC, Chatzis P, Panteleris N, Chatzistamatiou K, Zeipiridis L, Dinas K. Concealed heterotopic pregnancy at 12 weeks, with no coexisting risk factors: lessons to be learned. *J Obstet Gynaecol Res.* 2017;43(1):228-31. [\[Crossref\]](#) [\[PubMed\]](#)
7. Peker N, Aydeniz EG, Gündoğan S, Şendağ F. Laparoscopic management of heterotopic istmocornual pregnancy: a different technique. *J Minim Invasive Gynecol.* 2017;24(1):8-9. [\[Crossref\]](#) [\[PubMed\]](#)
8. Braunstein GD, Rasor J, Danzer H, Adler D, Wade ME. Serum human chorionic gonadotropin levels throughout normal pregnancy. *Am J Obstet Gynecol.* 1976;126(6): 678-81. [\[Crossref\]](#)
9. Foxcroft KF, Callaway LK, Byrne NM, Webster J. Development and validation of a pregnancy symptoms inventory. *BMC Pregnancy Childbirth.* 2013;13:3. [\[Crossref\]](#) [\[PubMed\]](#) [\[PMC\]](#)