

## CASE REPORT

DOI: 10.5336/caserep.2021-87036

# A Hydroxychloroquine-Related Acute Severe Liver Disease

Kadir GİŞİ<sup>a</sup>, Murat İSPİROĞLU<sup>a</sup>, Emine KILINÇ<sup>b</sup><sup>a</sup>Department of Gastroenterology, Sütçü İmam University Faculty of Medicine, Kahramanmaraş, Türkiye<sup>b</sup>Department of Pathology, Sütçü İmam University Faculty of Medicine, Kahramanmaraş, Türkiye

**ABSTRACT** Drug-induced liver injury can develop depending on the drug itself, its metabolites or the host immune system. Hydroxychloroquine (HCQ) is used prevalently in the treatment of rheumatological diseases. Severe liver toxicities associated with HCQ have been rarely reported in the literature. We present the case of a 36-year-old female patient who was using HCQ due to adult Still's disease whose initial values were normal but arrived 3 weeks later with severely high liver enzyme and bilirubin levels. The diagnosis of acute severe liver disease due to HCQ use was made by eliminating other causes and conducting a liver biopsy. The patient recovered completely with steroid therapy. It should be kept in mind that HCQ, which was prevalently used worldwide at the beginning of the coronavirus disease-2019 pandemic, can lead to severe liver disease in rare cases.

**Keywords:** Hydroxychloroquine; liver disease; COVID-19

Drug-induced liver injury (DILI) is a complicated process involving the drug itself, its metabolites and the host immune system.<sup>1</sup> DILI is generally characterized by hepatocellular damage, but it may also induce cholestatic damage or mixed-type damage (containing both hepatocellular damage and cholestatic damage characteristics). DILI is generally characterized by hepatocellular damage, but it may also induce cholestatic damage or mixed-type damage (having both hepatocellular damage and cholestatic damage characteristics). Drug-induced hepatotoxicity may develop with intrinsic dose dependent (predictable) or idiosyncratic (unpredictable) mechanisms. Idiosyncratic reactions may also be immune or nonimmune. The antimalarial drug hydroxychloroquine (HCQ) is one of the prevalently prescribed drugs for the cutaneous and joint symptoms of autoimmune diseases. Additionally, it is a drug that is preferred in the second-step treatment of adult Still's disease (ASD). Although it was discon-

tinued recently, it was used in the treatment and prophylaxis of the coronavirus disease-2019 (COVID-19) in the initial period of the pandemic.<sup>2</sup> This drug has a high hepatic metabolism and broad distribution volume involving mainly the liver, spleen, kidneys, lungs, and melanin-containing tissues.<sup>3</sup>

In this article, we discuss a patient in whom acute severe liver disease developed due to the use of HCQ which is one of the popular drugs of the COVID-19 pandemic period.

## CASE REPORT

The 36-year-old female patient had complaints of jaundice and itching present for 10 days. The patient had been diagnosed with ASD at the rheumatology outpatient clinic 1 month before, and 200 mg/day HCQ treatment had been started. Her sclerae and skin had an icteric appearance in her physical examination, she had mild upper-right quadrant pain in her

**Correspondence:** Kadir GİŞİ

Department of Gastroenterology, Sütçü İmam University Faculty of Medicine, Kahramanmaraş, Türkiye

**E-mail:** kadirgisi@gmail.com



Peer review under responsibility of Türkiye Klinikleri Journal of Case Reports.

**Received:** 10 Nov 2021

**Received in revised form:** 27 Jan 2022

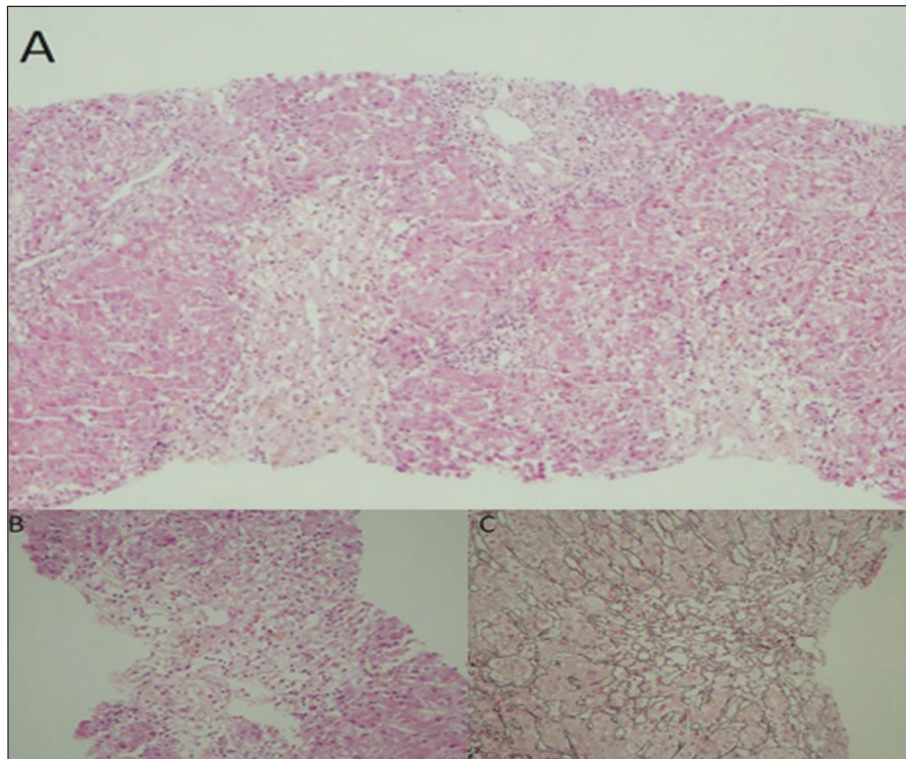
**Accepted:** 05 Feb 2022

**Available online:** 11 Feb 2022

2147-9291 / Copyright © 2022 by Türkiye Klinikleri. This is an open access article under the CC BY-NC-ND license (<http://creativecommons.org/licenses/by-nc-nd/4.0/>).

abdominal examination, and her other system examinations were natural. In the laboratory examinations of the patient, there were high values of international normalized ratio (INR): 1.25, aspartate aminotransferase: 693 U/L, alanine aminotransferase: 1,325 U/L, total bilirubin: 10.35 mg/dL, direct bilirubin: 9.26 mg/dL, alkaline phosphates: 135 U/L, gamma-glutamyl transferase: 200 IU/L, and lactate dehydrogenase: 497 U/L. The patient was hospitalized at the gastroenterology service with the pre-diagnosis of acute hepatitis. Serological tests were negative for hepatitis A, hepatitis B, hepatitis delta and hepatitis C. Moreover, cytomegalovirus, herpes simplex virus and Epstein-Barr virus serology test results were negative. The results of anti-mitochondrial antibody, anti-smooth muscle antibody, anti-liver-kidney microsomal antibody tests were also negative. She had no history of alcohol consumption. Abdominal ultrasonography and magnetic resonance cholangiography due to cholestasis were requested for the patient,

and the results came out normal. The patient was consulted to the rheumatology department regarding rheumatic involvement, but it was stated that the patient was in remission in terms of ASD, and she did not have any clinical and laboratory signs that would suggest other rheumatic diseases. As the pre-treatment laboratory values of the patient were normal, the case was firstly assessed as toxic hepatitis. It was thought that HCQ, whose use was stopped at the hospitalization of the patient at the clinic, was the drug that caused this situation (as she did not have a history of any other drug use). A liver biopsy was performed on the patient for pathological diagnostic purposes. In the follow-up, the patient had liver enzymes of over 1,000, total bilirubin: 22.3 and direct bilirubin: 19.69, the INR value of the patient rose to 1.95, and referral of the patient was considered by contacting the liver transplantation center. Meanwhile, the patient's pathology results came out, and in the lobular area, hydropic degeneration, edema, oc-



**FIGURE 1: A)** There are significant confluent necrosis associated with lobular and portal inflammation in the parenchyma (H&E, x100). **B)** This is area of confluent necrosis which hepatocytes are lost severely and replaced with lymphocytes, Kupffer cells and connective tissue around the central vein (H&E, x200). **C)** Reticulin staining around the area of confluent necrosis (Reticulin, x200).

casional rosette-like appearance, lymphocyte, occasional polymorphous leukocyte, 3-4 spotty necrosis in 10x magnification in the most abundant area and bridging confluent necrosis areas around the central vein, in the parenchyma and focal point were observed, and this was reported as compatible with acute toxic hepatitis (Figure 1). After the biopsy, by considering that the possible toxic effect was formed immunologically, the patient was started on methylprednisolone 40 mg/day treatment, and her laboratory values decreased dramatically in her follow-up. After 3 weeks, all values turned normal, and the steroid dose was stopped by gradual reduction. The patient who had been considered for referral to the liver transplantation center dramatically recovered after steroid treatment and was discharged.

The need for approval was waived by the Local Ethic Committee at the Sütçü İmam University, as this was a single-subject case report. Written informed consent was obtained from the patient for publication of this case report and any accompanying images.

### DISCUSSION

High liver enzyme levels are found mainly in the form of a mild-moderate increase in the transaminases in 65% of patients during the course of ASD. However, cases that developed acute liver failure have also been reported.<sup>4</sup> At first, it was thought that the ASD in our patient could have liver involvement, but this diagnosis was discarded after the rheumatology consultation. This was because it was reported that the patient was in laboratory-level and clinical remission in terms of ASD. Moreover, liver dysfunction in ASD frequently reflects underlying disease activity.<sup>5</sup> The serological tests of autoimmune hepatitis and viral hepatitis that could have caused the high bilirubin and liver enzyme levels in our patient turned out to be negative. The patient did not have a history of using nonsteroid anti-inflammatory drugs, antibiotics or herbal medications that could lead to toxic hepatitis. The fact that the blood values of the patient before starting HCQ were normal supported the possibility

**TABLE 1:** Main characteristics of patients who develop severe liver disease due to HCQ.

	Makin et al.		Giner Galvañ et al.	Abdel Gallil	This case
Age	27	16	26	28	36
Sex	Female	Female	Female	Female	Female
AST	-	544	399	745	693
ALT	2,575	-	285	987	1,325
Total bilirubin	9.5	24.3	-	-	10.35
INR	3.3	3.5	-	-	1.25
Post-treatment toxicity findings	After 2 weeks Nausea, vomiting, jaundice	After 2 weeks Jaundice, weakness	After 8-10 hours Nausea, vomiting, fever	After 1 year Nausea, vomiting, abdominal pain	After 3 weeks Jaundice, itching
HCQ dose of usage	2x200 mg	2x200 mg	1x200 mg	1x400 mg	1x200 mg
Disease	SLE	Juvenile Still's disease	Mixed connective tissue disease	SLE	Adult Still's disease
Treatment given	None	Liver transplantation	1x60 mg/day methyl prednisolone	Mycophenolate mofetil+10 mg/day prednisolone	Methyl prednisolone 40 mg/day
Liver biopsy	Performed	Performed	Not performed	Not performed	Performed
Outcome	Exitus	Exitus	Recovery	Recovery	Recovery

AST: Aspartate aminotransferase; ALT: Alanine aminotransferase; INR: International normalized ratio; HCQ: Hydroxychloroquine; SLE: Systemic lupus erythematosus.

of HCQ toxicity. HCQ is used worldwide in the prophylaxis and treatment of malaria, the treatment of rheumatoid arthritis, lupus erythematosus and ASD, in addition to being used for a period in the prophylaxis or treatment of COVID-19, although it has been recently stopped.<sup>2</sup> Albeit rarely, this drug is associated with hepatotoxicity, and it largely induces high liver enzyme values in relation to an idiosyncratic toxic effect. Until now, in the literature, a few severe liver injury cases associated with HCQ have been reported (Table 1).<sup>6-8</sup> Almost all of these cases had a mixed type of liver injury, as in our patient.

This case is the fifth case in the literature displaying acute severe hepatitis symptoms related to HCQ use. All previous patients were female, and their mean age was 26 (16-28). Among the previous 4 cases reported to have HCQ toxicity, two developed severe liver failure, while one died after liver transplantation, and the other died before transplantation.<sup>6-8</sup> Our patient was a woman at the age of 36. Furthermore, although nausea and vomiting were the main symptoms in most of the previous cases, there was no nausea or vomiting in our patient. She had a complaint of itching, which the other patients did not have. Considering the recovered cases, starting steroid treatment after stopping HCQ was important in normalizing the liver functions and enzymes in the patients. This was because while steroids play a role in the treatment of drug-induced hypersensitivity reactions, they also have an unproven benefit in most forms of drug-induced hepatotoxicity.<sup>9</sup> While we were thinking of referring our patient to the transplant center, we observed that

she recovered completely with the steroid treatment that we started.

In conclusion, it should be kept in mind that HCQ, which was prevalently used worldwide at the beginning of the COVID-19 pandemic, may lead to severe liver failure and even death, although such cases are rare. Calling patients who have started outpatient treatment in for polyclinic checkup regarding liver toxicity within the first ten days will allow the early detection of possible toxicity.

#### **Source of Finance**

*During this study, no financial or spiritual support was received neither from any pharmaceutical company that has a direct connection with the research subject, nor from a company that provides or produces medical instruments and materials which may negatively affect the evaluation process of this study.*

#### **Conflict of Interest**

*No conflicts of interest between the authors and / or family members of the scientific and medical committee members or members of the potential conflicts of interest, counseling, expertise, working conditions, share holding and similar situations in any firm.*

#### **Authorship Contributions**

**Idea/Concept:** Kadir Gişi; **Design:** Kadir Gişi, Emine Kılınç; **Control/Supervision:** Kadir Gişi, Murat İspiroğlu; **Data Collection and/or Processing:** Kadir Gişi, Emine Kılınç; **Analysis and/or Interpretation:** Kadir Gişi, Murat İspiroğlu; **Literature Review:** Kadir Gişi; **Writing the Article:** Kadir Gişi, Emine Kılınç; **Critical Review:** Murat İspiroğlu, Kadir Gişi; **References and Fundings:** Kadir Gişi; **Materials:** Kadir Gişi, Emine Kılınç.

## REFERENCES

1. Chen M, Suzuki A, Borlak J, Andrade RJ, Lucena MI. Drug-induced liver injury: Interactions between drug properties and host factors. *J Hepatol.* 2015;63(2):503-14. [[Crossref](#)] [[PubMed](#)]
2. Yao X, Ye F, Zhang M, Cui C, Huang B, Niu P, et al. In vitro antiviral activity and projection of optimized dosing design of hydroxychloroquine for the treatment of severe acute respiratory syndrome coronavirus 2 (SARS-CoV-2). *Clin Infect Dis.* 2020;71(15):732-9. [[Crossref](#)] [[PubMed](#)] [[PMC](#)]
3. Van Beek MJ, Piette WW. Antimalarials. *Dermatol Clin.* 2001;19(1):147-60, ix. [[Crossref](#)] [[PubMed](#)]
4. Gerfaud-Valentin M, Jamilloux Y, Iwaz J, Sève P. Adult-onset Still's disease. *Autoimmun Rev.* 2014;13(7):708-22. [[Crossref](#)] [[PubMed](#)]
5. Zhu G, Liu G, Liu Y, Xie Q, Shi G. Liver abnormalities in adult onset Still's disease: a retrospective study of 77 Chinese patients. *J Clin Rheumatol.* 2009;15(6):284-8. [[Crossref](#)] [[PubMed](#)]
6. Makin AJ, Wendon J, Fitt S, Portmann BC, Williams R. Fulminant hepatic failure secondary to hydroxychloroquine. *Gut.* 1994;35(4):569-70. [[Crossref](#)] [[PubMed](#)] [[PMC](#)]
7. Giner Galva- V, Oltra MR, Rueda D, Esteban MJ, Redón J. Severe acute hepatitis related to hydroxychloroquine in a woman with mixed connective tissue disease. *Clin Rheumatol.* 2007;26(6):971-2. [[Crossref](#)] [[PubMed](#)]
8. Abdel Galil SM. Hydroxychloroquine-induced toxic hepatitis in a patient with systemic lupus erythematosus: a case report. *Lupus.* 2015;24(6):638-40. [[Crossref](#)] [[PubMed](#)]
9. Giannattasio A, D'Ambrosi M, Volpicelli M, Iorio R. Steroid therapy for a case of severe drug-induced cholestasis. *Ann Pharmacother.* 2006;40(6):1196-9. [[Crossref](#)] [[PubMed](#)]