

# Successful Treatment of Corneal and Conjunctival Intraepithelial Neoplasia with Topical Interferon Alfa-2b: Case Report

## Korneal ve Konjonktival İntraepitelyal Tümörün Topikal İnterferon Alfa-2b ile Başarılı Tedavisi

Emine KALKAN AKÇAY,<sup>a</sup>  
Necati DURU,<sup>a</sup>  
Gamze DERELİ CAN,<sup>a</sup>  
Aydan KILIÇARSLAN,<sup>b</sup>  
Muhammed Bülent AKINCI,<sup>c</sup>  
Nurullah ÇAĞIL<sup>a</sup>

Departments of  
<sup>a</sup>Ophthalmology,  
<sup>b</sup>Pathology,  
<sup>c</sup>Medical Oncology,  
Yıldırım Beyazıt University  
Faculty of Medicine, Ankara

Geliş Tarihi/Received: 08.03.2014  
Kabul Tarihi/Accepted: 09.12.2014

Yazışma Adresi/Correspondence:  
Gamze DERELİ CAN  
Yıldırım Beyazıt University  
Faculty of Medicine,  
Department of Ophthalmology, Ankara,  
TÜRKİYE/TURKEY  
dereli\_gmz@hotmail.com

**ABSTRACT** Corneal and conjunctival intraepithelial neoplasia (CCIN) is a premalignant lesion of the corneal epithelium and limbus and the most common tumor of the ocular surface. Management of these lesions includes wide local excision followed by supplemental cryotherapy, and topical chemotherapy with antineoplastic drugs. As shown by past research, CCIN has a high recurrence rate after excision alone. Consequently, new chemotherapeutic agents have begun to be used in recent years to reduce the risk of recurrence in recent years. In this case, after a clinical and histopathological diagnosis of CCIN, an interferon alfa-2b (IFN  $\alpha$  2b) eye drop was prepared and used four times daily and complete tumor resolution was noted at the first year. We aimed to present our successful treatment of a case of CCIN with topical IFN  $\alpha$  2b.

**Key Words:** Conjunctiva; cornea; interferon alfa-2b; carcinoma in situ

**ÖZET** Korneal ve konjonktival intraepitelyal neoplazi (KKN) kornea epiteli ve limbusun premalign bir lezyonudur ve oküler yüzeyin en sık rastlanan tümördür. Bu lezyonun tedavisi geniş lokal eksizeyon ardından kriyoterapi ve kanser önleyici ilaçlar ile topikal kemoterapiyi içerir. Sadece eksizeyon sonrası KKN'nin yüksek rekürrens hızına sahip olduğu geçmiş çalışmalarda gösterilmiştir. Bu sebeple son yıllarda yeni kemoterapotik ajanlar rekürrensi azaltmak için kullanılmaya başlanmıştır. Bu olguda, KKN'nin klinik ve histopatolojik tanısının ardından, interferon alfa-2b (IFN alfa-2b) göz damlası hazırlandı, günde 4 kez kullanıldı ve tedavi sonrası birinci yılda tümoral lezyonun tamamen rezolüsyona uğradığı görüldü. Bu yazıda topikal IFN alfa-2b ile başarılı bir şekilde tedavi edilen KKN olgusunu sunmayı amaçladık.

**Anahtar Kelimeler:** Konjonktiva; kornea; interferon alfa-2b; in situ karsinom

**Türkiye Klinikleri J Ophthalmol 2015;24(1):46-9**

Corneal and conjunctival intraepithelial neoplasia (CCIN) is a premalignant lesion of the corneal epithelium and limbus and the most common tumor of the ocular surface.<sup>1</sup> Generally it occurs in the interpalpebral fissure, usually at the region of the limbus, although it may be found elsewhere.<sup>2</sup> The etiology of this disease is most likely multifactorial, involving such factors as age, ultraviolet light exposure, human papillomavirus, and human immunodeficiency virus. Management of these lesions includes wide local excision followed by supplemental cryotherapy, and topical chemotherapy with antineoplastic drugs. CCIN has been known to have a high recurrence rate after excision alone. Cryotherapy, radiation,

and chemotherapeutics have been used after excision to reduce recurrence rates. Mitomycin C (MMC) and 5-fluorouracil (5-FU) have been successfully employed against CCIN.<sup>3</sup> More recently, interferon alfa-2b (IFN  $\alpha$  2b) has been shown to be effective in treating CCIN.<sup>4</sup> In the present paper, a successfully treated CCIN patient with IFN  $\alpha$  2b eye drop after clinical and histopathological diagnosis was reported.

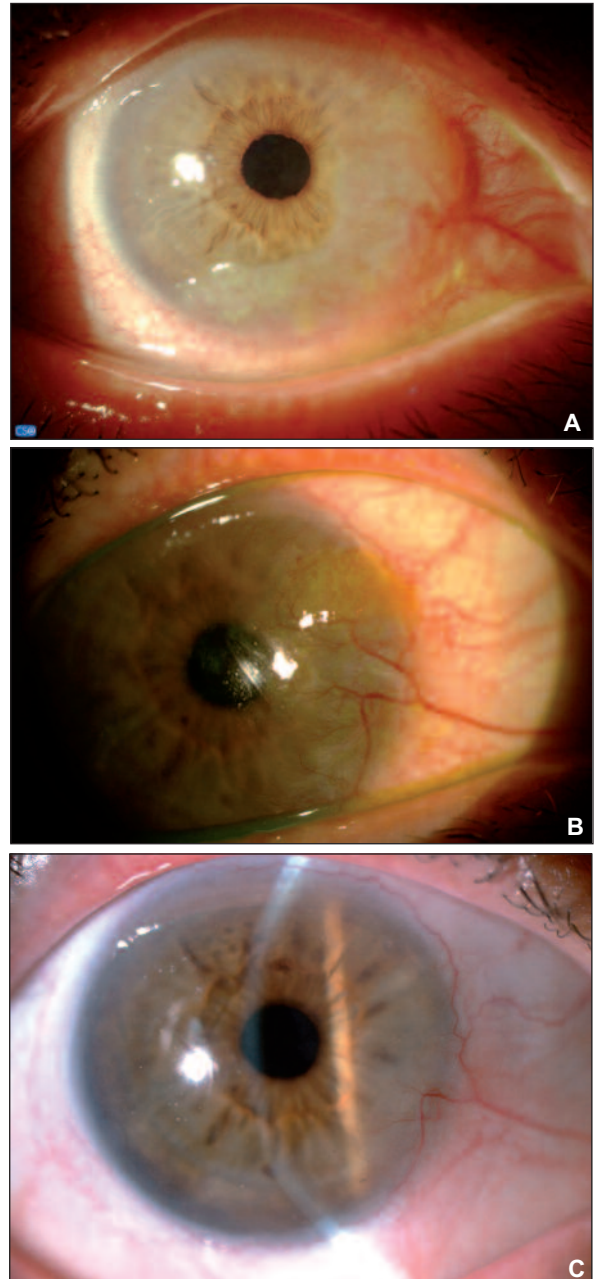
## CASE REPORT

A seventy-four year old female patient presented to our clinic with a three-month long history of foreign body sensation, redness, irritation, decreased visual acuity and rising tissue growth in her right eye. She had undergone surgery for retinal detachment in her left eye 10 years before. Best corrected visual acuity was 20/80 on the right eye and 20/1200 on the left eye.

Slit lamp examination revealed a 270-degree (from the 11 to 8-o'clock), gray gelatinous, slightly elevated neovascular tumorous lesion involving the conjunctiva, cornea, as well as the limbus on the right eye (Figure 1A). On examination of the left eye, wide scarring of conjunctiva as a complication of previous retinal detachment surgery, and posterior chamber intraocular lens (PC IOL) were noted.

On the basis of clinical findings, an initial diagnosis of CCIN was made in the right eye and a complete excision of lesion was planned. However, due to the high risk ratio of limbal stem cell deficiency (LSCD) after such a wide local excision for complete lesion removal with no option of left conjunctival autograft because of scarring, we changed our plans and an incisional biopsy was performed from the superonasal of the limbus, which confirmed the diagnosis of CCIN histopathologically (Figure 2A). Therefore, we decided to apply medical treatment instead of surgery. Written informed consent was obtained from the patient according to the Tenets of the Declaration of Helsinki after an explanation of all the treatment options. A single therapeutic agent, topical IFN  $\alpha$  2b 1 million IU/mL was prepared, and was instilled four times

daily; this regimen continued until complete disappearance had occurred. She was followed up one day, one week, one month, four months, six months, twelve months, and fifteen months after treatment. Topical therapy was generally well tol-



**FIGURE 1:** A. 270-degree (from the 11 to 8-o'clock) gray, gelatinous, slightly elevated neovascular tumorous lesion involving the conjunctiva, cornea, as well as the limbus. B. Regression of CINN was noted at 4th month of treatment. C. Total resolution of CINN was noted at first year of the treatment.

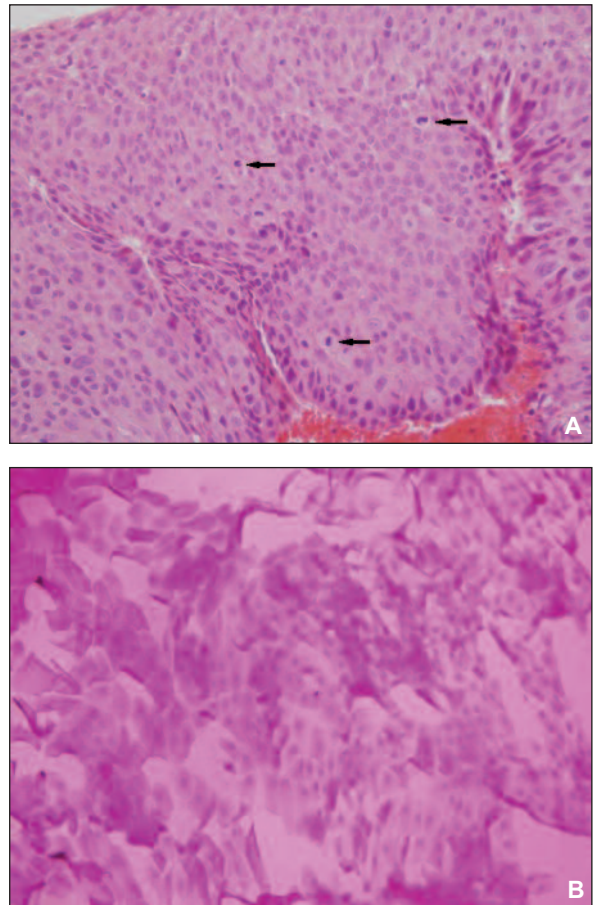
CINN: Corneal and conjunctival intra epithelial neoplasia.

(See color figure at <http://www.turkiyeklinikleri.com/journal/oftalmoloji-dergisi/1300-0365/>)

erated with the exception of the development of punctate epitheliopathy developed at the 2nd month of the treatment, which was relieved by preservative-free lubricants. No other side-effects except punctate epitheliopathy were detected. Regression of CCIN was noted during the 4th month of treatment (Figure 1B). Therapy was discontinued after regression of the lesion. Total resolution of CCIN was noted at the first year of treatment, although limbal vascularization was present at 4-o'clock (Figure 1C). Incisional biopsy was performed from the superior, inferior, and nasal limbal region of the right eye to confirm total resolution. No tumor cells were found in the biopsy. No recurrence has been observed yet at the 1.5 years' follow up, while the limbal vascularization at 4-o'clock remained. Impression cytology was performed including the superior, inferior, and nasal limbal region of the right eye to confirm a total cure histopathologically in the final examination. Benign conjunctival and corneal epithelial cells were reported in the impression cytology (Figure 2B). We suppose that the vascularization depends on LSCD in that area.

## DISCUSSION

Conjunctival and corneal intraepithelial neoplasia is a precancerous lesion of the ocular surface, which is slowly progressive with low malignant potential.<sup>5</sup> Although CCIN is a slow-growing tumor, appropriate treatment is important due to the potential for local invasion or metastasis to regional lymph nodes. Traditionally, treatment of CCIN is a wide local surgical excision combined with cryotherapy, despite the risk for recurrence. The existence of excision margins at the time of surgery is the most important predicting factor in recurrence rate. In addition, determining the edges and deep margins of the mass during the operation is too difficult. Recent studies have shown that the recurrence rate is approximately 50% when pathological evidence of residual tumor cells in the surgical margins exist, and 5% to 33% when clear margins are found.<sup>6,7</sup> Due to the high recurrence rates, adjunctive medical interventions for CCIN, such as MMC, 5-FU, and IFN  $\alpha$  2b, have been proposed. These thera-



**FIGURE 2:** A. A large number of significant atypia and mitotic figures in the squamous epithelium of the conjunctiva, incisional biopsy, H/E X40. B. Benign conjunctival and corneal epithelial cells, impression cytology, H/E X40.

(See color figure at <http://www.turkiyeklinikleri.com/journal/oftalmoloji-dergisi/1300-0365/>)

peutic agents act as an anti-tumor substance. 5-FU is a pyrimidine analog and works as a irreversible inhibitor of thymidylate synthase. MMC is a chemotherapeutic agent which has an antibiotic activity against the tumor cells. IFN  $\alpha$  2b utilizes intracellular signaling pathway and controls the cell cycle, cell differentiation, apoptosis, and immune response.<sup>3,8</sup> IFN  $\alpha$  2b eye drops are generally well-tolerated and have minimal side effects. On the contrary, MMC eye drops usually cause epithelial toxicity, reactive conjunctivitis, photophobia and severe discomfort. Several reports have also confirmed the clinical efficacy of topical 5-FU in the treatment of CCIN, although its side-effect profile is worse than IFN  $\alpha$  2b.<sup>8</sup> In this case, we decided to use topical IFN  $\alpha$  2b as a single therapy for primary CCIN based on the reported success of topical IFN

$\alpha$  2b for CCIN. This decision was also based on the fact that, as shown in the literature, IFN  $\alpha$  2b has a better side-effect profile and less toxicity.<sup>9</sup> To the best of our knowledge, this is the first reported case of CCIN which was treated only with topical IFN  $\alpha$  2b therapy in Turkey. Interferon therapy was approved by the United States Food and Drug Administration (FDA) for the treatment of many cancers such as hairy cell leukemia, malignant melanoma, hepatocellular carcinoma, cervical neoplasia, multiple myeloma, follicular lymphoma, chronic hepatitis B and C, condyloma acuminata and AIDS related kaposi sarcoma.<sup>3</sup> Despite the off-label use of topical IFN  $\alpha$  2b, it has been reported in several publications to be successful in achieving tumor control with a dosage of one million IU/mL four times daily on the ocular surface.<sup>10-13</sup> For using this off-label drug, approval was obtained from "The General Directorate of Pharmaceuticals and Pharmacy" in Turkey.

Schechter et al. reported that 28 eyes of 26 CCIN patients had been treated with topical IFN  $\alpha$  2b. Twenty-seven patients had complete resolution; one patient had recurrence after therapy stopped.<sup>12</sup> Likewise, Boehm et al. reported that of the seven patients with recurrent CCIN who had

been treated with topical IFN  $\alpha$ -2b, two patients had a recurrence of CCIN, noted at one year and two months, respectively.<sup>14</sup> In these studies, a wide range of duration-such as a two-to-24-month time frame-is required for complete resolution. Although the reason remains unclear, researchers continued on this anti-tumor medical treatment several months after resolution. This decision was probably dependent upon the subjective experiences of specialists in various cases.<sup>11-13</sup> In our case, the single IFN  $\alpha$  2b therapy was stopped after we had seen that there was no CCIN did not appear in slit lamp examination and after confirmation of total cure with impression cytology in the final examination.

In conclusion, treatment of CCIN with IFN  $\alpha$  2b is effective, valuable and safe with a low recurrence rate. When compared to surgical excision, this treatment is more reliable because of the non-invasive nature. Furthermore, IFN  $\alpha$  2b is less likely to induce devastating complications such as LSCD on the ocular surface. Additionally, it seems to have less ocular surface toxicity when compared to other topical chemotherapeutic agents.<sup>9,11-14</sup> Based on our experience, IFN  $\alpha$  2b is an effective approach in the treatment of CCIN.

## REFERENCES

- Nelson KD, McSoley JJ. Clinical findings and management of conjunctival intraepithelial neoplasia. *Optometry* 2011;82(1):15-21.
- Prabhasawat P, Tarinvorakup P, Tesavibul N, Uprasertkul M, Kosrirukvongs P, Booranapong W, et al. Topical 0.002% mitomycin C for the treatment of conjunctival-corneal intraepithelial neoplasia and squamous cell carcinoma. *Cornea* 2005;24(4): 443-8.
- Giaconi JA, Karp CL. Current treatment options for conjunctival and corneal intraepithelial neoplasia. *Ocul Surf* 2003;1(2):66-73.
- Fernandes BF, Nikolitch K, Coates J, Novais G, Odashiro A, Odashiro PP, et al. Local chemotherapeutic agents for the treatment of ocular malignancies. *Surv Ophthalmol* 2014; 59(1):97-114.
- Kao AA, Galor A, Karp CL, Abdelaziz A, Feuer WJ, Dubovy SR. Clinicopathologic correlation of ocular surface squamous neoplasms at Bascom Palmer Eye Institute: 2001 to 2010. *Ophthalmology* 2012;119(9):1773-6.
- Anne Vollmar A, De La Torre D, Schmiiedecke S. Use of interferon alpha b2 in treatment of corneal-conjunctival intraepithelial neoplasia. *Optometry* 2009; 80(6):299-300.
- Saraj G. Corneal and conjunctival intraepithelial neoplasia-A case report. *People's Journal Scientific Research* 2010;3(2):31-2.
- Huerva V, Mangues I. Treatment of conjunctival squamous neoplasias with interferon alpha 2ab. *J Fr Ophthalmol* 2008;31(3): 317-25.
- Nanji AA, Sayyad FE, Karp CL. Topical chemotherapy for ocular surface squamous neoplasia. *Curr Opin Ophthalmol* 2013;24(4): 336-42.
- Majewski S, Szmurlo A, Marczak M, Jablonska S, Bollag W. Synergistic effect of retinoids and interferon alpha on tumor-induced angiogenesis: anti-angiogenic effect on HPV-harboring tumor-cell lines. *Int J Cancer* 1994; 57(1):81-5.
- Galor A, Karp CL, Chhabra S, Barnes S, Alfonso EC. Topical interferon alpha 2b eye-drops for treatment of ocular surface squamous neoplasia: a dose comparison study. *Br J Ophthalmol* 2010;94(5):551-4.
- Schechter BA, Koreishi AF, Karp CL, Feuer W. Long-term follow-up of conjunctival and corneal intraepithelial neoplasia treated with topical interferon alpha-2b. *Ophthalmology* 2008;115(8):1291-6, 1296.e1.
- Sturges A, Butt AL, Lai JE, Chodosh J. Topical interferon or surgical excision for the management of primary ocular surface squamous neoplasia. *Ophthalmology* 2008;115(8):1297-302, 1302.e1.
- Boehm MD, Huang AJ. Treatment of recurrent corneal and conjunctival intraepithelial neoplasia with topical interferon alpha 2b. *Ophthalmology* 2004;111(9):1755-61.