

# The Association Between Uveitis and Familial Mediterranean Fever: Coincidence or Association?

## Üveit ve Ailesel Akdeniz Ateşi Arasındaki İlişki: Rastlantı mı İlişki mi?

Mustafa KÖŞKER,<sup>a</sup>  
Osman ÇELİKAY,<sup>a</sup>  
Sinan ÇALIŞKAN,<sup>a</sup>  
Tolga BİÇER,<sup>a</sup>  
Cem ÖZİŞLER,<sup>b</sup>  
Ferda ALPASLAN PINARLI,<sup>c</sup>  
Canan GÜRDAL<sup>a</sup>

Clinics of

<sup>a</sup>Ophthalmology,

<sup>b</sup>Rheumatology,

<sup>c</sup>Genetic Diagnostic Center,

Dışkapı Yıldırım Beyazıt Training and

Research Hospital,

Ankara

Received: 23.09.2017

Received in revised form: 26.11.2017

Accepted: 14.12.2017

Available online: 25.10.2018

Correspondence:

Mustafa KÖŞKER

Dışkapı Yıldırım Beyazıt

Training and Research Hospital,

Clinic of Ophthalmology, Ankara,

TURKEY/TÜRKİYE

mustafakosker0@gmail.com

**ABSTRACT Objective:** To evaluate the association between uveitis and Familial Mediterranean Fever (FMF). **Material and Methods:** This retrospective study was performed to evaluate the prevalence of uveitis in patients with FMF referred to Genetic Diagnostic Center at Dışkapı Yıldırım Beyazıt Training and Research Hospital from June 2011 to June 2015. We included all 132 patients with FMF. **Results:** Four of the 132 patients with FMF had uveitis. Three of the 4 patients had anterior uveitis, and 1 had posterior uveitis. One of the patients with anterior uveitis also had a history of recurrent episcleritis. All 4 patients with FMF and uveitis have been on Colchicine. Two of the 29 patients (6,9%) with a heterozygous mutation (E148 and M694V), 1 of the 35 patients (2,9%) with a homozygous mutation (M694V/M694V), 1 of the 51 patients (2%) with a compound heterozygous mutation (M694V/M680I) had uveitis. None of the 17 patients without a Mediterranean fever (MEFV) gene mutation had uveitis. The prevalence of uveitis in the FMF patients (3,1%) was significantly higher than the highest prevalence of uveitis reported in the literature (0,12%). In our study, FMF was a predisposing factor in the development of uveitis [odds ratio: 26 (95% CI: 8,3-81,3)], especially in patients with M694V mutations [odds ratio: 33,8 (95% CI: 9,3-122,1)]. Although 2 of the 4 patients with uveitis had hypertension and asthma, none had any systemic diseases predisposing to uveitis. **Conclusion:** MEFV gene mutations, particularly in M694V mutations, may be a predisposing factor in the development of uveitis.

**Keywords:** Familial mediterranean fever; uveitis; inflammation; M694V

**ÖZET Amaç:** Üveit ve Ailesel Akdeniz Ateşi (AAA) arasındaki ilişkiyi değerlendirmek. **Gereç ve Yöntemler:** Bu retrospektif çalışma Haziran 2011 ile Haziran 2015 arasında Dışkapı Yıldırım Beyazıt Eğitim ve Araştırma Hastanesi Genetik Tanı Merkezine yönlendirilen AAA hastalarındaki üveit prevalansını değerlendirmek için yapıldı. AAA hastalığı olan 132 hasta çalışmaya dahil edildi. **Bulgular:** AAA hastalığı olan 132 hastanın 4'ünde üveit vardı. Dört hastanın 3'ünde ön üveit, 1'inde arka üveit vardı. Ön üveitli hastalardan birinde de tekrarlayan episiklerit vardı. Üveiti olan 4 AAA hastası da kolşisin tedavisi almaktaydı. Heterozigot mutasyonu olan 29 hastanın 2'sinde (%6,9) (E148 and M694V), homozigot mutasyonu olan 35 hastanın 1'inde (%2,9) (M694V/M694V), compound heterozigot mutasyonu olan 51 hastanın 1'inde (%2) (M694V/M680I) üveit saptandı. Akdeniz ateşi (MEFV) gen mutasyonu olmayan AAA'lı hastaların hiçbirinde üveit saptanmadı. AAA hastalarındaki üveit prevalansı (%3,1) literatürde rapor edilen en yüksek üveit prevalansından (%0,12) anlamlı olarak yüksek bulundu. Çalışmamızda AAA üveit gelişimi için bir risk faktörü olarak bulundu [odds ratio: 26 (%95 GA: 8,3-81,3)]. M694V mutasyonu bulunan AAA hastalarında üveit riskinin daha da arttığı görüldü [odds ratio: 33,8 (%95 GA: 9,3-122,1)]. Üveiti bulunan 4 hastanın 2'sinde hipertansiyon ve astım bulunmasına rağmen hiçbir hastada üveite neden olabilecek sistemik bir hastalığa rastlanmadı. **Sonuç:** MEFV gen mutasyonları, özellikle M694V bölgesindekiler, üveit gelişiminde bir risk faktörü olabilir.

**Anahtar Kelimeler:** Ailesel akdeniz ateşi; üveit; inflamasyon; M694V

Uveitis is a common extra-articular sign of many systemic inflammatory diseases such as Behcet's disease or ankylosing spondylitis.<sup>1,2</sup> While it is not clear how these systemic diseases predispose to ocular inflammation, it has been recently hypothesized that IL-1 $\beta$  might have a role in the pathogenesis of eye and joint disease.<sup>3</sup>

The pyrin protein, which is coded by Mediterranean fever (MEFV) gene, reduces the activation of IL-1B by inhibiting the catalytic activity of caspase-1. Because the pyrin interaction with caspase-1 decreases in the presence of the MEFV mutations, mutations associated with Familial Mediterranean Fever (FMF) might reduce the inhibitor effect of the pyrin on the interleukin (IL)-1B activation, and thus IL-1B becomes more active than usual.<sup>4</sup>

Based on that IL-1B might have an important role in the pathogenesis of both uveitis and FMF disease, the purpose of our study is to investigate the prevalence of uveitis in patients with FMF in order to consider whether MEFV gene mutations might be a predisposing factor in the development of uveitis.

## MATERIAL AND METHODS

This retrospective study was performed to be able to examine the prevalence of uveitis in patients with FMF seen at Genetic Diagnostic Center in Dışkapı Yıldırım Beyazıt Training and Research Hospital from June 2011 to June 2015. A retrospective chart review of the health records was conducted in patients with FMF in August 2016. The study was approved by the ethics committee of Dışkapı Yıldırım Beyazıt Training and Research Hospital and conducted in accordance with the tenets of the Declaration of Helsinki. Written informed consent was obtained from all subjects.

The inclusion criteria for potential subjects with FMF were a diagnosis of FMF made according to MEFV gene sequencing and clinical criteria<sup>5</sup> by genetic specialists (F.A.P.) and a rheumatologist (C.O.). The diagnosis of uveitis was made according to the signs on slitlamp examination by the ophthalmologists (M.K., S.C., O.C. and C.G.). We excluded the patients who have comorbidities which might lead to uveitis.

We examined the best-corrected visual acuity (BCVA), intraocular pressure, anterior and posterior segment of the eye. Routine laboratory evaluation consisted of a complete blood count with differential, biochemical analysis, urinalysis, and erythrocyte sedimentation rate, antinuclear antibody, rheumatoid factor, C-reactive protein, human leukocyte antigen typing, angiotensin-converting enzyme, pathergy test, skin tuberculin test, chest radiography, syphilis, toxoplasma, herpes, and Lyme serology were done in FMF patients with uveitis to be able to exclude the other probable etiologies. Standardization of Uveitis Nomenclature working group criteria was used for classification of anatomic location.<sup>6</sup> Anatomically, uveitis was classified as anterior, intermediate, posterior, or panuveitis.

We included all 132 patients with FMF seen in the Genetic Diagnostic Center from June 2011 to June 2015. We also compared the prevalence of uveitis in the FMF group (3%) with the highest prevalence of uveitis reported in the literature to be able to understand whether FMF is a predisposing factor for the development of uveitis.

## MEFV GENE SEQUENCING

MEFV Gene Sequencing was performed as described in a previous study.<sup>7</sup> Genomic DNA was extracted from the blood samples of the all subjects using a DNA Isolation Kit for Mammalian Blood (Roche Diagnostics, Indianapolis, IN). The exons 2 and 10 of the MEFV gene and flanking regions of these exons were amplified by the polymerase chain reaction (PCR) by using a specific primer set. Sequencing of amplicons was performed on an ABI Prism 3130XL Genetic Analyzer (ABI Applied Biosystems, Foster City, CA) by using the ABI BigDye Terminator Cycle Sequencing Kit v3.1 (ABI Applied Biosystems, Foster City, CA) according to the manufacturer's instructions.

## STATISTICAL ANALYSIS

Data analysis was performed using Number Cruncher Statistical System (NCSS), 2007 Statistical Software (Utah). Qualitative data were analyzed by Pearson  $\chi^2$  and Fisher exact tests. Odds ratio and

95% confidence intervals (CI) were also calculated. P value lower than 0.05 was considered statistically significant.

## RESULTS

Eighty two of the patients were female and 50 were male. Four of the 132 patients with FMF had uveitis. While the mean age of 4 patients with uveitis was 49.8 years (range, 48-55), that of 132 patients without a history of uveitis was 37.0 (range, 5-67) ( $p<0.001$ ) (Table 1). Three of the 4 patients had anterior uveitis, and 1 had posterior uveitis (Figure 1). One of the patients with anterior uveitis also had a history of recurrent episcleritis (Table 2). All 4 patients with uveitis had unilateral involvement. All 4 patients with FMF and uveitis have been on Colchicine for a mean of 5.6 years (range, 6 months - 12 years) and have had clinical signs of FMF for 24 years (range, 1-47 years) (Table 1).

Of 132 patients with FMF, 51 had a compound heterozygous mutation, 35 had a homozygous mutation, and 29 had a heterozygous mutation. Seventeen of 132 patients had no MEFV gene mutation (Table 3). Two of the 29 patients (6,9%) with a heterozygous mutation (E148 and M694V), 1 of the 35 patients (2,9%) with a homozygous mutation (M694V/M694V), 1 of the 51 patients (2%) with a compound heterozygous mutation (M694V/M680I) had uveitis (Table 2). None of the 17 patients with-

out a MEFV gene mutation had uveitis. Although 2 of the 4 patients with uveitis had hypertension and asthma, none had any systemic diseases predisposing to uveitis.

The prevalence of uveitis in the FMF group (3.1%) was significantly higher than the highest prevalence of uveitis reported in the literature (0.12%) ( $P<0.001$ ).<sup>8</sup> According to our results, FMF was a predisposing factor in the development of uveitis [odds ratio: 26 (95% CI: 8.3 - 81.3)], especially in patients with M694V mutations [odds ratio: 33.8 (95% CI: 9.3- 122.1)] ( $p<0.0001$ ).

Three patients with active anterior uveitis were treated with tropicamide and topical steroids in addition to their ongoing oral colchicine treatment. The uveitis was in remission in the patient with posterior uveitis and we did not start any medication in addition to his ongoing oral colchicine treatment.

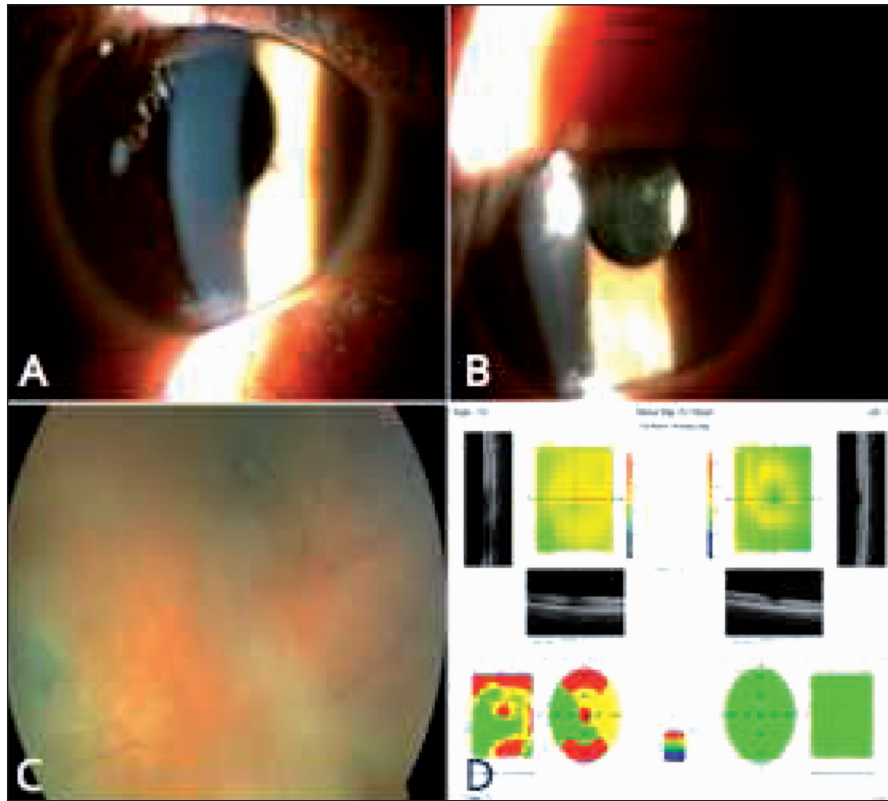
## DISCUSSION

Uveitis is a common extra-articular manifestation of many inflammatory diseases involving the joints. While IL-1 is one of the cytokines in pathogenesis of arthritis, it is not clear what the exact influence of it in the development of uveitis. It has been recently implicated IL-1 in the pathogenesis of uveitis.<sup>3</sup> In the pathophysiology, a mutation of the MEFV gene disrupts the function of pyrin protein, which has an autoregulatory effect in inflammatory processes.<sup>4</sup> Based on that IL-1B might

**TABLE 1:** Demographic and general properties of the uveitic patients with familial mediterranean fever (FMF).

Case no	Age/Sex (year)	Eye	Diagnosis duration of FMF (year)	Complaint duration of FMF (year)	Genetic mutation	Duration of Colchicine therapy (year, dose)	Comorbidities
Case 1	55/ F	L	12	42	M694V/M680I Compound heterozygote	12 (4x1)	Hypertension and asthma
Case 2	50/F	R	1	9	M694V/M694V Homozygote	1 (3x1)	Hypertension and asthma
Case 3	48/M	R	9	44	E148 Heterozygote	9 (2x1)	-
Case 4	50/F	L	0.5	1	M694V Heterozygote	0.5 (2x1)	-

F: Female, M: Male, L: Left, R: Right.



**FIGURE 1:** Pseudophakia and posterior capsule opacification **A, B**); retinal vascular sheathing and inactive retinal scar in the peripheral inferior temporal fundus in the right eye of case 3 **C**); Retina map of the right and left eye of the case 3 **D**).

Case no	Type of Uveitis	BCVA (R/L)	Bio	IOP (mmHg)	F
Case 1	Anterior	1.0/0.5	Medium-sized keratic precipitates on the inferior aspect of the corneal endothelium, 3+ cells in the anterior chamber, fix dilated pupil, posterior synechia, posterior subcapsular cataract in LE	13.9/16.7	Normal
Case 2	Anterior	1.0/1.0	2+ cells in the anterior chamber, posterior synechia in RE	11.2/13.2	Normal
Case 3	Posterior	0.1/1.0	Pseudophakia and posterior capsule opacification in RE	13.2/12.1	3 (+) vitritis (sequela) cellophane maculopathy, retinal vascular sheathing and inactive retinal scar in the peripheral inferior temporal fundus
Case 4	Anterior /Episcleritis	1.0/1.0	1+ cells in the anterior chamber and episcleritis in LE	16.2/15.4	Normal

BCVA: Best corrected visual acuity, R: Right, RE: Right eye, L: Left, LE: Left eye, IOP: Intra ocular pressure.

have an important role in the pathogenesis of both uveitis and FMF disease, we investigate the association between FMF and uveitis. Our study is first to examine the association between uveitis and FMF by evaluating the prevalence of uveitis in patients with FMF.

Ocular findings have rarely been reported in FMF. Firstly, Michaelson et al. has reported retinal colloid bodies in a patient with FMF.<sup>9</sup> Then, episcleritis in 4 cases, panuveitis in 2 cases, and anterior uveitis in 2 cases have been reported up to now.<sup>9-12</sup> In our study, 4 of the 132 patients with FMF had

**TABLE 3:** Detected mediterranean fever gene mutations in patients with familial mediterranean fever.

Compound Heterozygote	N	Homozygote Mutations	N	Heterozygote Mutation	N	Mutation Negative
M694V/M680I	21	M694V/M694V	22	M694V	14	
M694V/E148Q	11	M680I/M680I	5	E148Q	9	
M694V/V726A	9	V726A/V726A	5	M680I	3	
G304R/M680I	3	E148Q/E148Q	3	V726A	2	
M680I/V726A	4			R761H	1	
Other mutations	3					
Total	51		35		29	17

uveitis. Three of the 4 patients had anterior uveitis, and 1 had posterior uveitis. One of the patients with anterior uveitis also had a history of recurrent episcleritis.

Reported prevalence of uveitis in the literature was between 0.06% and 0.12%.<sup>8,13</sup> Prevalence of FMF ranges from 1:200 to 1:1000.<sup>14</sup> When compared the prevalence of uveitis in the FMF group (3.1%) with the highest prevalence of uveitis reported in the literature (0.12%), the prevalence of uveitis in the FMF group was still statistically significantly higher than that reported previously.<sup>8</sup> It has been reported that M694V and M680I mutations were the most common mutations in patients with FMF as in our study.<sup>14</sup> In the present study, 2 patients with uveitis and FMF had a heterozygous mutation (M694V and E148 in 1 case each), 1 had a compound heterozygous mutation (M694V/-M680I) and 1 had homozygous mutation (M694V/-M694V). According to our results, FMF was a predisposing factor in the development of uveitis, especially in patients with M694V mutations. M694V mutations have been found to be associated with more severe forms of the disease and higher frequencies of arthritis.<sup>15,16</sup> In harmony with that, 3 of 4 patients who developed uveitis in our study had a M694V mutation.

Systemic investigation of the uveitis etiology did not also reveal any disorder except FMF. Two of the 4 patients with uveitis and FMF had hypertension and asthma. Our hypothesis is supported by the fact that the patients with uveitis did not have any diagnosed systemic diseases other than

FMF, which may lead to uveitis. It was also interesting that the mean complaint duration of FMF was 43 years in 2 patients with severe ocular sequela (case 1 and 3) and 5 years in other 2 patients without any severe ocular sequela (case 2 and 4). We feel that the total exposure time to inflammation in FMF patients might affect the severity of the uveitis.

As a result, our study is the first to describe an association between uveitis and MEFV gene mutations. According to our results, inflammation may tend to develop uveitis in patients with FMF. We hypothesize that MEFV gene mutations leading to IL-1B activation may be a predisposing factor in the development of uveitis and IL-1B might have a crucial role in the pathogenesis of both FMF and uveitis. Thus, all FMF patients should have routine eye exams. More researches including more patients are required to further understand the association between uveitis and FMF.

#### Source of Finance

*During this study, no financial or spiritual support was received neither from any pharmaceutical company that has a direct connection with the research subject, nor from a company that provides or produces medical instruments and materials which may negatively affect the evaluation process of this study.*

#### Conflict of Interest

*No conflicts of interest between the authors and / or family members of the scientific and medical committee members or members of the potential conflicts of interest, counseling, expertise, working conditions, share holding and similar situations in any firm.*



**Authorship Contributions**

**Idea/Concept:** Mustafa Köşker; **Design:** Mustafa Köşker, Osman Çelikay; **Control/Supervision:** Mustafa Köşker, Canan Gürdal; **Data Collection and / or Processing:** Mustafa Köşker, Osman Çelikay, Sinan Çalıřkan, Tolga Biçer, Cem Öziřler, Ferda Alpaslan Pınarlı; **Analysis and / or Comment:** Mustafa Köşker, Osman

Çelikay, Sinan Çalıřkan, Tolga Biçer; **Reference Screen:** Mustafa Köşker; **Complete Writing:** Mustafa Köşker, Osman Çelikay, Sinan Çalıřkan, Tolga Biçer; **Critical Investigation:** Mustafa Köşker, Cem Öziřler, Ferda Alpaslan Pınarlı; **Resources and Fund Providing:** Ferda Alpaslan Pınarlı, Canan Gürdal; **Materials:** Cem Öziřler, Ferda Alpaslan Pınarlı.

## REFERENCES

1. Robinson PC, Leo PJ, Pointon JJ, Harris J, Cremin K, Bradbury LA, et al. The genetic associations of acute anterior uveitis and their overlap with the genetics of ankylosing spondylitis. *Genes Immun* 2016;17(1):46-51.
2. Ozyazgan Y, Ucar D, Hatemi G, Yazici Y. Ocular involvement of Behçet's syndrome: a comprehensive review. *Clin Rev Allergy Immunol* 2015;49(3):298-306.
3. Planck SR, Woods A, Clowers JS, Nicklin MJ, Rosenbaum JT, Rosenzweig HL. Impact of IL-1 signalling on experimental uveitis and arthritis. *Ann Rheum Dis* 2012;71(5):753-60.
4. Chae JJ, Wood G, Masters SL, Richard K, Park G, Smith BJ, et al. The B30.2 domain of pyrin, the familial Mediterranean fever protein, interacts directly with caspase-1 to modulate IL-1beta production. *Proc Natl Acad Sci U S A* 2006;103(26):9982-7.
5. Livneh A, Langevitz P, Zemer D, Zaks N, Kees S, Lidar T, et al. Criteria for the diagnosis of familial Mediterranean fever. *Arthritis Rheum* 1997;40(10):1879-85.
6. Bloch-Michel E, Nussenblatt RB. International Uveitis Study Group recommendations for the evaluation of intraocular inflammatory disease. *Am J Ophthalmol* 1987;103(2):234-5.
7. Kosker M, Arslan N, Alp MY, Ozisler C, Acar M, Dogan AS, et al. Association between keratoconus and familial Mediterranean fever in Turkey. *Cornea* 2016;35(1):77-80.
8. Gritz DC, Wong IG. Incidence and prevalence of uveitis in Northern California; the Northern California Epidemiology of Uveitis Study. *Ophthalmology* 2004;111(3):491-500.
9. Michaelson I, Eliakim M, Ehrenfeld EN, Rachmilewitz M. Fundal changes resembling colloid bodies in recurrent polyserositis (periodic disease). *AMA Arch Ophthalmol* 1959;62(1):1-4.
10. Berestitschevsky S, Weinberger D, Avisar I, Avisar R. Episcleritis associated with familial Mediterranean fever. *Isr Med Assoc J* 2008;10(4):318-9.
11. Akman A, Varan B, Akova YA, Aydin P. Ocular involvement in siblings with familial Mediterranean fever. *J Pediatr Ophthalmol Strabismus* 2001;38(2):114-6.
12. Hirsh A, Huna R, Ashkenazi I, Bartov E, Blumenthal M. Recurrent bilateral panuveitis and rhegmatogenous retinal detachment in a patient with familial Mediterranean fever. *Am J Ophthalmol* 1990;110(6):702-3.
13. Acharya NR, Tham VM, Esterberg E, Borkar DS, Parker JV, Vinoya AC, et al. Incidence and prevalence of uveitis: results from the Pacific Ocular Inflammation Study. *JAMA Ophthalmol* 2013;131(11):1405-12.
14. Tunca M, Akar S, Onen F, Ozdogan H, Kasapcopur O, Yalcinkaya F, et al. Familial Mediterranean fever (FMF) in Turkey: results of a nationwide multicenter study. *Medicine (Baltimore)* 2005;84(1):1-11.
15. Shohat M, Magal N, Shohat T, Chen X, Dagan T, Mimouni A, et al. Phenotype-genotype correlation in familial Mediterranean fever: evidence for an association between Met694Val and amyloidosis. *Eur J Hum Genet* 1999;7(3):287-92.
16. Pasa S, Altintas A, Devcioglu B, Cil T, Danis R, Isi H, et al. Familial Mediterranean fever gene mutations in the Southeastern region of Turkey and their phenotypical features. *Amyloid* 2008;15(1):49-53.