

# Paraplegia Following Type A Aortic Dissection After Open Cardiac Surgery: An Uncommon Complication

## Açık Kalp Cerrahisi Sonrası Gelişen Tip A Aort Diseksiyonuna Bağlı Parapleji: Nadir Bir Komplikasyon

<sup>1</sup> Burak BOZKURT<sup>a</sup>, <sup>2</sup> Yusuf Kağan POÇAN<sup>b</sup>, <sup>3</sup> Anıl KARAAĞAÇ<sup>a</sup>, <sup>4</sup> Ozan ERTÜRK<sup>c</sup>,  
<sup>5</sup> Mehmet KAPLAN<sup>a</sup>

<sup>a</sup>Dr. Siyami Ersek Thoracic and Cardiovascular Surgery Training and Research Hospital, Clinic of Cardiovascular Surgery, İstanbul, Türkiye  
<sup>b</sup>İskenderun State Hospital, Clinic of Cardiovascular Surgery, Hatay, Türkiye  
<sup>c</sup>Çankırı State Hospital, Clinic of Cardiovascular Surgery, Çankırı, Türkiye

**ABSTRACT** Type A aortic dissection is an infrequent occurrence following open-cardiac surgery, and the development of paraplegia as a complication is even rarer. This case report presents a unique instance of Type A aortic dissection in a patient who experienced paraplegia subsequent to undergoing coronary artery bypass grafting and mitral valve replacement. The causes of paraplegia after aortic dissection are diverse, with cerebrovascular diseases and spinal cord ischemia being uncommon contributors. Despite its rarity, paraplegia in this context carries substantial mortality and morbidity risks. This case emphasizes the importance of considering such complications in the postoperative management of cardiac surgery patients, highlighting the need for vigilance and early intervention.

**ÖZET** Tip A aort diseksiyonu, açık kalp cerrahisi sonrası nadir bir durumdur ve parapleji gelişimi daha da nadirdir. Bu vaka raporu, koroner arter baypas greftleme ve mitral kapak değişimi sonrasında parapleji gelişen bir hastada Tip A aort diseksiyonu örnek bir durumunu sunmaktadır. Aort diseksiyonu sonrası parapleji nedenleri çeşitlidir ve bunlar arasında serebrovasküler hastalıklar ve omurilik iskemisi nadir katkıda bulunan faktörlerdir. Nadir olmasına rağmen bu bağlamda parapleji önemli mortalite ve morbidite riskleri taşır. Bu vaka, kardiyak cerrahi hastalarının ameliyat sonrası yönetiminde bu tür komplikasyonların dikkate alınmasının önemini vurgulayarak, dikkatli olma ve erken müdahale gerekliliğini öne çıkarmaktadır.

**Keywords:** Paraplegia; dissection; spinal cord ischemia

**Anahtar Kelimeler:** Parapleji; diseksiyon; omurilik iskemisi

Neurological complications are important causes of mortality and morbidity after open-cardiac surgery. Cardiac surgery-associated paraplegia is very rare, although its incidence reaches 11% after aortic surgery (descending thoracic, abdominal aortic or dissection surgery).<sup>1</sup> Paraplegia may occur due to ischemia of the anterior spinal cord. While clinically loss of motor strength, pain and temperature sensations in the lower extremities are observed in patients, proprioception. And vibration senses may be partially protected. Type A aortic dissection is a very rare

complication after open-cardiac surgery. Aortic dissection may develop from the site of aortic cannulation, proximal anastomosis suture line, and the site of the aortic cannula. The development of paraplegia after aortic dissection is an unusual complication. Its incidence is 2-5%.<sup>2</sup>

### CASE REPORT

A 65-year-old male patient admitted to the cardiology unit with the complaint of sudden onset of shortness of breath. The echocardiography showed that the

#### TO CITE THIS ARTICLE:

Bozkurt B, Poçan YK, Karaağaç A, Ertürk O, Kaplan M. Paraplegia following Type A aortic dissection after open cardiac surgery: An uncommon complication. Türkiye Klinikleri J Cardiovasc Sci. 2024;36(1):35-8.

**Correspondence:** Burak BOZKURT

Dr. Siyami Ersek Thoracic and Cardiovascular Surgery Training and Research Hospital, Clinic of Cardiovascular Surgery, İstanbul, Türkiye

**E-mail:** drburakbozkurt@gmail.com



Peer review under responsibility of Türkiye Klinikleri Cardiovascular Sciences.

Received: 31 Dec 2023

Accepted: 12 Feb 2024

Available online: 15 Feb 2024

2146-9032 / Copyright © 2024 by Türkiye Klinikleri. This is an open access article under the CC BY-NC-ND license (<http://creativecommons.org/licenses/by-nc-nd/4.0/>).

ejection fraction was % 35 and severe mitral regurgitation. The diameter of the ascending aorta was 38 mm, the sinus valsalva was 37 mm. He had no history of diabetes mellitus and hypertension (HT). The coronary angiography showed a significant two-vessel disease and proximal stenosis of the left anterior descending (LAD) artery. There was no peripheral arterial disease.

After the median sternotomy, left internal thoracic (LITA) and right internal thoracic (RITA) arteries were harvested for full arterial coronary revascularization. Arterial cannulation from the ascending aorta and indirect bicaval venous cannulation from the right atrium was performed. RITA in situ-LAD and LITA in situ-diagonal artery distal anastomosis were performed. After the distal anastomosis, mitral valve replacement was performed while preserving the posterior leaflet. Cardiopulmonary bypass (CPB) time was 226 and cross-clamp time was 158 minutes. Mean arterial pressure was maintained between 60 and 80 mmHg during CPB. Intra-aortic balloon pump (IABP) was inserted from the right femoral artery due to low blood arterial pressure refractory to inotropic support in intensive care unit. The patient, who was hemodynamically stable and had normal blood gas parameters, was extubated on the 1<sup>st</sup> postoperative day. However, he had loss of lower extremity motor strength and pain and temperature sensations at thoracic (Th) 10 level and below. There were no deep tendon reflexes. Peripheral arterial pulses of the patient who developed paraplegia were normal. To rule out aortic dissection, bedside echocardiography was performed; however, no intimal flap was identified in the ascending aorta. Cerebrospinal fluid (CSF) pressure was measured as 14 mmHg. CSF drainage was performed, maintaining the CSF pressure below 10 mmHg. Spinal magnetic resonance imaging (MRI) could not be performed in the early period because of IABP and high-doses inotropes. A clinical diagnosis of spinal cord ischemia was made. He was given parenteral steroids (prednisolone) and diuretics (furosemide, mannitol).

He was intubated on the 5<sup>th</sup> postoperative day due to respiratory distress. The patient's IABP was removed after hemodynamic stability was achieved. Spinal contrast MRI was performed. MRI showed

spinal cord oedema (Figure 1). Thoracoabdominal computed tomography angiography (CTA) was performed urgently. CTA showed Type A aortic dissection (Figure 2). He was operated urgently.

Arterial cannulation from the axillary artery and two-stage venous cannulation was performed from the right atrium. CPB was initiated. Aorta was clamped and aortotomy was made. The intimal dissection tear was on the site of the root cannula. There was intramural hematoma in the ascending aorta (Figure 3). Intimal tear was reaching the arcus aorta but the aortic arch vessels were normal. Ascending aorta was replaced with 28 no dacron tube graft (Figure 4).

He was extubated at the postoperative 22<sup>nd</sup> hour but he was still paraplegic. He was reintubated on the 10<sup>th</sup> postoperative day due to respiratory distress. He

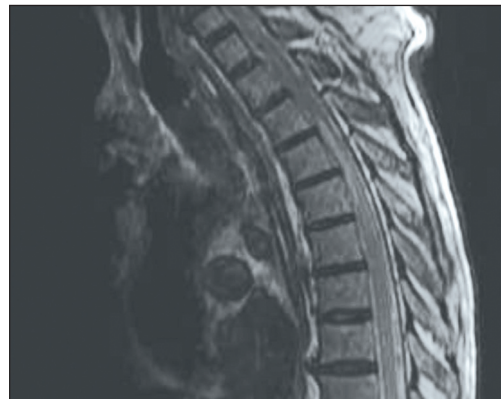


FIGURE 1: Lumbar magnetic resonance imaging t1 sequence-A significant spinal expansion and edema appearance was detected in the upper thoracic segments.

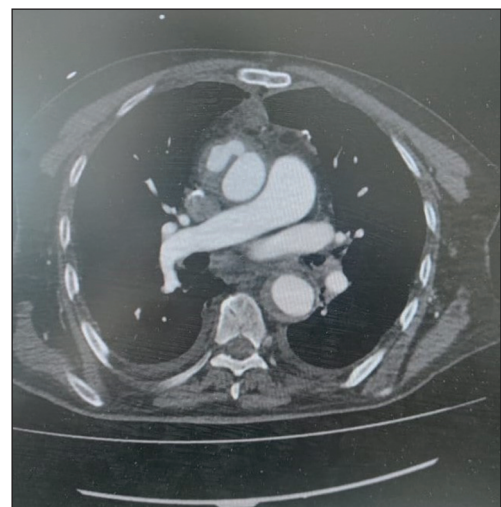


FIGURE 2: Type A aortic dissection from the root canula.

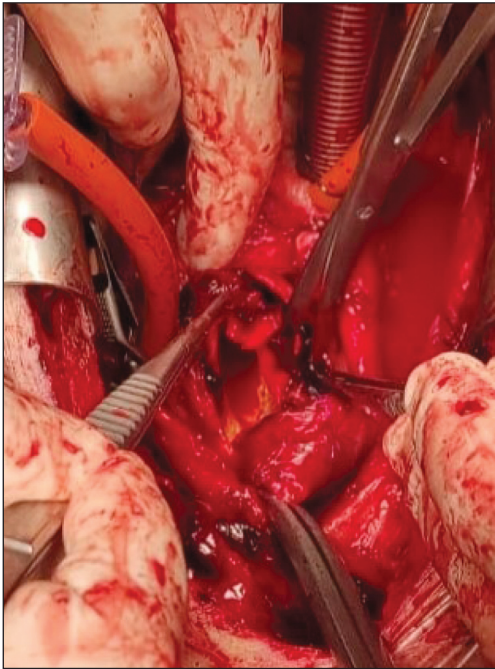


FIGURE 3: Intramural hematoma in the ascending aorta.

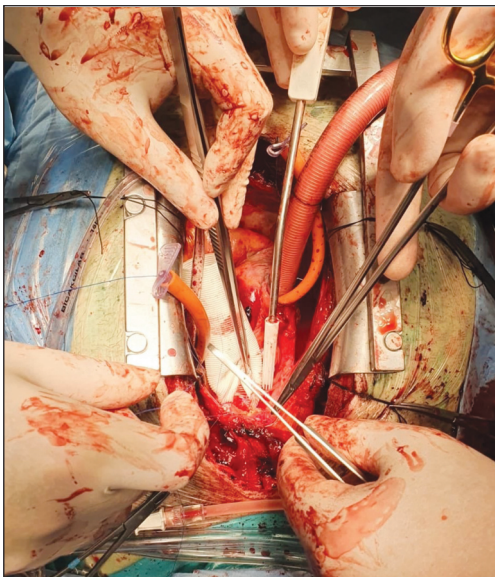


FIGURE 4: 28 no dacron tube graft.

died on the 34<sup>th</sup> postoperative day due to ventilator-associated pneumonia.

The study protocol was approved by the Dr. Siyami Ersek Thoracic and Cardiovascular Surgery Training and Research Hospital Ethics Committee (27.01.2022- E-28001928-604.01.01). The study was conducted in accordance with the principles of the Declaration of Helsinki.

A written informed consent was obtained from the parents and/or legal guardians of the patients.

## DISCUSSION

Type A aortic dissection is an uncommon complication after open-cardiac surgery. Aortic cross-clamping and aortic cannulation are the two most important causes of intimal damage during coronary bypass surgery or valve surgery.<sup>3</sup> In some cases, the aorta can be dissected from the area where the coronary bypass grafts are anastomosed to the aorta, and in rare cases, the aorta can be dissected from the location of the aortic root cannula. Aortic dissection may present with different clinical scenarios such as sudden chest pain and back pain, pallor, paresthesia in extremities. There might be painless dissection in some patients rarely.<sup>2</sup> Prolonged aortic cross clamp time, low perfusion pressure of the spinal cord and microemboli may cause spinal cord ischemia. The patient's peripheral vascular disease may increase the risk of developing paraplegia after cardiac surgery. In some cases, an increase in the incidence of development of paraplegia after insertion of IABP has been detected, and it has been reported that use of force on IABP placement, especially in patients with advanced aortoiliac disease.<sup>4</sup> MRI is the gold standard imaging of the spinal cord. However, MRI can be normal in the acute phase. Thus, absence of abnormal MRI findings during the acute phase does not rule out a clinical diagnosis.<sup>5</sup> A number of therapies are available to optimize spinal cord perfusion and minimize oedema including systemic corticosteroids, permissive HT and diuresis.<sup>4</sup> MRI could not be performed early period because he was hemodynamically unstable. Aortic dissection should be considered in neurological complications after cardiac surgery. 10-15% of spontaneous aortic dissections are asymptomatic.<sup>3</sup> Symptoms of aortic dissection are often masked by sedation and postoperative pain. Contrast-enhanced thoracic CTA should be performed when there is no reason to explain the clinical examination of patients with neurological complications. CSF drainage after emergency surgery play an important role in clinical recovery in dissection cases presenting with paraplegia. As with thoracoabdominal aortic surgery or endovascular interventions, it is important to keep the

CSF pressure below 10 mmHg with intermittent drainage.<sup>6</sup> In our patient, after the diagnosis of Type A Aortic dissection, emergent surgical intervention was planned, CSF pressures were followed before and after the operation and the pressure was kept between 8-10 mmHg. However, he was not clinically improved. In conclusion, in patients who develop paraplegia, aortic dissection as an important cause of spinal cord ischemia should be considered first in the differential diagnosis when no central neurological cause can be found and we suggest urgent CTA contrast.

### Source of Finance

*During this study, no financial or spiritual support was received neither from any pharmaceutical company that has a direct connection with the research subject, nor from a company that provides or produces medical instruments and materials which may negatively affect the evaluation process of this study.*

### Conflict of Interest

*No conflicts of interest between the authors and / or family members of the scientific and medical committee members or members of the potential conflicts of interest, counseling, expertise, working conditions, share holding and similar situations in any firm.*

### Authorship Contributions

**Idea/Concept:** Burak Bozkurt, Yusuf Kağan Poçan, Anıl Karaağaç; **Design:** Mehmet Kaplan, Anıl Karaağaç; **Control/Supervision:** Mehmet Kaplan, Burak Bozkurt; **Data Collection and/or Processing:** Burak Bozkurt, Ozan Ertürk, Yusuf Kağan Poçan; **Analysis and/or Interpretation:** Burak Bozkurt, Yusuf Kağan Poçan, Anıl Karaağaç; **Literature Review:** Burak Bozkurt, Yusuf Kağan Poçan, Ozan Ertürk; **Writing the Article:** Burak Bozkurt, Yusuf Kağan Poçan, Anıl Karaağaç; **Critical Review:** Mehmet Kaplan, Anıl Karaağaç, Burak Bozkurt, Yusuf Kağan Poçan; **References and Fundings:** Mehmet Kaplan; **Materials:** Ozan Ertürk.

## REFERENCES

1. Alektoroff K, Kettner M, Papanagiotou P. Spinale Ischämie [Spinal cord ischemia]. *Radiologe*. 2021;61(3):263-6. German. [[Crossref](#)] [[PubMed](#)]
2. Hdiji O, Bouzidi N, Damak M, Mhiri C. Acute aortic dissection presenting as painless paraplegia: a case report. *J Med Case Rep*. 2016;10:99. [[Crossref](#)] [[PubMed](#)] [[PMC](#)]
3. Archer AG, Choyke PL, Zeman RK, Green CE, Zuckerman M. Aortic dissection following coronary artery bypass surgery: diagnosis by CT. *Cardiovasc Intervent Radiol*. 1986;9(3):142-5. [[Crossref](#)] [[PubMed](#)]
4. Spielmann PM, Campanella C. Spinal infarction following coronary artery bypass grafting. *Interact Cardiovasc Thorac Surg*. 2004;3(4):606-7. [[Crossref](#)] [[PubMed](#)]
5. Sevik U, Kaya S, Ayaz F, Aktas U. Paraplegia due to spinal cord infarction after coronary artery bypass graft surgery. *J Card Surg*. 2016;31(1):51-6. [[Crossref](#)] [[PubMed](#)]
6. Svensson LG, Hess KR, D'Agostino RS, Entrup MH, Hreib K, Kimmel WA, et al. Reduction of neurologic injury after high-risk thoracoabdominal aortic operation. *Ann Thorac Surg*. 1998;66(1):132-8. [[Crossref](#)] [[PubMed](#)]