

# Complications During Cataract Surgery, Management and Outcomes: Descriptive Research

## Katarakt Cerrahisi Sırasında Gelişen Komplikasyonlar, Yönetimi ve Sonuçlarımız: Tanımlayıcı Araştırma

<sup>id</sup> Mümin Enver YİĞİT<sup>a</sup>, <sup>id</sup> Aysun SAGDANI<sup>a</sup>, <sup>id</sup> Gökhan ÖZGE<sup>a</sup>, <sup>id</sup> Ali Hakan DURUKAN<sup>a</sup>,  
<sup>id</sup> Önder AYYILDIZ<sup>a</sup>, <sup>id</sup> Duygu AKPINAR<sup>a</sup>

<sup>a</sup>University of Health Sciences Gülhane Faculty of Medical, Department of Ophthalmology, Ankara, Türkiye

This study was presented as an oral presentation with presentation number SS-KRC-38 at the 57<sup>th</sup> National Congress of the Turkish Ophthalmological Association on and included in the congress abstract book, November 12, 2023, Antalya, Türkiye.

**ABSTRACT Objective:** In our study, we aimed to reveal the type of complication, the surgical stage at which it developed, and our outcomes in cases that underwent cataract surgery and experienced intraoperative complications. **Material and Methods:** A total of 8,806 cases that underwent phacoemulsification surgery at Ankara Gülhane Training and Research Hospital were retrospectively reviewed. In complicated cases, data such as the type of cataract, additional case characteristics, surgical experience, type of anesthesia used, the stage at which the complication occurred, the necessity for vitreoretinal surgery, and the location and method of intraocular lens implantation (if implanted) were analyzed. **Results:** Of all cases, 64.6% (n=5,679) were operated on by faculty members, 22.9% (n=2,022) by specialist doctors, and 12.5% (n=1,105) by resident doctors. Intraoperative complications occurred in 289 (3.2%) of the phacoemulsification surgery cases. Among the complicated cases, 125 (43.4%) were performed by faculty members, 95 (32.8%) by specialist doctors, and 69 (23.8%) by resident doctors. The most common complication was posterior capsule rupture (75.7%). The most frequent stage at which complications occurred was the irrigation-aspiration stage at 48.4%. Posterior capsule rupture was the most frequent complication, occurring in 76.1% (n=220) of cases. Vitreoretinal surgery was performed in 32 of the 289 complicated cases. Visual acuity outcomes were better in cases completed in a single session compared to those requiring sequential surgeries (0.9 vs. 0.4, respectively, p<0.05). **Conclusion:** Our study provides valuable information on the stage at which complications most commonly occur during cataract surgery and the factors that affect the outcomes.

**ÖZET Amaç:** Çalışmamızda, katarakt cerrahisi geçirmiş ve intraoperatif komplikasyon gelişmiş olgularda komplikasyonun şekli ve hangi cerrahi aşamada geliştiği ve sonuçlarımızı ortaya koymayı amaçladık. **Gereç ve Yöntemler:** Ankara Gülhane Eğitim ve Araştırma Hastanesi'nde fakoemülsifikasyon cerrahisi yapılan 8.806 olgu retrospektif olarak incelendi. Komplike olgularda katarakt tipi, ek olgu özellikleri, cerrahi deneyim, kullanılan anestezi türü, komplikasyonun hangi evrede ortaya çıktığı, vitreoretinal cerrahi gerekliliği, göz içi lens implantasyonunun (eğer implante edildiye) yeri ve yöntemi gibi veriler incelendi. **Bulgular:** Tüm olguların %64,6'sı (n=5.679) öğretim üyeleri, %22,9'u (n=2.022) uzman doktor, %12,5'i (n=1.105) asistan doktor tarafından ameliyat edilmişti. Fakoemülsifikasyon cerrahisi yapılmış Olguların 289'unda (%3,2) intraoperatif komplikasyon geliştiği saptandı. Komplike olguların 125'i (%43,4) öğretim üyesi, 95'i (%32,8) uzman doktor, 69'u (%23,8) asistan doktor seviyesinde yapılan olgulardı. En sık görülen komplikasyon arka kapsül yırtılmasıydı (%75,7). Komplikasyonun en sık gerçekleştiği aşama %48,4 ile irrigasyon-aspirasyon aşamasıydı. En sık komplikasyon %76,1 (n=220) ile arka kapsül yırtılmasıydı. 289 komplike vakadan 32'sine VRC yapılmıştır. İlk seans ile bitirilen ameliyatların görme keskinlikleri sıralı ameliyat gerektiren olgulara göre daha iyi olarak saptandı (sırasıyla 0,9 ve 0,4, p<0,05). **Sonuç:** Çalışmamız katarakt ameliyatındaki komplikasyonların sıklıkla hangi aşamada gerçekleştiğini ve sonuçlara etki eden faktörler hakkında önemli bilgiler sunmaktadır.

**Keywords:** Cataract; complications; phacoemulsification; posterior capsule rupture

**Anahtar Kelimeler:** Katarakt; komplikasyonlar; fakoemülsifikasyon; arka kapsül rüptürü

**TO CITE THIS ARTICLE:**

Yiğit ME, Sagdani A, Özge G, Durukan AH, Ayyıldız Ö, Akpınar D. Complications during cataract surgery, management and outcomes: Descriptive research. Türkiye Klinikleri J Ophthalmol. 2024;33(4):252-7.

**Correspondence:** Mümin Enver YİĞİT

University of Health Sciences Gülhane Faculty of Medical, Department of Ophthalmology, Ankara, Türkiye

**E-mail:** eyigit43@gmail.com



Peer review under responsibility of Türkiye Klinikleri Journal of Ophthalmology.

**Received:** 14 May 2024

**Received in revised form:** 07 Aug 2024

**Accepted:** 13 Aug 2024

**Available online:** 21 Aug 2024

2146-9008 / Copyright © 2024 by Türkiye Klinikleri. This is an open access article under the CC BY-NC-ND license (<http://creativecommons.org/licenses/by-nc-nd/4.0/>).

Cataract is defined as the opacification of the crystalline lens inside the eye and can reduce visual acuity. Although aging is the most common cause, it is known that various systemic diseases, trauma, medications, and genetic predisposition are associated with the formation of cataracts. It is also the most common treatable cause of blindness worldwide.<sup>1</sup>

Cataract surgery is one of the most commonly performed and effective surgical procedures worldwide. The history of cataract surgery dates back to the 5<sup>th</sup> century BC, with the method of couching for mature cataracts, which involved pushing the cataract into the vitreous.

This method was followed by extracapsular cataract extraction and intracapsular cataract extraction techniques, respectively. The phacoemulsification (phaco) technique and intraocular lens (IOL) implantation, described by Charles Kelman in 1967, are currently the most widely accepted and safest methods.<sup>2</sup> Modern cataract surgery has evolved beyond just removing the opaque lens to provide visual rehabilitation and it has become a refractive surgery aiming to correct other refractive errors in patients as well.<sup>3</sup>

Although modern cataract surgery offers advantages such as working in a closed system, rapid wound healing, early rehabilitation, and low astigmatism, it has the disadvantage of having a long learning curve.<sup>4</sup>

Although the frequency of complications during cataract surgery continues to decrease thanks to advances in techniques and technology, various intraoperative complications have been identified. These include posterior capsule rupture, zonular dialysis, suprachoroidal hemorrhage, and lens material going into the vitreous.<sup>5</sup> It has been reported that the rate of posterior capsule rupture varies between 1-4.1%.<sup>6</sup> The incidence of dropped lens material is low, approximately around 0.18%, compared to posterior capsule rupture, while the incidence of zonular dialysis was reported to be approximately 0.46% in the same study.<sup>7</sup> Suprachoroidal hemorrhage, on the other hand, is a rarer complication, with an incidence of approximately 0.04%.<sup>8</sup>

In our study, we aimed to evaluate the type and stages of complications, management, and surgical ex-

perience in cases where complications developed during phacoemulsification+IOL implantation surgery.

## MATERIAL AND METHODS

Our study included 8,806 surgeries performed between November 2014 and May 2022, in which patients were diagnosed with cataracts and scheduled for phacoemulsification+IOL implantation surgery. Ethical approval was obtained from the Ethics Committee of Gülhane Scientific Research Ethics Board, University of Health Sciences (date: 21 April 2022; no: 2022/149) and the principles of the Helsinki Declaration were followed. The study protocol was retrospectively designed. Surgeries were retrospectively reviewed through surgical notes, patient admission records, and the hospital information management system. Since this is a retrospective study, informed consent forms for ethics committee approval were deemed unnecessary.

Cases where intraoperative complications were detected were reviewed by examining the surgical notes, patient admission records, and pre- and postoperative examinations in the hospital information management system. Data such as the type of cataract, experience level of the operating surgeon, type of anesthesia used during surgery, stage at which the complication occurred, need for vitreoretinal surgery (VRS), if an IOL was implanted, where and by what method the IOL was placed, preoperative and postoperative best corrected visual acuity (BCVA), and any additional complications during follow-up were analyzed.

Our study included all cataract cases aged 40 and above that were secondary to age-related or systemic diseases such as diabetes and developed intraoperative complications. The exclusion criteria were determined as cases that underwent phacoemulsification surgery after vitrectomy or penetrating keratoplasty and cases that underwent combined surgery. Additionally, individuals with a history of any previous eye surgery in the same eye or those who were poorly followed up were excluded from the study.

## SURGICAL METHOD

At least 3 minutes before all surgeries, the conjunctival sac was irrigated with 5% povidone-iodine solu-

tion. In all cases, corneal side ports were created at the 3-and 9-o'clock positions using a 20-gauge MVR blade. The anterior chamber was filled with 3% sodium hyaluronate (Protectalon, VSY Biotechnology). A corneal incision was made at 12 o'clock using a 2.65 mm blade. Hydrodissection and hydrodelineation were performed after capsulorhexis. The nucleus was emulsified using the "divide & conquer" technique. Remaining cortical material was cleaned with bimanual cannulas.

In cases where posterior capsule rupture occurred, triamcinolone was injected into the anterior chamber to visualize the presence of vitreous. In cases where vitreous was observed in the anterior chamber, anterior vitrectomy was performed using an anterior vitrector. For cases with zonular dialysis, depending on the size of the dialysis quadrant, capsule tension ring was placed inside the capsular bag as appropriate. For cases with drop lens material, vitrectomy was performed in the second session. In cases where suprachoroidal hemorrhage developed during vitrectomy session, urgent closure was performed to prevent further exposure of intraocular materials. In cases where the posterior capsule rupture was not significant, IOL was placed in the capsular bag; in cases where sulcus support was adequate, it was placed in

the sulcus; and in cases where sulcus support was inadequate, it was placed with scleral fixation.

## STATISTICAL ANALYSIS

Descriptive statistics were conducted using IBM SPSS Statistics 24.0 software (IBM Co., NY, USA). Continuous variables are presented as mean±standard deviation, while categorical variables are expressed as frequencies and percentages. The difference between preoperative and postoperative BCVA was analyzed using the Wilcoxon test. The correlation between cataract severity and complications was examined using the Spearman correlation test. A P-value less than 0.05 was considered statistically significant.

## RESULTS

Among the 8,806 surgeries planned for phacoemulsification with IOL implantation during the specified period, it was found that 5,679 (64.6%) were performed by senior doctors, 2,022 (22.9%) by specialist doctors, and 1,105 (12.5%) by resident doctors (Figure 1). Complications such as posterior capsule rupture, zonular dialysis, drop lens material, anterior chamber misdirection, and suprachoroidal hemorrhage were observed in 289 (2.49%) of these surg-

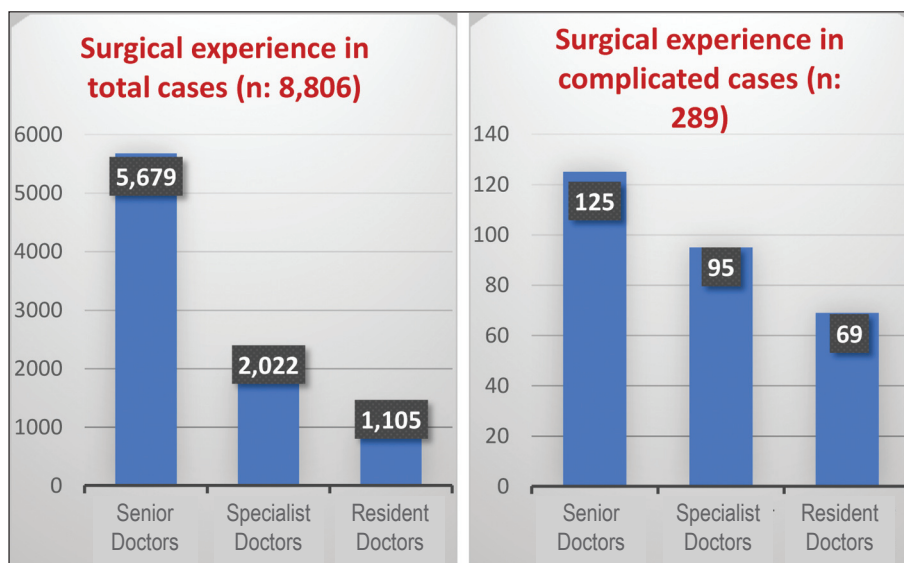


FIGURE 1: Surgical experience.

eries. The most commonly occurring complication was posterior capsule rupture, accounting for 76.1% (n=220) of cases. This was followed by zonular dialysis with a rate of 10.4% (n=30), while lens material going into the vitreous was observed in 9.7% (n=28) of complications.

It was determined that 43.4% (n=125) of the complicated cases were performed by senior doctors, 32.8% (n=95) by specialist doctors, and 23.8% (n=69) by resident doctors (Figure 1). When the number of complications was proportionate to the total number of cases they performed, the complication rates were 2.2% for senior doctors, 4.6% for specialist doctors, and 6.2% for resident doctors. Among the 1,105 surgeries performed by resident doctors with their level of experience during the specified period, intraoperative complications occurred in 69 cases (6.2%).

Among the 289 cases with complications, the most common surgical stage where complications occurred was the remaining cortical material cleaning stage, accounting for 48% of cases. This was followed by phacoemulsification (34%) and IOL implantation (11%) stages (Figure 2)

Of the 8,806 surgeries, 685 were performed under general anesthesia (7.7%), 68 under retrobulbar anesthesia (0.77%), 63 under subtenon anesthesia (0.71%), and 70 under subconjunctival anesthesia (0.79%), while 7,920 were conducted with topical anesthesia (89.9%). Among the 289 cases with complications, 16 were under general anesthesia (5.5%), 4 under retrobulbar anesthesia (1.3%), 7 under subtenon anesthesia (2.4%), 3 under subconjunctival anesthesia (1.03%), and 259 under topical anesthesia (89.6%).

In cases where complications developed, a total of 206 patients had intraocular lenses placed in the ciliary sulcus, with 10 of them in the second session and the rest in the first session. In 11.8% of these cases, the IOL was placed in the capsular bag. In 12 patients, the IOL was placed using scleral fixation in the same session, and in 25 patients, it was placed in the second session. The Yamane technique was preferred for scleral fixation in 32 out of 37 patients. 15.5% of cases (45 patients) were left after the first session. (Figure 3)

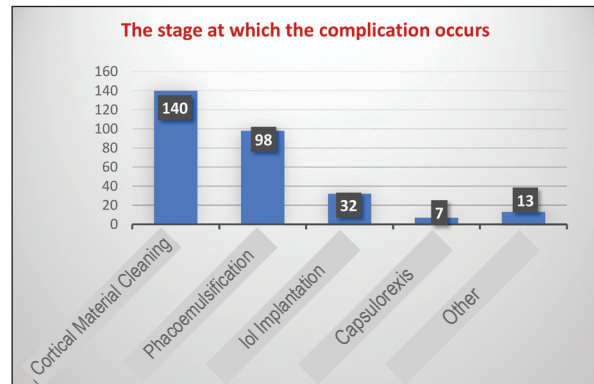


FIGURE 2: The stage at which the complication occurs.




FIGURE 3: Intraocular lens status in complicated cases.

In cases where complications developed, the classification of cataracts according to the Lens Opacities Classification System III classification was as follows: 48% were nuclear, 23% were posterior subcapsular, 14% were cortical, and 15% were mature, brown, white, or nigra cataracts. Among the cases, 32 required VRS, 3 developed retinal detachment within 1 year, 2 were found to have bullous keratopathy during follow-up, and 2 experienced intraoperative suprachoroidal hemorrhage.

In cases where complications occurred, the mean BCVA was 0.091±0.017 (according to the logarithm of minimum angle of resolution scale). The BCVA of surgeries completed in the first session was found to be higher than cases requiring sequential surgeries (p<0.05). Additionally, a positive correlation was

found between the degree of cataract and the development of complications ( $p=0.026$ ).

## DISCUSSION

Modern cataract surgery has been found to be safe in over 95% of cases. With its increasing popularity worldwide, it is known that complications are inevitable, especially during the learning phase. However, with appropriate training and supervision by experienced phacoemulsification surgeons, the incidence of such complications is lower compared to learning through courses.<sup>9</sup>

Smith and Seiff reported in their study on resident training that the rates of vitreous loss were 16% in surgeries performed by first-year residents, 10% in surgeries by second-year residents, and 6% in surgeries by third-year residents.<sup>10</sup> Another study reported a vitreous loss rate of 14.7% during phacoemulsification surgeries performed by third-year residents.<sup>11</sup> In our study, the complication rate in surgeries performed by residents was found to be 6.9%. Tabandeh et al. reported an incidence of posterior capsule rupture of 4.4% in their study.<sup>12</sup> Cruz et al. reported a posterior capsule rupture rate of 9.9% in their retrospective analysis of visual outcomes and complication incidence in 181 phacoemulsification cases.<sup>13</sup> They stated that 72% of posterior capsule ruptures occurred during residual cortex cleaning and 22% during phacoemulsification. Three in our study, the overall complication rate was 2.49%, with a posterior capsule rupture rate of 76.1% among all complications. Similarly, the stage with the highest complication rate was residual cortex cleaning, with a rate of 48%.

Javitt et al. reported a postoperative retinal detachment rate of 1.17% after uncomplicated phacoemulsification, but this rate increased to 5% when performed after anterior vitrectomy.<sup>14</sup> Thylefors et al. reported a risk of retinal detachment of 2.01% in patients who developed posterior capsule rupture during cataract surgery when analyzing the risk of regmatogenous retinal detachment after cataract surgery.<sup>15</sup> In our study, the rate of retinal detachment following complicated cataract surgery was found to be 1.03%.

During cataract surgery, the incidence of suprachoroidal hemorrhage varies between 0.03-0.13%.<sup>16,17</sup> In our study, this rate was found to be 0.69%. The use of smaller incisions or scleral tunnels has been reported to be more beneficial for controlling suprachoroidal hemorrhage due to their ability to create a closed system and prevent sudden decrease in intraocular pressure.<sup>18</sup> It is estimated that postoperative edema may develop in 1-2% of patients undergoing cataract surgery.<sup>19</sup> In our study, this rate was found to be 0.69%.

Earlier studies have reported that cataract surgeries performed using various methods result in visual acuity better than 6/18 in 65-90% of cases.<sup>20</sup> In our study, we also found a significant increase in postoperative visual acuity compared to preoperative values. However, the better postoperative visual acuity in cases where surgery was completed in the first session compared to cases requiring sequential surgeries highlights the negative impact of the need for sequential surgeries on postoperative visual acuity. Therefore, knowing what to expect during surgery and what to do can improve visual outcomes.

Sutton and colleagues stated in their study that continuously evolving technology and increased surgical experience are associated with a significant decrease in complications.<sup>21</sup>

## LIMITATIONS

The limitations of our study can be considered as its retrospective nature, the fact that we are a tertiary care hospital leading to the referral of challenging cases to us, and the inclusion of resident training as part of the study.

## CONCLUSION

Our study provides significant data to the literature regarding cases with complications detected during cataract surgery, including the type of complication and the surgical stage at which it occurred, the experience level of the surgeon performing the surgery, our management of the complications, and our outcomes.

### *Source of Finance*

*During this study, no financial or spiritual support was received neither from any pharmaceutical company that has a direct con-*

nection with the research subject, nor from a company that provides or produces medical instruments and materials which may negatively affect the evaluation process of this study.

### Conflict of Interest

No conflicts of interest between the authors and / or family members of the scientific and medical committee members or members of the potential conflicts of interest, counseling, expertise, working conditions, share holding and similar situations in any firm.

### Authorship Contributions

**Idea/Concept:** Ali Hakan Durukan, Gökhan Özge, Önder Ayyıldız; **Design:** Mümin Enver Yiğit; **Control/Supervision:** Gökhan Özge; **Data Collection and/or Processing:** Mümin Enver Yiğit, Aysun Sagdani, Duygu Akpınar; **Analysis and/or Interpretation:** Ali Hakan Durukan, Gökhan Özge; **Literature Review:** Mümin Enver Yiğit, Aysun Sagdani; **Writing the Article:** Mümin Enver Yiğit, Aysun Sagdani; **Critical Review:** Ali Hakan Durukan, Gökhan Özge, Önder Ayyıldız; **References and Fundings:** Mümin Enver Yiğit.

## REFERENCES

- Thompson J, Lakhani N. Cataracts. *Prim Care*. 2015;42(3):409-23. [Crossref] [PubMed]
- Davis G. The evolution of cataract surgery. *Mo Med*. 2016;113(1):58-62. [PubMed] [PMC]
- Can İ, Takmaz T, Özdamar A, Kamiş Ü, Aydın Akova Y, Arslan OŞ, et al. Evaluation of the cataract surgery 2018 survey in terms of achieving refractive cataract surgery targets. *Turk J Ophthalmol*. 2021;51(1):7-18. [Crossref] [PubMed] [PMC]
- Steinert RF, Brint SF, White SM, Fine IH. Astigmatism after small incision cataract surgery. A prospective, randomized, multicenter comparison of 4- and 6.5-mm incisions. *Ophthalmology*. 1991;98(4):417-23 [Crossref]
- Chan E, Mahroo OA, Spalton DJ. Complications of cataract surgery. *Clin Exp Optom*. 2010;93(6):379-89. [Crossref] [PubMed]
- Ionides A, Minasian D, Tuft S. Visual outcome following posterior capsule rupture during cataract surgery. *Br J Ophthalmol*. 2001;85(2):222-4. [Crossref] [PubMed] [PMC]
- Jaycock P, Johnston RL, Taylor H, Adams M, Tole DM, Galloway P, et al. The Cataract National Dataset electronic multi-centre audit of 55,567 operations: updating benchmark standards of care in the United Kingdom and internationally. *Eye (Lond)*. 2009;23(1):38-49. [Crossref] [PubMed]
- Ling R, Cole M, James C, Kamalarajah S, Foot B, Shaw S. Suprachoroidal haemorrhage complicating cataract surgery in the UK: epidemiology, clinical features, management, and outcomes. *Br J Ophthalmol*. 2004;88(4):478-80. [Crossref] [PubMed] [PMC]
- Yap EY, Heng WJ. Visual outcome and complications after posterior capsule rupture during phacoemulsification surgery. *Int Ophthalmol*. 1999;23(1):57-60. [PubMed]
- Smith JH, Seiff SR. Outcomes of cataract surgery by residents at a public county hospital. *Am J Ophthalmol*. 1997;123(4):448-54. [Crossref] [PubMed]
- Allinson RW, Metrikin DC, Fante RG. Incidence of vitreous loss among third-year residents performing phacoemulsification. *Ophthalmology*. 1992;99(5):726-30. [Crossref] [PubMed]
- Tabandeh H, Smeets B, Teimory M, Seward H. Learning phacoemulsification: the surgeon-in-training. *Eye (Lond)*. 1994;8(Pt 4):475-7. [Crossref] [PubMed]
- Cruz OA, Wallace GW, Gay CA, Matoba AY, Koch DD. Visual results and complications of phacoemulsification with intraocular lens implantation performed by ophthalmology residents. *Ophthalmology*. 1992;99(3):448-52. [Crossref] [PubMed]
- Javitt JC, Vitale S, Canner JK, Krakauer H, McBean AM, Sommer A. National outcomes of cataract extraction. I. Retinal detachment after inpatient surgery. *Ophthalmology*. 1991;98(6):895-902. [Crossref] [PubMed]
- Thylefors J, Jakobsson G, Zetterberg M, Sheikh R. Retinal detachment after cataract surgery: a population-based study. *Acta Ophthalmol*. 2022;100(8):e1595-e9. [Crossref] [PubMed] [PMC]
- Stein JD, Grossman DS, Mundy KM, Sugar A, Sloan FA. Severe adverse events after cataract surgery among medicare beneficiaries. *Ophthalmology*. 2011;118(9):1716-23. [Crossref] [PubMed] [PMC]
- Song W, Zhang Y, Chen H, Du C. Delayed suprachoroidal hemorrhage after cataract surgery: a case report and brief review of literature. *Medicine (Baltimore)*. 2018;97(2):e8697. [Crossref] [PubMed] [PMC]
- Koksaldi S, Utine CA, Kayabasi M. Management of suprachoroidal hemorrhage during cataract surgery: a case report. *Beyoglu Eye J*. 2022;7(1):66-70. [PubMed] [PMC]
- Pricopie S, Istrate S, Voinea L, Leasu C, Paun V, Radu C. Pseudophakic bullous keratopathy. *Rom J Ophthalmol*. 2017;61(2):90-4. [Crossref] [PubMed] [PMC]
- Ang GS, Whyte IF. Effect and outcomes of posterior capsule rupture in a district general hospital setting. *J Cataract Refract Surg*. 2006;32(4):623-7. [Crossref] [PubMed]
- Sutton G, Bali SJ, Hodge C. Femtosecond cataract surgery: transitioning to laser cataract. *Curr Opin Ophthalmol*. 2013;24(1):3-8. [Crossref] [PubMed]