

A Rare Case of Asymptomatic Giant Right Atrial Aneurysm: Case Report

Aseptomatik Dev Sağ Atriyal Anevrizmalı Nadir Bir Olgu

Fatoş ALKAN,^a
Özgür BAYTURAN,^b
Mecnun ÇETİN,^c
Şenol COŞKUN^a

Departments of
^aPediatrics Cardiology,
^bCardiology,
Celal Bayar University Faculty of Medicine,
Manisa
^cDepartment of Pediatric Cardiology,
Yüzüncü Yıl University Faculty of Medicine,
Van

Geliş Tarihi/Received: 26.12.2016
Kabul Tarihi/Accepted: 16.02.2017

Yazışma Adresi/Correspondence:
Fatoş ALKAN
Celal Bayar University Faculty of Medicine,
Department of Pediatric Cardiology,
Manisa,
TURKEY/TÜRKİYE
fatos.alkan@hotmail.com

This study was presented as a poster at the 15th National Congress of Pediatric Cardiology and Cardiovascular Surgery, 13-16 April 2016, Antalya.

ABSTRACT Right atrial aneurysm is a rare abnormality of the heart. This defect is seen in all age groups and is usually diagnosed incidentally. The aneurysm can be asymptomatic or present with symptoms related to supraventricular arrhythmias or thromboembolic phenomenon. We present the case report of a 74-year-old male with right atrial aneurysm which was incidentally detected during echocardiographic evaluation.

Keywords: Heart atria; aneurysm; echocardiography; tomography, x-ray computed

ÖZET Sağ atriyal anevrizma kalbin nadir ve sıklıkla konjenital orjinli bir anomalisidir. Fetal dönemden geç erişkin döneme kadar, tüm yaş gruplarında görülen bu defekt genellikle rastlantısal saptanabilmektedir. Aseptomatik olabileceği gibi supraventriküler aritmiler veya tromboembolik olaylar ile de ortaya çıkabilmektedir. Bu yazıda ileri yaşa kadar tanı almayan, aseptomatik 74 yaşında bir erkek olgu ekokardiyografi sırasında tesadüfen saptanması nedeniyle sunulacaktır.

Anahtar Kelimeler: Kalp atriumları; anevrizma; ekokardiyografi; tomografi, bilgisayarlı x-ray

The right atrial aneurysm is a cardiac malformation of unknown etiology, rarely found in cardiological practice. It can be detected at any time between fetal and adult life. Approximately half of patients show no symptoms. If no treatment is carried out, the risk of complications such as arrhythmia and thromboembolism will increase; therefore, medical or surgical treatment is recommended. In our article we present a rare and asymptomatic patient who was diagnosed with right atrial aneurysm at 74 years of age by echocardiography and computed tomography (CT) angiography.

CASE REPORT

A 74-year-old male patient was admitted to our department after referral from another hospital because of hypertension, and an abnormality was detected incidentally via echocardiography. His and his family's past history showed non specific findings. In the physical examination there

weren't any pathologic findings. An electrocardiogram (ECG) showed sinus rhythm with QRS axis of -30° . Surprisingly, the P wave was normal (Figure 1). A chest radiograph showed marked cardiomegaly with a cardiothoracic ratio of 60%. Laboratory findings were normal. On an echocardiogram there was a large cystic structure arising from the anterior freewall of the right atrium and extended across the atrioventricular groove over the anterior aspect of the right ventricle (Figure 2). The right atrial dimensions were 8.7x9.7 cm. No abnormality was found in the structure and function of the valves, and abnormal wall motion was not observed. Transesophageal echocardiogram (TEE) showed a cystic mass arising from the anterior freewall of right atrium, but no thrombus was found. The lesion was confirmed by CT angiogram, which depicted a giant aneurysm of

the right atrial free wall and causing slight compression of the right ventricle, otherwise two coronary systems were intact (Figure 3). It was considered that his signs were associated with the presumably congenital right atrial aneurysm. The patient was asked to undergo right atrial aneurysm resection due to the risk of complications such as arrhythmia and thromboembolism, but he denied the procedure and instead started anticoagulant therapy. At a recent 1- year follow-up visit, this patient was asymptomatic and doing well clinically.

DISCUSSION

An atrial aneurysm is defined as the dilatation of the atrium involving all layers of the atrial wall. Aneurysms of the right atrial are very rare and its origin is not clear. Although most right atrial

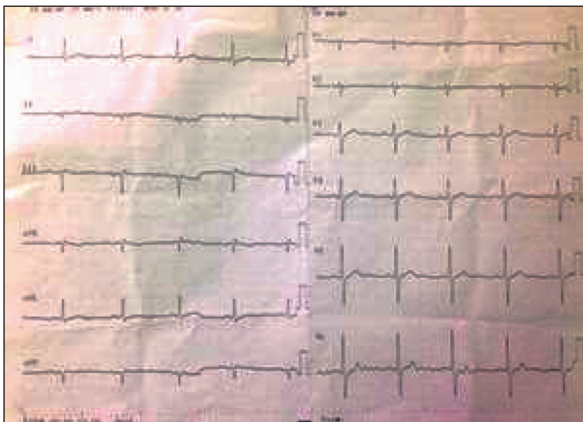


FIGURE 1: ECG showing sinus rhythm.

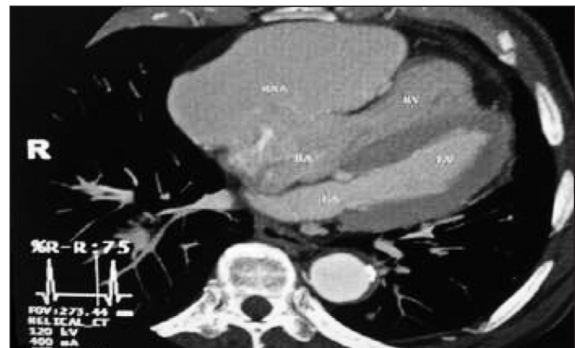

FIGURE 3: Computed tomography angiography scan demonstrating a right atrial aneurysm. LA; Left atrium, LV; Left ventricle, RA; Right atrium, RV; Right ventricle, RAA; Right atrial aneurysm.

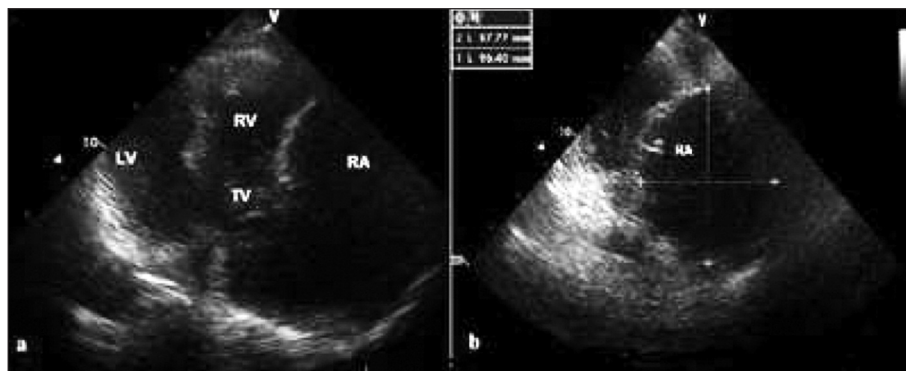


FIGURE 2: Transthoracic echocardiography from the apical four-chamber a) and modified b) view demonstrating an aneurysmal structure related to the right atrium. LA; Left atrium, LV; Left ventricle, RA; Right atrium, RV; Right ventricle, TV; Tricuspid valve, RAA; Right atrial aneurysm.

aneurysms have a congenital origin, acquired cases due to trauma have also been reported.^{2,3} The entity was first described in 1955 and performed the first surgical resection of a right atrial aneurysm in 1968.^{4,5}

In a review of 103 sporadic cases with congenital malformations of the right atrium and the coronary sinus published between 1955 and 1998 of the 105 cases in this series, 60 were cases of congenital enlargement of the right atrium.¹ The age at presentation varies from the neonatal period to late adulthood. The most common symptoms are palpitations due to atrial tachycardia, including atrial flutter and fibrillation. Other rhythm abnormalities include pre-excitation, junctional rhythm, atrioventricular block and incessant supraventricular tachycardia. In addition, potential complications include pulmonary thrombo-embolism, paradoxical systemic embolization and atrial rupture.^{1,6-8}

The majority of patients are asymptomatic and diagnosed with giant right atrial aneurysm after an incidental finding of cardiomegaly on chest radiograph. The diagnosis can be difficult as it is easily mistaken for more common anomalies that involve right atrial enlargement. Alternative diagnoses that can mimic giant right atrial aneurysm include Ebstein disease, pericardial effusion, pericardial cysts, and tumors.⁹ It is distinguishable from Ebstein's anomaly with normal placement and function of tricuspid valve. Correct diagnosis is necessary for planning therapy.¹⁰ The diagnosis of right atrial aneurysm can be established with echocardiography, angiography, CT, or MRI. In our case, right atrial aneurysm was diagnosed by

echocardiography, TEE, and confirmed by CT angiography.

Treatment options depend on clinical presentation, and include anticoagulation, catheter ablation, and surgery. Surgical treatment can be considered in symptomatic cases and in patients with symptoms due to compression of large aneurysms. Follow-up with conservative treatment may be appropriate in most cases. Asymptomatic patients should be managed conservatively with treatment directed toward prevention of thromboembolic complications.

In any event, asymptomatic patients should be evaluated individually for treatment. We recommended surgical treatment due to the risk of death from complications. However, he denied the treatment for the reasons of old age and the absence of symptoms. Currently, his progress is being observed with medication.

Informed Consent

Written informed consent was obtained from patient who participated in this case.

Conflict of Interest

Authors declared no conflict of interest or financial support.

Authorship Contributions

Concept: Özgür Bayturan, Mecnun Çetin, **Design:** Fatoş Alkan, Şenol Coşkun, **Supervision:** Fatoş Alkan, Mecnun Çetin, **Resource:** Fatoş Alkan, Şenol Coşkun, **Materials:** Özgür Bayturan, **Data Collection &/or Processing:** Fatoş Alkan, **Analysis &/ or Interpretation:** Özgür Bayturan, **Literature Search:** Fatoş Alkan, **Writing:** Mecnun Çetin, Fatoş Alkan, **Critical Reviews:** Şenol Coşkun.

REFERENCES

1. Binder TM, Rosenhek R, Frank H, Gwechenberger M, Maurer G, Baumgartner H. Congenital malformations of the right atrium and the coronary sinus: an analysis based on 103 cases reported in the literature and two additional cases. *Chest* 2000;117(6):1740-8.
2. Stone KS, Brown JW, Canal D, Caldwell R, Hurwitz R, King I. Congenital aneurysm of the left atrial wall in infancy. *Ann Thorac Surg* 1990;49(3):476-8.
3. Chatrath R, Turek O, Quivers ES, Driscoll DJ, Edwards WD, Danielson GK. Asymptomatic giant right atrial aneurysm. *Tex Heart Inst J* 2001;28(4):301-3.
4. Baily CP. *Surgery of the Heart*. 1st ed. Philadelphia, PA: Lea & Febiger; 1955. p.413.
5. Morrow AG, Behrendt DM. Congenital aneurysm (diverticulum) of the right atrium: clinic manifestations and results of operative treatment. *Circulation* 1968;38(1):124-8.
6. Mascio CE, Burkhart HM, Fagan T, Ge S, Burkhart DM. Neonatal right atrial aneurysm. *Ann Thorac Surg* 2005;80(6):2382.
7. Papagiannis J, Chatzis A, Sarris G. Giant right atrial aneurysm: a case report. *Int J Cardiol* 2008;129(1): e5-6.
8. Klisiewicz A, Szymański P, Rózański J, Hoffman P. Giant congenital aneurysm of the right atrium: echocardiographic diagnosis and surgical management. *J Am Soc Echocardiogr* 2004;17(3):286-7.
9. Maione S, Giunta A, Betocchi S, Ferro G, Vigorito C, Chiariello M. Two-dimensional echocardiography in idiopathic enlargement of the right atrium. Reliability and limitations. *Cardiology* 1983;70(4): 216-22.
10. Aryal MR, Hakim FA, Giri S, Ghimire S, Pandit A, Bhandari Y, et al. Right atrial appendage aneurysm: a systematic review. *Echocardiography* 2014;31(4): 534-9.