

# Treatment of an Extensive Superficial Spreading BCC with Topical Imiquimod Therapy and Cryotherapy Combination

## GENİŞ, YÜZEYEL YAYILAN BAZAL HÜCRELİ KARSİNOMANIN TOPİKAL İMİKİMOD VE KRYOTERAPİ KOMBİNASYONU İLE TEDAVİSİ

Emel BÜLBÜL BAŞKAN, MD,<sup>a</sup> Gülçin ALKAN, MD,<sup>a</sup> Şükran TUNALI, MD,<sup>a</sup> Hayriye SARICAOĞLU, MD<sup>a</sup>

<sup>a</sup>Department of Dermatology, Uludağ University Faculty of Medicine, BURSA

### Abstract

Imiquimod is an immune response modifier which has been successfully used and recognized in the treatment of genital warts and actinic keratoses through its indirect antiviral and antitumoral effects. There are also reports of imiquimod treatment for malignant tumoral lesions such as basal cell carcinoma, squamous cell carcinoma and metastatic melanoma. Here, we present a patient whose large, hemorrhagic plaque on the scalp was diagnosed as basal cell carcinoma who refused surgical therapy. Clinical result obtained by imiquimod and cryotherapy combination therapy was discussed with a review of related literature.

**Key Words:** Imiquimod, carcinoma, basal cell, cryotherapy

**Türkiye Klinikleri J Dermatol 2006, 16:213-216**

### Özet

İmikimod dolaylı antiviral ve antitümoral etkileri nedeniyle genital verrülerin ve aktinik keratozun tedavisinde başarıyla kullanılmakta olan bir immün cevap düzenleyicidir. İmikimodun bazal hücreli karsinoma, skuamöz hücreli karsinoma ve metastatik melanoma gibi malign tümoral lezyonların tedavisinde de kullanımı bildirilmiştir. Biz de bu makalede saçlı deride büyük, hemorajik plağı yüzeysel bazal hücreli karsinoma tanısı alan ve cerrahi girişimi kabul etmeyen hastayı sunuyoruz. İmikimod ve kryoterapi kombinasyon tedavisi ile gözlenen klinik sonucu literatür verileri ışığında tartıştık.

**Anahtar Kelimeler:** İmikimod, karsinoma, basal cell, kriyoterapi

**B**asal cell carcinoma (BCC) is the most common skin cancer and new effective treatments are being developed for this disease.<sup>1</sup> Imiquimod is an immune response modifier that acts on the immune system by stimulating monocytes/macrophages and dendritic cells to produce interferon-alpha and other cytokines, which are important in cell-mediated immunity.<sup>2</sup> Imiquimod has been shown to promote histological

clearance of superficial and nodular BCC in various clinical and phase III studies.<sup>1,3-8</sup>

Here we present a patient with an extensive superficial spreading basal cell carcinoma effectively treated with topical imiquimod application followed by cryotherapy, and we underline the efficacy of imiquimod as a nonsurgical therapeutic option in extensive BCC.

### Case Report

A 58-year-old man (Fitzpatrick skin type II), previously diagnosed as non-Hodgkin lymphoma presented with 4 years' history of an erythematous plaque, 5.5x4.5 cm. in size, located on the frontoparietal scalp and covered by sero-hemorrhagic crusts (Figure 1a). There was no lymphadenopathy.

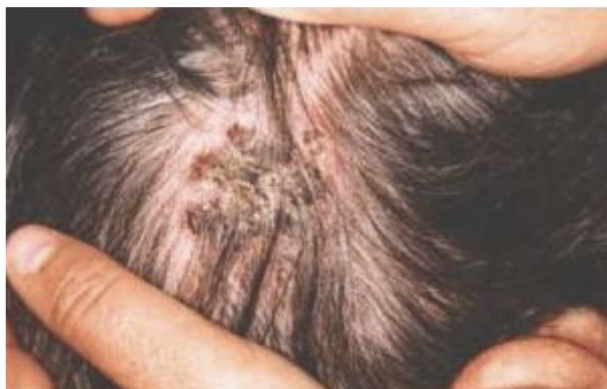**Geliş Tarihi/Received:** 28.02.2006 **Kabul Tarihi/Accepted:** 01.08.2006

**Yazışma Adresi/Correspondence:** Emel BÜLBÜL BAŞKAN, MD  
Uludağ University Faculty of Medicine,  
Department of Dermatology, BURSA  
bbemel@uludag.edu.tr

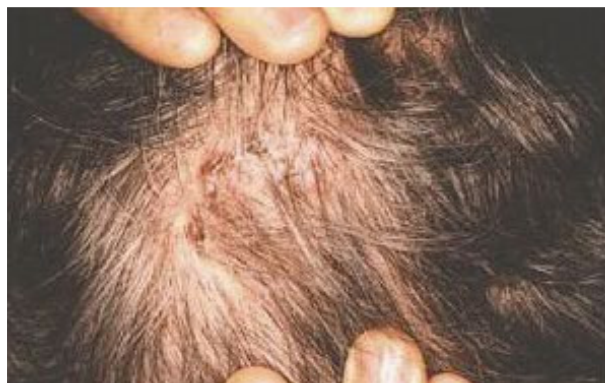Copyright © 2006 by Türkiye Klinikleri

Türkiye Klinikleri J Dermatol 2006, 16

213



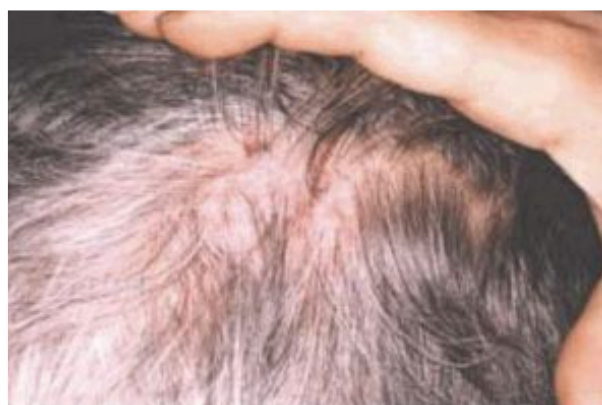**Figure 1a.** Clinical appearance of the erythematous plaque before the treatment.



**Figure 1b.** Clinical appearance of the treatment, lesion after 10 weeks' imiquimod. Note the persistence of few

The diagnosis was previously confirmed with histopathological examination (Figure 2a) and due to the size of the lesion he was offered surgical therapy by the plastic surgery clinic. The patient refused the surgical therapy due to the potentially large resulting defect after removal. Since the patient was against surgical procedures (confirmed with informed consent), we offered him to apply topical imiquimod 5% cream five days a week and visit the clinic every month. Upon his consent, baseline photographs were taken and the size of the lesion was recorded. The patient was evaluated by two dermatologists at 3<sup>rd</sup>, 5<sup>th</sup>, 10<sup>th</sup>, 16<sup>th</sup>, 22<sup>nd</sup> and 24<sup>th</sup> weeks of therapy and monthly after the completion of the topical imiquimod therapy.

The onset of clinical regression was observed at the 5<sup>th</sup> week of therapy. The clinical regression at the 10<sup>th</sup> week is presented in Figure 1b and the hemorrhagic crusts completely disappeared after 16 weeks of topical therapy. No side effect was reported except for slight erythema. As there was one resistant erythematous papule on the border of the lesion (Figure 1c), therapy was continued to 20 weeks having no additional response. Therefore, we suggested addition of cryotherapy to his current therapy but he acknowledged his satisfaction with the results of this therapy and refused. The patient demanded to continue the therapy for another 4 weeks. At the end of the 24<sup>th</sup> week of the treatment no improvement was observed, so after the with-

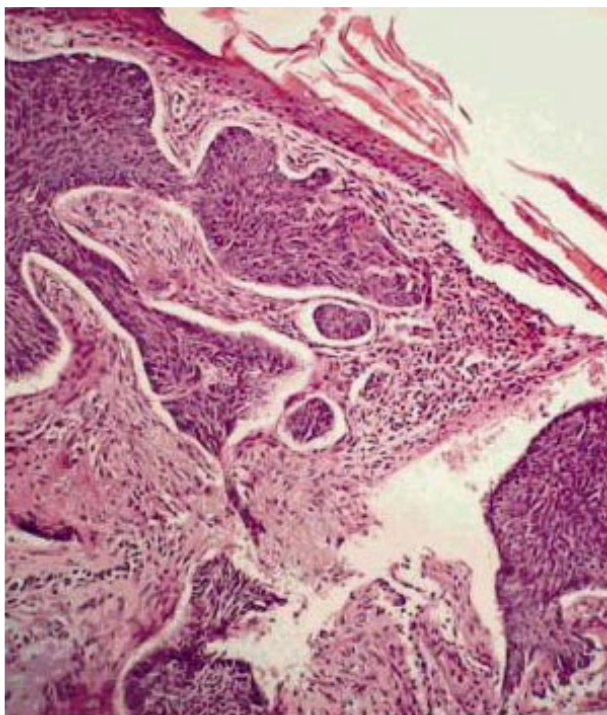


**Figure 1c.** The clinical appearance of the lesion after 20 weeks' treatment with only one resistant papule on the border of the lesion

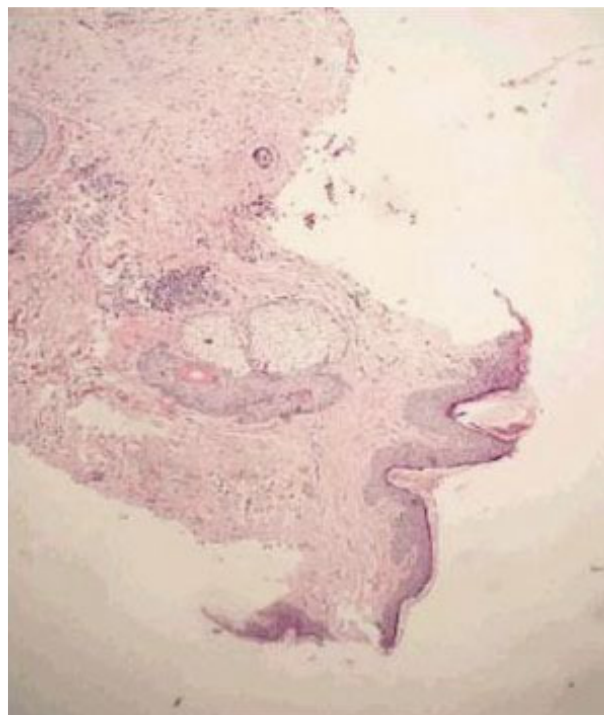
drawal of the imiquimod application, we applied cryotherapy (a total of 5 sessions applied as 2x15 seconds by open spray method with 3 weeks' intervals) to the erythematous papule. Four month post treatment punch biopsy was taken for histopathological evaluation and no histopathological feature of BCC or other malignancy was seen (Figure 2b).

## Discussion

Although surgical excision and cryotherapy are effective therapeutic options in BCC, noninvasive approach may sometimes be preferred for large tumor sizes and/or due to poor patient's compliance. Nonsurgical therapies for BCC include cryotherapy, intralesional interferon alpha-2a and



**Figure 2a.** Histopathology of initial biopsy specimen demonstrating typical features for BCC (H&E, x100 magnification)



**Figure 2b.** Histopathology of four months post treatment biopsy specimen demonstrating no histopathological feature.

2b, photodynamic treatment, topical 5-fluorouracil and topical imiquimod application, radiation therapy.<sup>9-11</sup> Previous clinical studies have already demonstrated the efficacy of topical imiquimod for treating both superficial and nodular BCCs (nBCC) under a variety of dosing schedules.<sup>1, 3-8</sup> Histological clearance rates in Phase II studies have been higher for subjects with superficial BCC than those with nBCC. The most recommended dosing regimen is the 5-times-a-week regimen. In addition, 6 and 12 week treatment durations have been evaluated as well as its use under occlusion.<sup>5,6</sup> Therefore, we preferred 5 times a week regimen for our patient without occlusion. Occlusive therapy could not be easily performed since the lesion was located on the scalp.

The most common side effects of imiquimod use are application site reactions (i.e; erythema, erosion, scabbing/crusting). The only adverse effect observed in our patient was slight erythema that developed in the first few weeks of the therapy.

Minsue Chen et al<sup>12</sup> previously reported the efficacy of imiquimod in large superficial basal

cell carcinoma. Topical imiquimod 5% cream was applied 3 times a week for a total of 12 weeks on BCC patch measuring 5x6 cm located on the dorsal arm. They achieved clinical and histological clearances with no recurrence at 4-months follow-up.

Our case is another vivid example of the efficacy of topical 5% cream applied 5 times a week on the extensive superficial BCC and combination of cryotherapy for the residual lesions. The therapy was well tolerated with minimal side effects but possibly prolonged because occlusion on scalp could not be applied efficiently.

It is apparent that, in addition to its efficacy in histological and clinical clearance, this approach greatly decreases disfigurement and provides acceptable cosmetic results even in larger lesions. We conclude that BCC therapy should be individualized based on the patient's immune status, age, compliance and co-morbid disorders. Recent clinical trials should focus on the efficacy and cost effectiveness of this self-administered therapy in larger BCC.

We conclude that imiquimod and cryotherapy combination therapy is quite effective even on extensive basal cell carcinomas and a good alternative for patients who refuse surgical applications.

### REFERENCES

1. Beutner KR, Geisse JK, Helman D, Fox TL, Ginkel A, Owens ML. Therapeutic response of basal cell carcinoma to immun response modifier imiquimod 5% cream. *J Am Acad Dermatol* 1999;41:1002-7.
2. Miller RL, Gerster JF, Owens ML, Slade HB, Toami MA. İmiquimod applied topically: a novel immune response modifier and new class of drug. *Int J Immunopharmacol* 1992;21:1-14.
3. Marks R, Gebauer K, Shumack S, et al. Imiquimod 5% cream in the treatment of superficial BCC: results of a multicenter 6 week dose response trial. *J Am Acad Dermatol* 2001;44:807-13.
4. Geisse J, Rich P, Pandya A, et al. Imiquimod 5% cream for the treatment of superficial basal cell carcinoma: a double-blind, randomized, vehicle-controlled study. *J Am Acad Dermatol* 2002;47:390-8.
5. Shumac S, Robinson J, Kossard S, et al. Efficacy of topical 5 % imiquimod cream for the treatment of nodular basal cell carcinoma: comparison of dosing regimens. *Arch Dermatol* 2002;138:1165-71.
6. Sterry W, Ruzicka T, Herrera E, et al. Imiquimod 5 % cream for the treatment of superficial and nodular basal cell carcinoma: randomized studies comparing low frequency dosing with and without occlusion. *Br J Dermatol* 2002;147:1227-36.
7. Geisse J, Caro I, Lindholm J, Golitz L, Stampone P, Owens M. Imiquimod 5% cream for the treatment of superficial basal cell carcinoma: Results from two phase III, randomized, vehicle-controlled studies. *J Am Acad Dermatol* 2004; 50: 722-33.
8. Vidal D, Matias-Guiu X, Alomar A. Open study of the efficacy and mechanism of action of topical imiquimod in basal cell carcinoma. *Clin Exp Dermatol* 2004;29:518-25.
9. Taştan HB, Koç E, Akar A, Gür AR. Treatment of basal cell carcinoma with intralesional interferon alpha-2a, 2b and combination of alpha 2a and 2b. *T Klin J Dermatol* 2000;10:16-22.
10. Ceylan C, Ozdemir F, Erboz S, Kazandı A, Ozol A. Topical photodynamic treatment in basal cell carcinoma. *Turkderm* 1999;33:153-7.
11. Huber A, Huber JD, Skinner RB Jr, Kuwahara RH, Haque R, Amonette RA. Topical imiquimod treatment for nodular basal cell carcinomas: an open-label series. *Dermatol Surg* 2004;30:429-30.
12. Chen TM, Rosen T, Orengo I. Treatment of a large superficial basal cell carcinoma with 5% imiquimod: a case report and review of the literature. *Dermatol Surg* 2002;28: 344-6.