

## CASE REPORT

DOI: 10.5336/caserep.2022-88264

# Oral Fibrolipoma: A Rare Histological Subtype

Elif ÇOBAN<sup>a</sup>, Berkan ALTAY<sup>a</sup>, Mehmet Hüseyin METİNEREN<sup>b</sup><sup>a</sup>Department of Oral and Maxillofacial Surgery, Kütahya University of Health Sciences Faculty of Dentistry, Kütahya, Türkiye<sup>b</sup>Department of Medical Pathology, Kütahya University of Health Sciences Faculty of Medicine, Kütahya, Türkiye

**ABSTRACT** Lipomas are soft tissue tumors who originate from adipose tissue. Histologically, subtypes ends are defined. These are fibrolipoma, angioliipoma, myxoid lipomas, spindle cell lipoma, pleomorphic lipoma and intramuscular lipoma. When a large proportion of connective tissue is present, the term fibrolipoma is used. Fibrolipoma subtype of the oral cavity is rare. The tumor has been reported to be more frequent in the buccal mucosa. This case report describes the treatment of an asymptomatic fibrolipoma lesion in the right buccal mucosa by local excision. Since asymptomatic lesions usually can only be detected in intraoral examination, physicians should be careful during clinical examinations and have information about rare histological subtype.

**Keywords:** Pathology; lipoma; biopsy

Lipomas are benign mesenchymal neoplasm that represents at least one-third of all benign tumors, consisting of well-circumscribed, slow growing composed of mature fat cell, most commonly seen on the trunk, shoulders, neck and axilla.<sup>1</sup> There are various histological subtypes of lipomas. If substantially connective tissue is present in histological examination, the term fibrolipoma is used. Fibrolipomas accounts for 1.6% of all maxillofacial lipomas.<sup>2</sup>

## CASE REPORT

In this study, a painless mobile mass in the right buccal mucosa of a 65-year-old female patient are reported. The patient had no known systemic disease or history of drug use. The patient was not using a total denture for 3 years.

The extraoral examination revealed no specific abnormality. In intraoral examination an evident submucosal swelling was observed. The covering mucosa was normal in texture without ulceration or inflammation. It was reported by the patient that the lesion had existed for 2 years and was asymptomatic. Since the patient did not use a prosthetic restoration

and did not have parafunctional habit, the lesion could not be associated with trauma.

Lesion was 1x1x1.5 cm<sup>3</sup> in size which was smooth pedunculated and fibrous (Figure 1). Excision biopsy was planned under local anesthesia. The pathological tissue taken by excisional biopsy was sent for histopathological examination (Figure 2). Differential diagnosis included lipoma, mesenchymal tumors and salivary gland tumors. Histological examination revealed mature adipose tissue separated by dense collagen fibers and wide fibrous bands in the lesion surrounded by a stratified squamous epithelium on the surface (Figure 3a, b). Histopathological diagnosis was fibrolipoma. The patient was evaluated in terms of glucose and lipid metabolism. The patient's hemoglobin A1c test value was 8.1. The patient was referred to the department of internal medicine and diabetes mellitus was diagnosed. A year follow-up revealed no recurrence.

Written informed consent was obtained from the patient for the use of clinical information, photographs and histopathological images given in this case report.

**Correspondence:** Elif ÇOBAN

Department of Oral and Maxillofacial Surgery, Kütahya University of Health Sciences Faculty of Dentistry, Kütahya, Türkiye

**E-mail:** elif.coban@ksbu.edu.tr



Peer review under responsibility of Türkiye Klinikleri Journal of Case Reports.

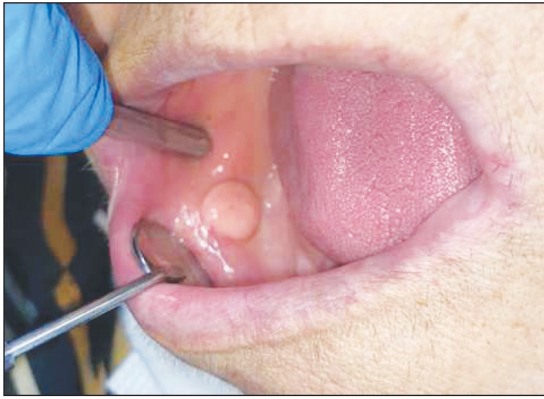**Received:** 23 Mar 2022

**Received in revised form:** 10 Aug 2022

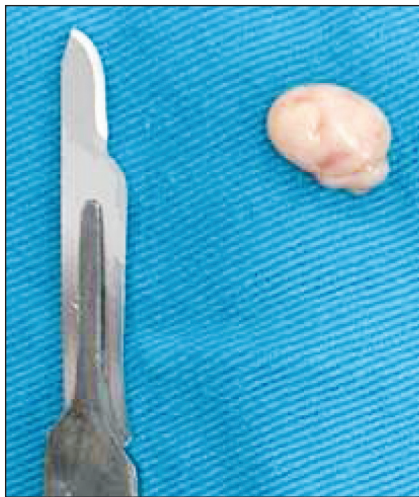
**Accepted:** 11 Aug 2022

**Available online:** 16 Aug 2022

2147-9291 / Copyright © 2022 by Türkiye Klinikleri. This is an open access article under the CC BY-NC-ND license (<http://creativecommons.org/licenses/by-nc-nd/4.0/>).



**FIGURE 1:** Clinical examination showing a pedunculated and well-circumscribed mass.



**FIGURE 2:** Macroscopic image of pathological tissue.

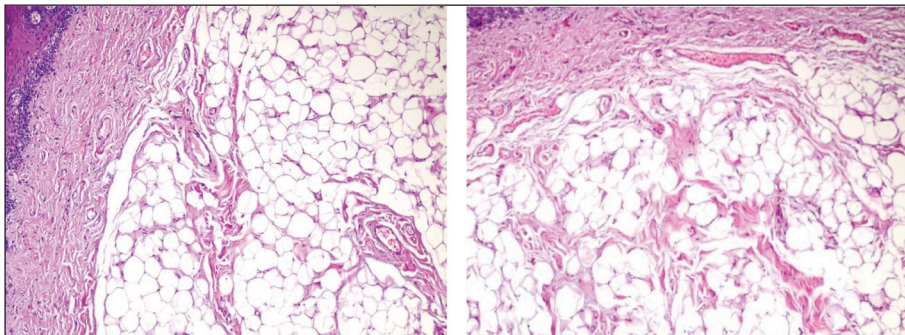
## DISCUSSION

Lipomas are slow-growing soft tissue neoplasms composed of mature adipose tissue.<sup>1</sup> Lipomas of the maxillofacial and oral region are rare, accounting for

only 1-4% of all such tumors.<sup>3</sup> Lipomas usually seen in the buccal mucosa. But, some buccal lipomas may not symbolize true tumors. These are rather herniation of the buccal fat pad through the buccinator muscle.<sup>3</sup> Histologically, various subtypes are defined for lipomas. These are fibrolipoma, angioliipoma, myxoid lipomas, spindle cell lipoma, pleomorphic lipoma and intramuscular lipoma.<sup>4</sup>

The subtype of 1.6% of lipoma lesions in the oral cavity is fibrolipoma.<sup>2</sup> Fibrolipomas are rare in the oral maxillofacial area and is classified as a version of conventional lipoma by the World Health Organization.<sup>5</sup> Histologically, connective tissue is mostly seen.<sup>3</sup> The mean age of occurrence of fibrolipoma is 34 years and occur mostly in adult men.<sup>2</sup> The etiopathogenesis of fibrolipomas is still unclear. Disturbances in glucose and lipid metabolism, hormone therapy, and trauma can lead to formation and proliferation of the fibrolipoma.<sup>6</sup> Also there may be an association between diabetes mellitus and fibrolipomas.<sup>2</sup> It can appear to be more common in overweight patient.<sup>3</sup> In the current case, the patient was female and had no history of disturbance in lipid metabolism and trauma. However, the patient was diagnosed with diabetes mellitus after being referred by our clinic.

Fibrolipoma of the oral cavity is rare. The tumor has been reported to be more frequent in the buccal mucosa.<sup>7</sup> Lesions normally appear with nodular aspect, oval shape, soft consistency or slightly indurated; they are floating, of sessile or pedunculated/pediculated implantation and smooth surface. Coloration varies from yellow to pink de-



**FIGURE 3: a-b:** (H&E, x100 magnification) Histological examination reveals mature adipose tissue separated by dense collagen fibers and wide fibrous bands in the lesion surrounded by a stratified squamous epithelium on the surface.

pending on the thickness of the mucosa. Depending upon the depth of tumor and quantity and distribution of fibrous tissue the consistency of fibrolipoma varies from soft to firm.<sup>8</sup> In our case, the lesion was in the buccal mucosa, slightly indurated, pedunculated implantation and smooth surface.

Microscopically the fibrolipoma shows benign adipocytes intermixed with broad bands of dense collagen. It is most commonly well circumscribed and can be thinly encapsulated. Malignant transformations in the oral and maxillofacial regions are rare.<sup>9</sup> But histologically, because of the adhesion of the surrounding tissues and focal pseudo-infiltration it can sometimes cause doubts in the differential diagnosis with malignant infiltrating lesions, and histological examination is mandatory for a definitive diagnosis.<sup>3</sup>

Differential diagnosis of fibrolipoma includes many lesions such as lymphangioma, angioma, schwannoma, pyogenic granuloma, minor salivary gland neoplasms and liposarcoma.<sup>6</sup> The treatment of fibrolipoma is local excision and recurrence is rare.<sup>10</sup>

The age range and gender, etiology and risk factors of fibrolipomas are still not clear. Rarely in the literature, in our case, the patient was elderly and female. In the diagnosis of fibrolipoma changes in glucose and lipidic metabolism and history of trauma should be evaluated. It should also be noted that fibrolipoma can also be a symptom of these undiagnosed diseases. Differential diagnosis should definitely be made because of its harder tissue com-

pared to lipomas and because it can be confused with malignant lesions histologically.

Fibrolipomas may not be noticed by patients unless they cause symptoms and can be detected during routine examination. It is the consensus of the authors that patients should be evaluated in terms of glucose and lipidic metabolism changes and malignant lesions in all cases thought to be fibrolipoma. In order to better recognize and manage fibrolipomas, more case reports and studies should be done about these lesions.

#### Source of Finance

*During this study, no financial or spiritual support was received neither from any pharmaceutical company that has a direct connection with the research subject, nor from a company that provides or produces medical instruments and materials which may negatively affect the evaluation process of this study.*

#### Conflict of Interest

*No conflicts of interest between the authors and / or family members of the scientific and medical committee members or members of the potential conflicts of interest, counseling, expertise, working conditions, share holding and similar situations in any firm.*

#### Authorship Contributions

**Idea/Concept:** Elif Çoban; **Design:** Berkan Altay; **Control/Supervision:** Berkan Altay; **Data Collection and/or Processing:** Elif Çoban; **Analysis and/or Interpretation:** Mehmet Hüseyin Metineren; **Literature Review:** Elif Çoban; **Writing the Article:** Elif Çoban; **Critical Review:** Berkan Altay; **Materials:** Elif Çoban.

## REFERENCES

1. Ponce JB, Ferreira GZ, Santos PS, Lara VS. Giant oral lipoma: a rare entity. *An Bras Dermatol.* 2016;91(5 suppl 1):84-6. [[Crossref](#)] [[PubMed](#)] [[PMC](#)]
2. Jung SN, Shin JW, Kwon H, Yim YM. Fibrolipoma of the tip of the nose. *J Craniofac Surg.* 2009;20(2):555-6. [[Crossref](#)] [[PubMed](#)]
3. Neville B, Damm D, Allen C, Chi A. *Oral and Maxillofacial Pathology.* 4<sup>th</sup> ed. St. Louis, MO: Elsevier; 2016.
4. Burket LE, Greenberg M, Glick M. *Burket's Oral Medicine.* 10<sup>th</sup> ed. New York: Decker; 2003.
5. Fletcher CDM, Unni KK, Mertens F. *Adipocytic tumors.* World Health Organization Classification of Tumours. Lyon: IARC Press; 2002. p.9-46.
6. Iaconetta G, Friscia M, Cecere A, Romano A, Orabona GD, Califano L. Rare fibrolipoma of the tongue: a case report. *J Med Case Rep.* 2015;9:177. [[Crossref](#)] [[PubMed](#)] [[PMC](#)]
7. Gupta S, Pathak S. Fibrolipoma of buccal mucosa - a case report. *J Indian Dent Assoc.* 2011;5:737-8.
8. Khubchandani M, Thosar NR, Bahadure RN, Baliga MS, Gaikwad RN. Fibrolipoma of buccal mucosa. *Contemp Clin Dent.* 2012;3(Suppl 1):S112-4. [[Crossref](#)] [[PubMed](#)] [[PMC](#)]
9. Kumar P, Naraniya A. Intraoral fibro-lipoma: a rare histological variant. *Indian J Oral Sci.* 2012;3(1):39. [[Link](#)]
10. Linares MF, Leonel AC, Carvalho EJ, de Castro JF, de Almeida OP, Perez DE. Intraoral lipomas: a clinicopathological study of 43 cases, including four cases of spindle cell/pleomorphic subtype. *Med Oral Patol Oral Cir Bucal.* 2019;24(3):e373-e8. [[PubMed](#)] [[PMC](#)]