

Martsolf Syndrome and Anesthesia: Case Report

Martsolf Sendromu ve Anestezi

Özgün CUVAŞ, MD,^a
Esra TÜRKYILMAZ, MD,^a
Bülent BALTACI, MD^a

^aDepartment of Anesthesiology and
Intensive Care Medicine,
Ankara Training and Research Hospital,
Ankara,

Geliş Tarihi/Received: 27.09.2010
Kabul Tarihi/Accepted: 10.11.2010

Yazışma Adresi/Correspondence:
Özgün CUVAŞ, MD
Ankara Training and Research Hospital,
Department of Anesthesiology and
Intensive Care Medicine, Ankara,
TÜRKİYE/TURKEY
ozguncuvas@yahoo.com

ABSTRACT In this case report, we described our anesthetic management in a 45-day-old baby with Martsolf syndrome. This is the second case of Martsolf syndrome described in the Turkish population. Martsolf syndrome is a rare autosomal recessive disorder characterized by cataract, mental retardation, microcephaly, short stature and hypogonadism. In addition to the findings correlated with Martsolf syndrome, the baby had a secundum type atrial septal defect (ASD). Preoperative equipment was prepared for possible difficult intubation because of micrognathia and high arched palate. Ventilation and intubation were difficult and oxygen saturation decreased during this period. We want to emphasize that pediatric patients with Martsolf syndrome may have a risk of difficult airway and cardiac pathology; therefore an anesthetist should be prepared for these difficulties.

Key Words: Anesthesia, general; intubation, intratracheal; maxillofacial abnormalities

ÖZET Bu olgu sunumunda, Martsolf sendromlu 45 günlük bir bebekteki anestezi uygulamamızı sunduk. Bu olgu Türk toplumunda tanımlanan ikinci Martsolf sendromu vakasıdır. Martsolf sendromu katarakt, zeka geriliği, mikrosefali, kısa boy ve hipogonadizmle karakterize nadir bir otozomal resesif hastalıktır. Martsolf sendromuyla uyumlu bu bulgulara ek olarak hastamızda sekundum tip atriyal septal defekt (ASD) vardı. Mikrognati ve yüksek kavisli damak nedeniyle olası zor entübasyon için preoperatif ekipman hazırlandı. Ventilasyon ve entübasyon zordu ve bu dönemde oksijen saturasyonu düştü. Martsolf sendromlu pediatrik hastaların zor havayolu ve kardiyak patoloji riskine sahip olabileceklerini, bundan dolayı anesteziistin bu zorluklara karşı hazırlıklı olması gerektiğini vurgulamak isteriz.

Anahtar Kelimeler: Anestezi, genel; entübasyon, intratrakeal; maksillofasyal anormallikler

Türkiye Klinikleri J Anest Reanim 2011;9(2): 146-9

Martsolf syndrome is a rare autosomal recessive disorder first described in two brothers in the Jewish population with cataract, mental retardation, microcephaly, short stature and hypogonadism.¹ Up to date approximately eight case reports about Martsolf syndrome have been reported.¹⁻⁸ The first case in the Turkish population was described by Bora et al.⁷ These case reports were especially interested in the clinical presentation and genetic details of this syndrome. Patients with Martsolf syndrome have congenital cataract and they may undergo surgery at the early stage of their lives.^{2-5,7,8} There is no data about anesthetic management of a patient with Martsolf syndrome in literature.

Here, we described a 45-day-old Turkish boy with Martsolf syndrome underwent cataract surgery under general anesthesia.

CASE REPORT

A 45-day-old male baby was consulted preoperatively for general anesthesia for cataract surgery. The baby was born at term by spontaneous delivery. His birth weight was 3100 g (40th centile), height was 45 cm (<3rd centile) and head circumference was 32 cm (<3rd centile). The parents were not consanguineous. The patient's mother had asthma bronchiale. He was referred to the hospital because of difficulties in feeding. On physical examination, microcephaly, congenital cataract, micrognathia, low nasal bridge, long philtrum, high arched palate, pouting mouth, low posterior hairline, sparse facial hair, unilateral cryptorchidism and micropenis with extended penile length of 10 mm were observed (Figure 1). The patient had no microcornea, microphthalmia and optic atrophy.

The laboratory investigation included a complete blood count, routine biochemical testing of liver and kidney function, measurement of serum levels of electrolytes, creatinine phosphokinase, ammonia, lactate, pyruvate, urine and blood amino acid analysis. All results were normal. Toxoplasmosis, rubella, cytomegaly, herpes (TORCH) and galactosemies were ruled out. On cardiovascular examination, a secundum ASD was detected on echocardiography (Figure 2).

Chromosome analysis showed a normal male karyotype.

The written informed consent was taken from the patient's mother. Breast feeding was stopped 4 hours before surgery. Operating theater temperature was increased to 26 °C and warming blanket was turned on. A Miller blade no.1, proper size of face masks and oral airways, uncuffed endotracheal tubes no. 3.5-3-2.5, stylet, suction apparatus, 6F suction catheter and laryngeal mask (LMA) no.1 were prepared. After routine monitoring with ECG, noninvasive blood pressure and pulse oximeter, a 24G intravenous cannula was inserted at the left brachial vein. Infusion of D5 ¼ NS solution was started at a rate of 20 ml kg⁻¹ h⁻¹ for the first hour. Precordial stethoscope was attached. Patient's temperature was measured as 37.0°C with axillary digital thermometer. The patient's weight was 4200 g, heart rate was 130 beats min⁻¹ blood pressure was 75/42 mmHg and SpO₂ was 99%. After preoxygenation with 100% O₂ for 3min, mask ventilation with incremental increases in sevoflurane in 100% oxygen was started, but it was seen that the patient was not motionless in spite of inhalational induction and the patient's lungs were not ventilated adequately. 1 µg.kg⁻¹ fentanyl and 4 mg.kg⁻¹ thiopental sodium were administered to increase the level of anesthesia. Oral airway was inserted and jaw thrust maneuver was applied. Difficult ventilation was continued and SpO₂ value started to decrease, so 0.02 mg.kg⁻¹ IV atropine and 2 mg.kg⁻¹ IV

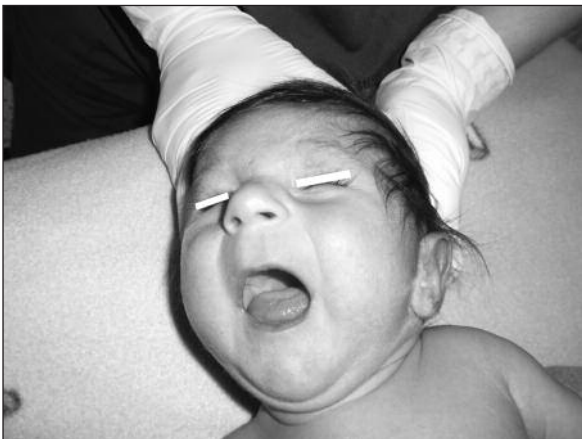

FIGURE 1: A 45-day-old baby with Martsolf Syndrome.

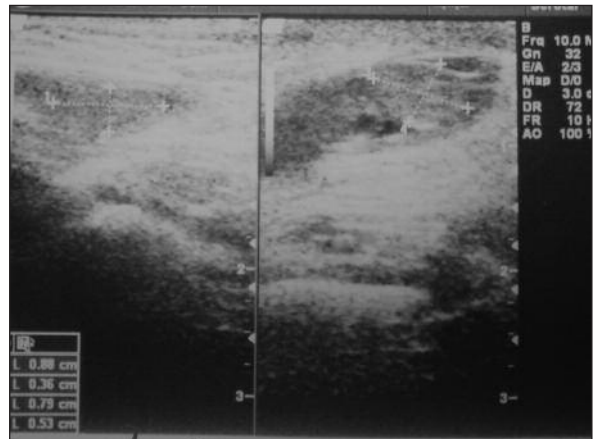


FIGURE 2: A secundum type ASD on ECHO.

succinylcholine was administered. Laryngoscopy was started 30 second after succinylcholine administration. At the first attempt, only epiglottis was seen and intubation was failed with uncuffed endotracheal tube no. 3.5. Another ETT no.3 with sytlet was inserted at the second attempt, just then SpO₂ was 88% and end-tidal CO₂ was 45 mmHg. After intubation, patient's lungs were ventilated uneventfully. Tracheal intubation was confirmed by end-tidal CO₂ and auscultation of lung sounds. Bradycardia was not seen during intubation period. Dexamethasone 0.5 mg kg⁻¹ was given intravenously. Ventilation was maintained manually with 100% oxygen via a Mapleson D circuit with 3 L min⁻¹ fresh gas flow until SpO₂ value would be 100% and 50% nitrous oxide in oxygen with 2-2.5% sevoflurane thereafter. Neuromuscular block was established by 0.05 mg kg⁻¹ vecuronium after spontaneous ventilation had started. During operation, SpO₂ and end-tidal CO₂ values were maintained > 98% and 35-38 mmHg, respectively. Lensectomy operation was lasted 55 min. At the end of the operation 0.015 mg kg⁻¹ atropine and 0.03 mg kg⁻¹ neostigmine was administered for the antagonism of neuromuscular block. Trachea was not extubated until adequate spontan ventilation, eye opening and upper airway reflexes returned. The patient was observed at PACU until the Modified Aldrete Score was 10. He was discharged after two days without any complication related to anesthesia or surgical procedure.

DISCUSSION

Major findings of Martsolf syndrome are cataract, microcephaly, hypogonadism, short stature and mental retardation. In addition to these features a number of dysmorphological findings such as low nasal bridge, maxillary retrusion, pouting mouth, high arched palate, malaligned teeth, micrognathia, sternal anomaly, lax finger joints and feet anomalies have been described in patients with Martsolf syndrome.¹⁻⁸

There is an existence of phenotypic similarity of some cases with Micro syndrome with that of Martsolf syndrome. It has been proposed that

Martsolf syndrome and Micro syndrome are also allelic variants. On the other hand, ocular and neurodevelopmental defects are less severe and microphthalmia is not a feature in Martsolf syndrome.^{1, 9} Our patient had no microcornea, microphthalmia and optic atrophy, therefore his syndrome was not Micro syndrome. The normal karyotype in our patient excluded chromosomal abnormalities.

There are six case reports in the literature which state that the patients with Martsolf syndrome have to undergo a surgical operation for congenital cataract, but there is no information about anesthetic management.^{2-5, 7, 8} It is clear that the syndromes with facial dysmorphic features are related to the difficult airway. Pediatric patients with congenital cataract undergo surgery at the early stage of their lives; therefore anesthesiologists should be familiar with the management of airway and be able to recognize and identify potential difficult airway. We prepared the equipment for difficult airway because of the fact that our patient had micrognathia and high arched palate. We preferred induction with inhalation agent, but had to use intravenous anesthetics to increase anesthetic level and relieve mask ventilation. In the case of unsuccessful second attempt of intubation, we would insert the LMA as soon as possible. The LMA and fiberscope are useful techniques in handling difficult airway. Unfortunately, we had no pediatric size of fiberscope, so we prepared proper size of LMA before induction of anesthesia. LMA provides an alternative way for tracheal intubation and an airway in urgent situations in which the patient cannot intubate and ventilate.

Among the case reports about Martsolf syndrome, only Harbour et al reported a brother and sister pair with features of Martsolf syndrome and a cardiomyopathy or cardiac failure.⁵ According to their report, the male infant with cardiac failure died owing to renal failure secondary to cardiac failure. Our patient had a secundum ASD. His cardiac pathology was not severe when compared to those reported by Harbour et al, but it was a warning to the anesthesiologist about the presence of a cardiac

pathology with Martsolf syndrome. In patients with cardiac pathology, oxygen saturation can rapidly decrease with transient interruption in breathing, whether due to apnea or airway obstruction with failure to establish effective ventilation. They will have a decreased margin of safety and will tolerate failures of respiratory or hemodynamic management poorly. In these patients, airway, ventilation and oxygen effects on the cardiovascular system are of primary

importance during the induction of anesthesia.¹⁰ In patients with facial dysmorphic features and cardiac pathology, induction-intubation period and the maintenance of patient's airway are vital.

In conclusion, we want to emphasize that pediatric patients with Martsolf syndrome may have a risk of difficult airway and cardiac pathology; therefore an anesthesiologist should be prepared for these difficulties.

REFERENCES

1. Martsolf JT, Hunter AGW, Haworth JC. Severe mental retardation, cataracts, short stature and primary hypogonadism in two brothers. *Am J Med Genet* 1978;1(3):291-9.
2. Sanchez JM, Barreiro C, Freilij H. Two brothers with Martsolf's syndrome. *J Med Genet* 1985;22(4):308-10.
3. Strisciuglio P, Costabile M, Esposito M, Di Maio S. Martsolf's syndrome in a non-Jewish boy. *J Med Genet* 1988;25(4):267-9.
4. Hennekam RCM, van de Meeberg AG, van Doorne JM, Dijkstra PF, Bijlsma JB. Martsolf syndrome in a brother and sister: clinical features and pattern of inheritance. *Eur J Pediatr* 1988;147(5):539-43.
5. Harbord MG, Baraitser M, Wilson J. Microcephaly, mental retardation, cataracts, and hypogonadism in sibs: Martsolf's syndrome. *J Med Genet* 1989;26(6):397-406.
6. Aligianis IA, Morgan NV, Mione M, Johnson CA, Rosser E, Hennekam RC, et al. Mutation in Rab3 GTPase-activating protein (RAB3GAP) noncatalytic subunit in kindred with Martsolf syndrome. *Am J Human Genet* 2006;78(4):702-7.
7. Bora E, Cankaya T, Alpman A, Karaca E, Cogulu O, Tekgul H, et al. A new case of Martsolf syndrome. *Genet Couns* 2007;18(1):71-5.
8. Ehara H, Utsunomiya Y, Ieshima A, Maegaki Y, Nishimura G, Takeshita K, et al. Martsolf syndrome in Japanese siblings. *Am J Med Genet* 2007;143A(9): 973-8.
9. Ainsworth JR, Morton JE, Good P, Woods CG, George ND, Shield JP, et al. Micro syndrome in Muslim Pakistan children. *Ophthalmology* 2001;108(3):491-7.
10. Kern FH, Ing RJ, Greeley WJ. Anesthesia for cardiovascular surgery. In: Motoyama EK, Davis PJ, eds. *Smith's Anesthesia for Infants and Children*. 7th ed. Philadelphia: Mosby Elsevier; 2006. p. 571-650.