

Acute Buried Bumper Syndrome: An Unexpected Complication: Case Report

Akut Gelişen Gömülü Tapa Sendromu: Beklenmedik Bir Komplikasyon

Ahmet Burak TOROS,^a
Ahmet BAŞEL,^b
Simru TUĞRUL,^b
Şafak KARAÇAY^c

Clinics of

^aGastroenterohepatology,

^bAnesthesia and Reanimation,

^cPediatric Surgery,

Liv Ulus Hospital, Istanbul

Geliş Tarihi/Received: 16.07.2013

Kabul Tarihi/Accepted: 02.12.2013

Yazışma Adresi/Correspondence:

Ahmet Burak TOROS

Liv Ulus Hospital,

Clinic of Gastroenterohepatology,

İstanbul,

TÜRKİYE/TURKEY

aburaktoros@yahoo.com

ABSTRACT Percutaneous endoscopic gastrostomy (PEG) is the modality of choice for providing long-term enteral nutrition in patients with inadequate oral intake. Although success rates of greater than 95% have been reported for PEG tube placement, procedure-related complications are common. Generally, Buried bumper syndrome is considered as a rare and late complication of PEG tube placement, occurring several months after placement. But in rare cases it can be seen as early as a week, in an acute manner. If not recognized and treated appropriately, it can lead to serious problems like gastric wall perforation and peritonitis. Here we report a case of an acute buried bumper syndrome, unique for its very short course of development.

Key Words: Endoscopy, gastrointestinal; endoscopy

ÖZET Yetersiz ağızdan beslenmesi olan hastalarda Perkütan endoskopik gastrostomi (PEG) açılması, uzun dönemde enteral beslenmeyi sağlamada seçkin çözüm haline gelmiştir. PEG tüpü takılması işleminin başarı oranları %95'in üzerinde olarak rapor edilse de, işlemle ilgili komplikasyon gelişmesi sık görülür. Genel olarak 'Gömülü tapa sendromu' PEG tüpü takılmasının nadir bir komplikasyonu olup, sıklıkla tüpün takılmasından sonra aylar içerisinde gelişir. Az sayıda vakada ise bir haftada bile oluşabilir ve akut gelişmiş bir komplikasyon olarak adlandırılır. Erken tanınıp gerektiği şekilde tedavisi yapılmazsa, mide duvarı delinmesi ve peritonit gibi ciddi sonuçlara yol açabilir. Burada, çok hızlı gelişmesi nedeniyle diğerlerinden ayrılan bir akut gelişmiş 'Gömülü tapa sendromu'nu sunuyoruz.

Anahtar Kelimeler: Endoskopi, gastrointestinal; endoskopi

Türkiye Klinikleri J Case Rep 2014;22(4):285-7

Since its introduction in the early 1980s, percutaneous endoscopic gastrostomy (PEG) has become the modality of choice for providing long-term enteral nutrition in patients with inadequate oral intake.¹ The main indication for PEG tube placement is neurologic dysphagia, which mostly develops secondary to stroke.² Pharyngeal or esophageal obstruction of mainly malignant origin, long-term gastric decompression and treatment of gastric volvulus are the other indications.³ PEG is a simple method for obtaining access to the stomach, while its morbidity and mortality are low.⁴ Complications related to PEG placement and feeding are traditionally stratified as major and minor.¹ Peristomal wound infection is the most common procedure-related complication and occurs in 5%-30% of patients.⁵

Buried bumper syndrome (BBS) is an unusual complication of PEG tube placement, occurring in about 1.5-1.9% of patients.⁶ This happens when excessive traction is applied to the PEG tube for an extended period. This traction leads to ischemic necrosis of the gastric mucosa and migration of the internal bumper into the gastric or abdominal wall.⁷ Typically, BBS is a chronic problem occurring after 3-6 months of PEG tube placement. Rare documented reports of BBS demonstrate cases occurring as soon as 5 to 30 days of PEG tube placement.^{8,9}

Traditional management of BBS involves establishing the gastrostomy tract with new PEG tube after removing the migrated old tube. Here we report a rare case of an acute BBS, resulting in removal of the PEG tube for preventing gastric wall perforation and left to spontaneous healing without a new tube placement.

CASE REPORT

A 57-year-old male, diagnosed with basillary artery thrombosis-acute infarction of the left brainstem, cerebellum and cerebellar peduncle; had been hospitalized at the Intensive Care Unit (ICU) of our hospital for 10 days. For further feeding, ICU doctors demanded the patient to have a PEG tube placed instead of parenteral feeding. The PEG tube placement was done without any problem and without prophyllaxis because the patient was already on broad-spectrum intravenous antibiotics.

3 days after the intervention, stoma leakage with feeding formulas (they were marked with food paint) was reported; we turned bolus feeding to a low-rate perfusion and added prokinetics for more effective gastric contractions. The stoma was not infected and the patient did not have any extra factors to impair wound healing (like diabetes mellitus, low albumin level, sepsis etc).

After 3 days without improvement, we decided to perform a repeat gastroscopy. During endoscopy, the bumper looked partially buried and when we pushed the tube inwards, the underlying gastric wall was deeply cavitated, fragile, weakened but not ulcerated or infected (Figures 1,2). To

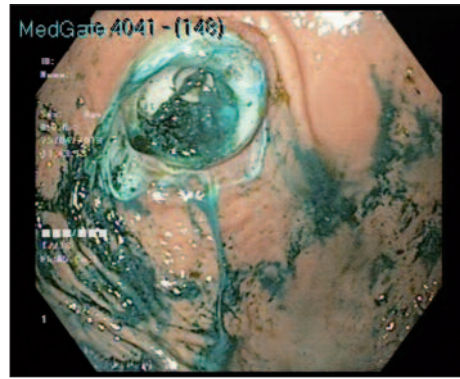


FIGURE 1: Bumper of the PEG catheter.

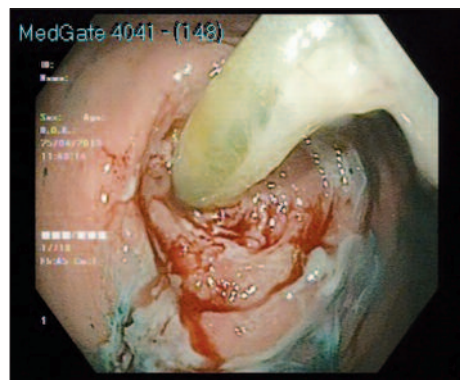


FIGURE 2: PEG tube and cavitation site.

avoid gastric wall perforation, we took the PEG tube out in the same session.

5 days later, we performed a second-look endoscopy and saw that the PEG tube insertion site was ulcerated. The patient is currently feeding with a nasogastric tube, we planned to place another PEG tube one week later, after the ulcer has healed.

DISCUSSION

Although success rates of greater than 95% have been reported for PEG tube placement, procedure-related complications are common. Generally, BBS is considered as a rare and late complication of PEG tube placement, occurring several months after placement. This occurs when excessive traction is applied to the PEG tube for an extended period. This traction leads to the ischemic necrosis of the gastric mucosa and migration of the internal

bumper into the gastric or abdominal wall. The reported incidence is 1.5-1.9%.^{7,9} If this problem is not recognized, BBS can lead to serious complications like gastric wall perforation, peritonitis, sepsis and even death.¹⁰

In a healthy or hospitalized but well-nourished patient, a gastrostomy tract is formed within 2-4 weeks.¹¹ In these cases, the risk of peritoneal leakage is high due to the incomplete formation of a gastrocutaneous fistula tract.¹² These patients usually present with abdominal pain and peritubal leakage. If one of these signs appear, gastroscopy is a must for definitive diagnosis. Ultrasonography or computerized tomography of the abdomen can also help in establishing the diagnosis.

In our case, stomal leakage without a wound site infection, which is not responsive to feeding with perfusion or prokinetics; led us to perform a gastroscopy for assessing the problem. The inner insertion area looked normal but when we pushed

the tube inwards, the underlying mucosa and muscle layer was observed as deeply cavitated and fragile, but without an ulcer or sign of infection. The most widely accepted treatment options include removal of buried tube and replacement with a new tube. But since the gastric wall was deeply cavitated in our case, we removed the PEG tube without replacing another one and left the site to heal. A control gastroscopy performed 5 days later, revealed a healing ulcer on the site. The patient is feeding with a nasogastric tube for now. We hope to place a new PEG tube for further feeding, after the ulcer is definitely healed.

To the best of our knowledge, this is one of the very few acute buried bumper cases reported in the literature, because most cases occur after several months, not in a few days after the procedure as we have reported. Frank peritonitis may not be present, persistent stomal leakage alone can be a reminder.

REFERENCES

1. Vanis N, Saray A, Gornjakovic S, Mesihovic R. Percutaneous endoscopic gastrostomy (PEG): retrospective analysis of a 7-year clinical experience. *Acta Inform Med* 2012;20(4): 235-7.
2. Koc D, Gercek A, Gencosmanoglu R, Tozun N. Percutaneous endoscopic gastrostomy in the neurosurgical intensive care unit: complications and outcome. *JPEN J Parenter Enteral Nutr* 2007;31(6):517-20.
3. Nicholson FB, Korman MG, Richardson MA. Percutaneous endoscopic gastrostomy: a review of indications, complications and outcome. *J Gastroenterol Hepatol* 2000;15(1): 21-5.
4. Hossein SM, Leili M, Hossein AM. Acceptability and outcomes of percutaneous endoscopic gastrostomy (PEG) tube placement and patient quality of life. *Turk J Gastroenterol* 2011;22(2):128-33.
5. Vargo JJ, Ponsky JL. Percutaneous endoscopic gastrostomy: Clinical applications. *Medscape General Medicine* 2000; 2 (4).
6. Venu RP, Brown RD, Pastika BJ, Erikson LW Jr. The buried bumper syndrome: a simple management approach in two patients. *Gastrointest Endosc* 2002;56(4):582-4.
7. Gençosmanoğlu R, Koç D, Tözün N. The buried bumper syndrome: migration of internal bumper of percutaneous endoscopic gastrostomy tube into the abdominal wall. *J Gastroenterol* 2003;38(11):1077-80.
8. Khalil Q, Kibria R, Akram S. Acute buried bumper syndrome. *South Med J* 2010;103(12):1256-8.
9. Bhat G, Suvarna D, Pai CG. Acute buried bumper syndrome: an endoscopic peg tube salvage approach. *Indian J Med Sci* 2010;64 (5):234-6.
10. McClave SA, Jafri NS. Spectrum of morbidity related to bolster placement at time of percutaneous endoscopic gastrostomy: buried bumper syndrome to leakage and peritonitis. *Gastrointest Endosc Clin N Am* 2007;17(4): 731-46.
11. Mellinger JD, Simon IB, Schlechter B, Lash RH, Ponsky JL. Tract formation following percutaneous endoscopic gastrostomy in an animal model. *Surg Endosc* 1991;5(4):189-91.
12. Marks JM, Ponsky JL, Pearl JP, McGee MF. PEG "Rescue": a practical NOTES technique. *Surg Endosc* 2007;21(5):816-9.