

Atypical Presentation of Menetrier's Disease in a Child with Recurrent Abdominal Pain

Tekrarlayan Karın Ağrısı Olan Çocuk Hastada Menetrier Hastalığının Olağan Dışı Tutulumu

Emrah AYDIN^a

^aBahçelievler State Hospital, İstanbul

Geliş Tarihi/Received: 17.10.2016
Kabul Tarihi/Accepted: 14.12.2016

Yazışma Adresi/Correspondence:

Emrah AYDIN
The Center for Fetal, Cellular & Molecular Therapy, Cincinnati Fetal Center, Cincinnati Children's Medical Center, Division of Pediatric General and Thoracic Surgery, Ohio, USA/ABD
dremrahaydin@yahoo.com

ABSTRACT A 13 years old girl admitted due to epigastric pain. She had a history of osteoid osteoma operation and a cousin diagnosed as familial adenomatosis polyposis. She was found to have polypoid structures beginning from antrum to the end of the first part of duodenum at gastroduodenoscopy which are reported as parietal hyperplasia. Her complaints were increased with proton pump inhibitor treatment and two more gastroduodenoscopy were needed to be diagnosed as Menetrier's disease. No etiologic factor could be demonstrated. She's been followed for the last year.

Keywords: Gastritis, hypertrophic; parietal cells, gastric; abdominal pain; child

ÖZET On üç yaşında kız olgu epigastrik ağrı nedeni ile kliniğimize yönlendirildi. Olgunun anamnezinde osteoid osteoma nedeni ile ameliyat olduğu ve kuzeninde ailesel adenomatoz polipozis hastalığı bulunduğu öğrenildi. Yapılan endoskopisinde antrumdan duodenum 1. kısma kadar olan bölümde polipoid yapılar saptandı. Alınan biyopsi örneklerinin sonuçları pariyetal hiperplazi olarak raporlandı. Proton pompa inhibitörü tedavisi ile şikayetleri artan olguya iki endoskopi daha yapıldıktan sonra Menetrier hastalığı tanısı konuldu. Altta yatan faktör belirlenemedi. Olgu son 1 yıldır takip edilmektedir.

Anahtar Kelimeler: Gastrit, hipertrofik; paryatel hücreler, gastrik; karın ağrısı; çocuk

For the video/videos of the article:



Menetrier's disease is characterized by giant mucosal pili, foveolar hyperplasia, glandular atrophy and increased mucosal thickness at greater curvature of fundus and corpus of the stomach since its first recognition at 1888 by Menetrier.¹ It is generally observed in adults with a peak at 40-60 years old age and 3 times more common in women. There has been no shown genetic predisposition but also many cases presented as familial outbreaks.² *Helicobacter pylori* is one of the most common precipitating cause in adulthood. Even it is uncommon in childhood; allergy, autoimmunity and cytomegalovirus (CMV) infection can accompany to the disease.³ Abdominal pain, emesis, periorbital edema, atypical lymphocytosis, transient hepatosplenomegaly, eosinophilia and transient protein loose may be the presenting symptoms in childhood.

Herein, we present a case with atypical presentation and clinical findings in the beginning and could only be diagnosed at the follow-up with repetitive upper gastrointestinal endoscopy.

CASE REPORT

A 13-year-old girl referred to the outpatient clinic department due to recurrent abdominal pain for the last two months. The pain was located mainly at epigastric region. She had regular menstruation periods for the last year. She was operated at her right femur due to osteoid osteoma two years before admission. Her mother and aunt had renal calculi. Her cousin had operated because of familial adenomatosis polyposis. Her physical examination revealed nothing except she was at between 25-50th percentiles according to the percentiles for weight for age. All laboratory values including complete blood count, biochemistry, hormone profile, urine analysis and tumor markers were normal. Abdominal ultrasonography revealed 4,5 cm ovarian cyst and mild hydronephrosis at his left kidney. Upper and lower gastrointestinal system contrast series were normal. Abdominopelvic magnetic resonance imaging (MRI) was normal except 4 cm simple ovarian cyst. Consultation with gynecologist did not reveal any pathology. Ovarian cyst was resolved completely at follow up. Upper and lower gastrointestinal endoscopy were performed. Colonoscopy findings were totally normal. There were polypoid structures beginning from antrum to the end of the first part of duodenum at the gastroduodenoscopy. (Figure 1) All other parts of esophagus, stomach and duodenum were found to

be normal. Tissue samples were biopsied from polypoid structures. Pathology was reported as parietal hyperplasia. Cytogenetic analysis for familial adenomatosis polyposis was performed (Table 1). She was found to have a mutation at APC gene called rs11432316. But at dbSNP database it was classified under the unknown effect part. Proton pump inhibitor treatment was started. But the severity of her complaints increased after this treatment. Especially 2-3 hours after she took the pills she had a severe epigastric pain. Approximately 4 months after the previous gastroscopy, another one was performed. Similar findings were found. There was no evidence of either increase or decrease of the severity of lesions. Pathology was reported as chronic gastritis, chronic inflammation (+) and lymphoid aggregate (++). *Helicobacter pylori* couldn't be demonstrated and lymphoma could not be demonstrated at histopathologic workup. Anti-histaminic and anti-inflammatory drugs were added to the treatment. At follow up proton pump inhibitors were replaced by H₂ receptor antagonist. Six months after second gastroscopy another one was performed. Almost the same findings were observed. The only difference is that duodenum's 1st part was better than the former one (Video 1). Biopsy was taken and it was reported as chronic gastritis, focal activation, chronic inflammation (+/+++), glandular atrophy (+/+++), *Helicobacter pylori* (+/+++), and foveolar hyperplasia (++) (Table

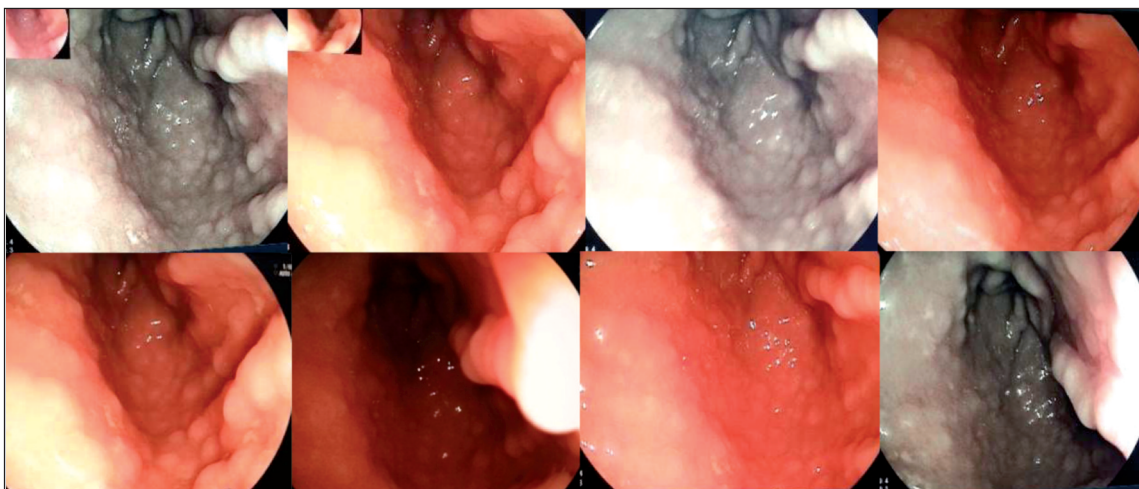


FIGURE 1: Endoscopic view of the antrum and 1st part of duodenum.

TABLE 1: Molecular analysis for familial adenomatous polyposis.

Location	Change of nucleotid	Change of protein	Change of genotype	dbSNP ID	Global allele frequency
5:112180228	c.*405_*406insA	-	het	rs34829795 rs11432316	-

2). The diagnosis of Menetrier's Disease was established according to the histopathologic findings. Antibiotics for *Helicobacter pylori* and tumor growth factor alpha (TGF- α) monoclonal antibodies were added to the treatment. Since then, she has been followed-up. Her symptoms' severity was decreased but still continues.

DISCUSSION

Menetrier's disease is an uncommon subtype of hyperplastic gastropathy. There have been many reports regarding Menetrier's disease since 1888 but its pathophysiology is not completely understood. Patients mostly have abdominal pain, emesis and loss of weight. It's suspected mostly when enlarged mucosal folds seen on the endoscopy especially in adulthood. There are some studies showing increased TGF- α levels at gastric mucus cells and successful treatment with TGF- α monoclonal antibodies.⁴⁻⁶ Treatment for underlying disease if there is one such as *Helicobacter pylori* or CMV infection, is necessary. Differential diagnosis should be done with Zollinger Ellison syndrome, pure *Helicobacter pylori* infection, hypertrophic hypersecretuar gastropathy, hyperplastic polyps and lymphoma.

The presentation of our case looked like Gardner syndrome due to ovarian cyst, osteoma and family history of colon carcinoma due to polyposis. Patient lost weight to some degree and her weight for age percentile was between 25-50th. Endoscopy for lower gastrointestinal system was completely normal. Even cytogenetic analysis for familial adenomatous polyposis was not normal, it couldn't demonstrate a FAP mutation. At follow up, the ovarian cyst completely resolved. This was the most complicating part for diagnosis. Clinical presentation and endoscopic view of the patient was favorable for FAP but it could not be demonstrated by karyotype analysis.

TABLE 2: Histopathologic results of the biopsies.

	1 st Gastroscopy	2 nd Gastroscopy	3 rd Gastroscopy
Chronic gastritis	+	+	+
Activation	+	?	+
Atrophy	-	-	+/++
Intestinal metaplasia	-	-	-
<i>Helicobacter pylori</i>	-	-	++/+++
Chronic inflammation	+	+	++/+++
Lymphoid aggregation	+	++	-

There are many causes of abdominal pain in childhood one of which is urinary problems. At the initial ultrasonography there was mild hydronephrosis. Regarding that there was a family history of renal calculi she was investigated for urinary problems. There was no additional pathology found and hydronephrosis resolved in following ultrasonographies

Because lymphoid aggregation was increased at the second gastroscopy and there was history of malignancy, lymphoma was suspected. Oncologic work-up did not reveal any pathology. The polypoid structures those found in gastroscopy may also be seen in different diseases such inflammatory bowel diseases, infectious process and malignancy. She did not have any sign or symptoms of inflammatory bowel diseases. Also there is no additional finding at both upper and lower endoscopy regarding it. Septic markers and viral serology was in normal limits. There had been no finding for *Helicobacter pylori* till the last gastroscopy. She was treated specifically for *Helicobacter pylori*. It was thought that there may be an allergic component which may cause this structures as in eosinophilic esophagitis. Antihistaminic and anti-inflammatory treatment was included in the treatment. Due to

findings at the last gastroscopy, TGF- α monoclonal antibodies were also added to the treatment.

Menetrier's disease may be presented in childhood different than the adulthood. Antrum was involved in children. There may be CMV infection accompanying the disease or allergy may be found. Children with Menetrier's disease may have the symptoms such as atypical lymphocytosis, transient splenomegaly, eosinophilia and protein lose which is self-limited. Even the prognosis of the disease is not favorable in adults it is mostly self-limited in childhood. In our case, none of these symptoms were present. Even many treatment modalities were performed there has been no complete relief of the symptoms. The patient did not have some clinical features of the Menetrier's Disease. However, inability to demonstrate any other disease that may cause these symptoms; foveolar hyperplasia and moderate inflammation at histopathologic specimens suggest the diagnosis of Menetrier's

Disease. After initiation of TGF- α monoclonal antibodies, her symptoms moderately relieved.

In the literature, there are some studies describing the similar lesions at antrum with increase of pain after proton pump inhibitor therapy as the Menetrier's disease. Komorowsky et al. stated at their studies that of 52 patients with hyperplastic gastropathy 8% diagnosed as Menetrier Disease, 10% Zollinger Ellison syndrome, 12% malignancy, 30% benign tumors and 40% chronic gastropathy and lymphoid hyperplasia.⁷

Conflict of Interest

Authors declared no conflict of interest or financial support.

Authorship Contributions

All authors have made substantial contributions to the conception and design of the study, acquisition, drafting the article and revising it for important intellectual content and final approval of the version to be submitted.

REFERENCES

1. Menetrier P: Des polyadenomas gastriques et de leurs rapports avec le cancer de l'estomac. Arch Physiol Norm Pathol 1888; 1:322-36.
2. Ibarolla C, Rodriguez-Pinilla M, Valiño C, Gomez-Casado E, Garcia de la Torre JP, Rodriguez-Cuellar E, et al. An unusual expression of hyperplastic gastropathy (Ménétrier type) in twins. Eur J Gastroenterol Hepatol 2003;15(4):441-5.
3. Hoffer V, Finkelstein Y, Balter J, Feinmesser M, Garty BZ. Ganciclovir treatment in Ménétrier's disease. Acta Pediatr 2003;92(8): 983-5.
4. Dempsey PJ, Goldenring JR, Soroka CJ, Modlin IM, McClure RW, Lind CD, et al. Possible role of transforming growth factor alpha in the pathogenesis of Ménétrier's disease: Supportive evidence from humans and transgenic mice. Gastroenterology 1992;103(6): 1950-63.
5. Settle SH, Washington K, Lind C, Itzkowitz S, Fiske WH, Burdick JS, et al. Chronic treatment of Ménétrier's disease with Erbitux: clinical efficacy and insight into pathophysiology. Clin Gastroenterol Hepatol 2005;3(7):654-9.
6. Burdick JS, Eunkyung C, Tanner G, Sun M, Paciga JE, Chenq JQ, et al. Treatment of Ménétrier's disease with a monoclonal antibody against the epidermal growth factor receptor. N Engl J Med 2000;343(23): 1697-703.
7. Komorowsky RA, Caya JG, Green JE. The morphologic spectrum of large gastric folds: utility of snare biopsy. Gastrointest Endosc 1986;32(3):190-2.