

# Autogenous Iliac Crest Bone as Grafting Material to Improve Paranasal Contour Deficiency: Case Report

## Paranasal Kontur Yetersizliğinin Düzeltilmesi İçin Otojen İliak Kemik Grefti Uygulanması

Fidan ALAKUŞ SABUNCUOĞLU,<sup>a</sup>  
Metin ŞENÇİMEN,<sup>b</sup>  
Altan VAROL<sup>c</sup>

<sup>a</sup>Clinic of Orthodontics Dentistry,  
Mareşal Çakmak Military Hospital,  
Erzurum

<sup>b</sup>Department of Oral Surgery,  
GATA Dental Sciences Center,  
Ankara

<sup>c</sup>Department of Oral and  
Maxillofacial Surgery,  
Marmara University Faculty of Dentistry,  
İstanbul

Geliş Tarihi/Received: 05.03.2011  
Kabul Tarihi/Accepted: 25.04.2011

Yazışma Adresi/Correspondence:  
Fidan ALAKUŞ SABUNCUOĞLU  
Mareşal Çakmak Military Hospital,  
Clinic of Orthodontics Dentistry, Erzurum,  
TÜRKİYE/TURKEY  
fidansabuncuoglu@yahoo.com.tr

**ABSTRACT** This article reports the treatment of an 25-year old male patient with Class III malocclusion and contour deficiency of bilateral paranasal area. Le Fort I advancement and bilateral sagittal split ramus osteotomy (BSRO) were performed and additionally iliac bone graft was applied on bilateral paranasal area. After treatment, the changes in the profile are more satisfactory with iliac bone graft application. Paranasal augmentation with iliac bone block grafting is an effective technique to achieve a favourable soft tissue support and esthetic facial appearance of the patient.

**Key Words:** Surgery, oral; esthetics, dental

**ÖZET** Bu çalışmada, çift taraflı paranasal bölgede kontural yetersizliği olan ve Sınıf III maloklüzyon gösteren 25 yaşındaki erkek hastanın tedavisi sunulmaktadır. Hastanın estetiği ve güzel bir yumuşak doku desteği için Le Fort I ve bilateral sagittal split ramus osteotomi (BSRO) ile beraber aynı anda çift taraflı paranasal bölgeye iliak kemik grefti uygulanmıştır. Tedavi sonrası memnun edici profil değişikliği elde edilmiştir. İliak kemik grefti ile paranasal bölgenin desteklenmesi, arzu edilen yumuşak doku desteği ve hastanın fasiyal estetik görünümünün sağlanması noktasında oldukça etkili bir yöntemdir.

**Anahtar Kelimeler:** Cerrahi, oral; estetik, dişsel

**Türkiye Klinikleri J Dental Sci 2012;18(3):375-81**

Successful surgical planning and accurate prediction of orthognathic surgery outcomes include not only occlusal correction and a well-balanced skeletal relationship, but the improvement of esthetics and function as well. For this reason, the prediction of postsurgical soft tissue changes is a crucial part of the presurgical treatment planning process.<sup>1</sup>

Generally, the changes at the superior and inferior aspects of the profile, such as nasion and pogonion, have shown more predictable patterns than those of the midfacial areas, such as the nose and lips. Soft tissue thickness or the muscular tonicity in the midfacial region could account for localized differences.<sup>2,3</sup> But paranasal contour is responsible for the shape of the lateral segment of the middle third of the face. Attractive paranasal prominence are important in the concept of youth and beauty. It is well known that strong cheekbones make the face appear youthful. Augmentation has been proposed to improve the facial attractiveness of patients with paranasal deficiency, to create a more youthful-looking face.<sup>4</sup>

This report describe simultaneous iliac graft augmentation and orthognathic surgery to correct paranasal deficiency and Class III malocclusion case.

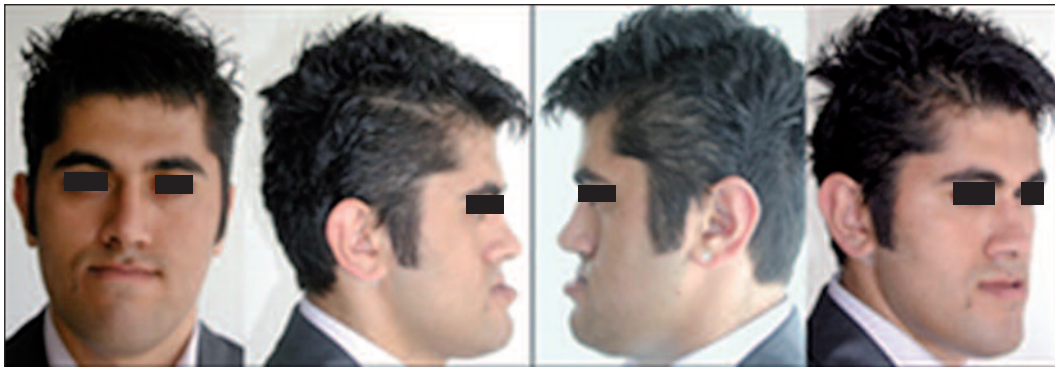## CASE REPORT

### DIAGNOSIS

The patient presented with a chief complaint of dissatisfaction with his facial apperance (Figure 1). General physical health was excellent and no disabilites reported and observed. Postero-anterior and lateral cephalometric, panoramic and intra-extraoral photographs of the 25-years-old male patient were taken before the treatment. The panoramic radiograph confirmed that the upper left

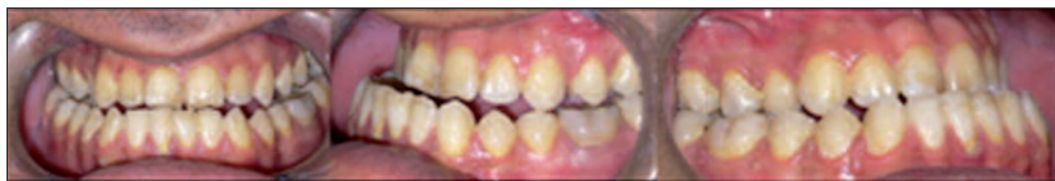and lower right first molar teeth were absent and the presence of left extra upper permanent teeth. The alveolar bone height and the root length of all teeth were normal (Figure 2). Soft tissue assessment revealed a prominent chin point and inadequate paranasal contours. The lower lip is protruded relatively to the upper lip.

Intraoral examination revealed a Class III malocclusion with an excessive negative overjet. Oral hygiene was fair and the patient has generalized marginal gingivitis. The frenal attachments were normal and the tongue was of normal size and function. The maxillary and mandibular arch forms were U-shaped and moderate anterior crowding was observed (Figure 3).



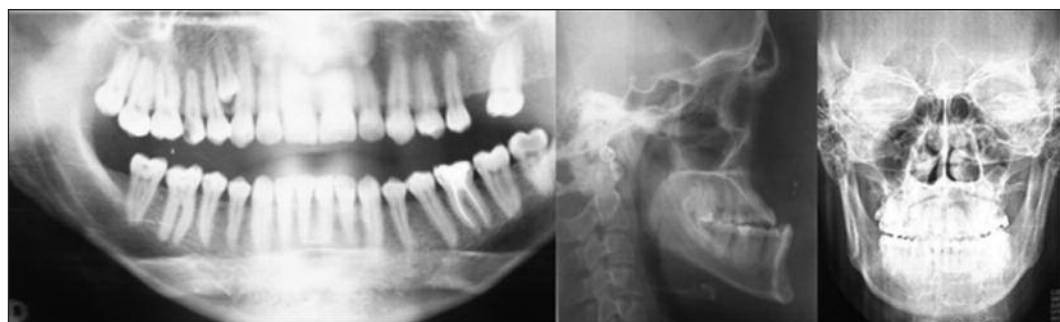**FIGURE 1:** Pre-treatment extraoral views.

(See for colored form <http://dishekimligi.turkiyeklinikleri.com/>)

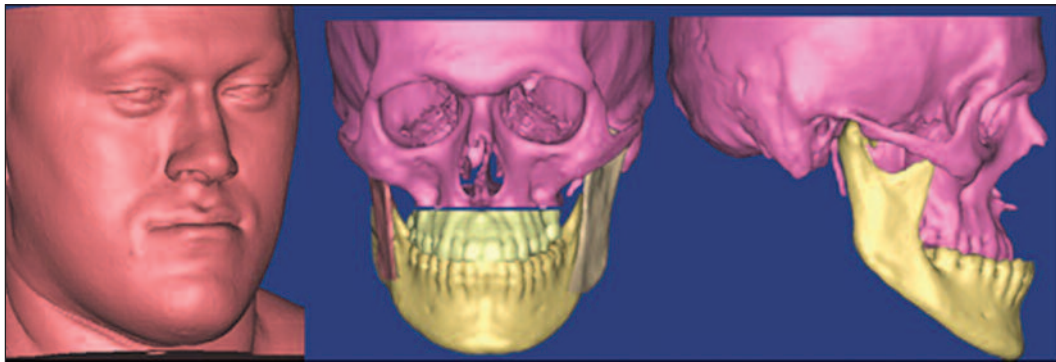


**FIGURE 2:** Pre-treatment-intraoral views.

(See for colored form <http://dishekimligi.turkiyeklinikleri.com/>)



**FIGURE 3:** Pre-treatment-radiographs views.



**FIGURE 4:** Pre-treatment-3 dimensional biomodel.  
(See for colored form <http://dishekimligi.turkiyeklinikleri.com/>)

To determine the skeletal deformity, cephalometric analysis and 3-D CT images of the patient were acquired (Figure 4). The lateral cephalometric analysis showed a skeletal Class III with an ANB angle of -12°. The anterior facial height was 144 mm, posterior facial height was 102 mm and the ratio of these values was 70% revealing that the patient had a short face (Table 1).

After evaluation of the records, mandibular anteroposterior excess, a maxillary anteroposterior deficiency and paranasal contour deficiency were detected.

**TREATMENT PLANNING**

The treatment planning of a difficult malocclusion that required comprehensive orthodontics with surgical intervention are presented. BSRO, Le Fort I and simultaneous iliac graft augmentation was performed to improve paranasal contour deficiency to achieve an ideal occlusal relationship and improve his chewing function.

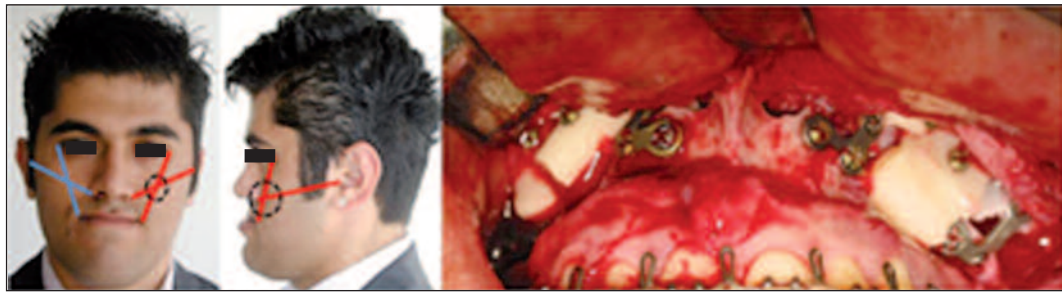**LOCATION OF THE PARANASAL GRAFTS**

Mladick’s method was used to achieve the proper position of iliac graft.<sup>4</sup> According to this method, one line is traced from the ala to the tragus and another line from the lateral canthus to the commissure. The crossing point is used as the reference point for symmetrical iliac graft placement (Figure 5). The malar prominence is generally located near this point.

**TABLE 1:** Cephalometric analysis of case.

	Preoperative	Immediate post-surgical	Final
SNA	83°	85°	86°
SNB	95°	87°	87°
ANB	-12°	-2°	-1°
NV-A	-3 mm	+1 mm	+1 mm
NV-Pog	+22 mm	+12 mm	+11 mm
S-N	78 mm	78 mm	78 mm
Go-Gn	90 mm	80 mm	80 mm
SN/ ANS-PNS	9	12	12
SN/Go-Gn	24°	31°	33°
ANS-PNS/Go-Gn	15°	19°	21°
SN/Occlusal plane	10	13	13
N-Me	144 mm	148 mm	148 mm
N-ANS	65 mm	67 mm	65 mm
ANS-Me	78 mm	82 mm	84 mm
S-Go	102 mm	105 mm	105 mm
S-Go/ N-Me	%70	%70	%70
1/SN	120°	117°	116°
1/Go-Gn	77°	78°	79°
1/1	131°	137°	135°
1/NA	10 mm	9 mm	8 mm
1-NA	35°	30°	27°
1/NB	3 mm	4 mm	4 mm
1-NB	16°	13°	16°

SNA; The angle between the anterior cranial base (SN) and NA line, SNB; The angle between the anterior cranial base (SN) and NB line, ANB; Interrelation of maxilla and mandible, NV-A; The perpendicular distance from A point to the N perpendicular line to FH plane, NV-Pog; The perpendicular distance from Pog point to the N perpendicular line to FH plane, S-N; Sella-Nasion plane, S; The angle between N-S line and S-Ar line, Ar; The angle between S-Ar line and Ar-Go line, Go; The angle between Ar-Go line and Go-Me line, Ar-Go: Ar-Go line, Go-Gn; Go-Gn line, Y Axis; The angle between FH plane to Sella-Gnathion plane, SN/Occ; SN plane to occlusal plane, SN/Go-Gn; SN plane to mandibular plane, Co-A; effective mid-facial length, Co-Pog; effective lower face length, N-Me; total anterior face height, N-ANS; Upper anterior face height, ANS-Me; Lower anterior face height, S-Go; total posterior face height, S-Go/ N-Me; Ratio of total posterior face height to total anterior face height, 1/SN; The angle between upper incisor axis line and SN plane, 1/Go-Gn; The angle between lower incisor axis line and mandibular plane, 1/1; The angle between upper and lower incisor axis lines, 1/NA; maxillary incisor to N-A line, 1-NA; maxillary incisor to N-A angle, 1/NB; mandibular incisor to N-A line, 1-NB; mandibular incisor to N-A angle



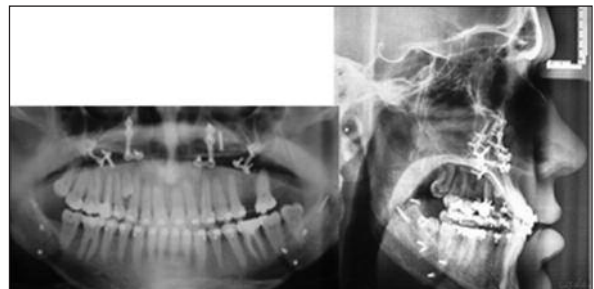**FIGURE 5:** Surgical phase, intraoral view of iliac bone augmentation with screw fixation, location of the paranasal grafts. (See for colored form <http://dishekimligi.turkiyeklinikleri.com/>)

## TREATMENT PROGRESS

Following patient acceptance of 'Informed Consent Form', treatment was initiated. After upper right first premolar had undergone endodontic treatment and periodontal treatment, orthodontic treatment began with the fitting of upper and lower pre-adjusted edgewise appliances of 0.018-inch slot. The arches were banded and bonded and the teeth levelled and aligned. Following the levelling phase, 0.016x0.022 inch arch wires were placed on the upper and lower teeth. The first phase required 7 months to level, align, and coordinate the arches and to reduce the dental compensations by proclining the lower incisors.

The required final orthodontic adjustments and full size stabilizing arcwires were placed and kept for 3 to 4 weeks to become passive before pre-surgical records have been taken. After passive treatment, upper and lower impressions and a facebow registration was taken. Model surgery is performed. Maxillary Le Fort I advancement (4 mm), mandibular bilateral sagittal split osteotomy (10 mm) and iliac augmentation for paranasal deficiency was performed (Figure 5).

Following the surgery, settling was accomplished with light round wires and vertical elastic mechanics. The patient's cephalometric analysis were re-examined (Figure 6, Table 1). The treatment was concluded in 18 months. Immediately after the removal of the fixed appliances, essix retainers were placed, and the patient was asked to wear them full time for 6 months and at night thereafter



**FIGURE 6:** Radiographs after surgical phase.

## SURGERY PROGRESS

Double jaw surgery was performed virtually and aesthetic predictions were calculated with soft-simulation option of the software. DICOM tomographic data was obtained from the patient for computer aided surgery (CAD) and 3-D simulation with Mimics® (Materialise, Lueven-Belgium) software. Skeletal deficiency in paranasal caused many queries in terms of skeletal reconstruction. As a result of Mimics simulation, only autogenous iliac bone grafting for paranasal augmentation should be performed following Le Fort I advancement was planned. Following accomplishment of routine bimaxillary osteotomy operation, regio iliaca was disinfected by a 5% dextrose solution 5 mm long skin incision running from spina iliaca anterior to spina iliaca posterior was performed. Two each, having 2 x 3 cm diameter, corticocancellous block bone grafts were transferred to maxillary paranasal region by using titanium screws for fixation (Figure 5). Donor iliac region was closed primarily. Alar cinch suture was applied to nasal extensions in order to minimize the effect of maxillary advancement on nasal pro-

jection. Antibiotics (amoxicillin and clavulanate, 1 g) were given peri-operatively and until the sixth postoperative day. Subsequently, no problems were detected. After surgery, post-surgical orthodontics was carried out to establish the final occlusal relationship.

There were no complications during the follow up period. From this study it is seen that paranasal reconstruction can be performed using anterior iliac bone to obtain acceptable esthetic and functional results. Correlations improved generally from subnasale, soft tissue pogonion, upper and lower lips in both sagittal and vertical directions. Facial photographs showed that overall facial balance was improved (Figure 7). The pretreatment and posttreatment cephalometric data for the cases were summarized in Table 1.

## RESULTS

The results showed that the cephalometric variables were normalized after surgery (Table 1).

In the sagittal plane, the following skeletal changes were observed:

1. Preoperative anterior mandibular growth confirmed by SNB and NV-Pg increased was significantly reduced and preoperative SNA angle largely increased after surgery.

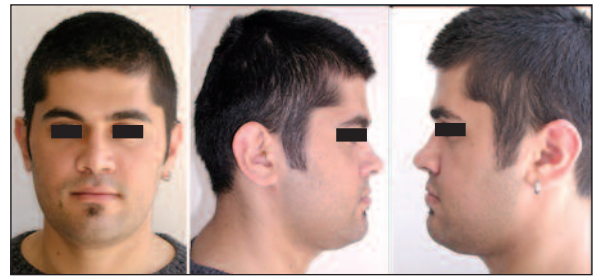

FIGURE 7: Post-treatment extraoral-views.  
(See for colored form <http://dishekimligi.turkiyeklinikleri.com/>)

2. The protrusion of the upper lip was correlated with the increases in SNA angle and N-A distance and also with the decrease in SNB angle.

3. The retrusion of the lower lip was correlated with the decrease in N-B distance.

4. The mandibular plane (SN/Go-Gn) angle increase as a result of surgery.

5. The mean overjet and maxillary and mandibular incisor inclinations increased significantly as a result of treatment.

An acceptable occlusion was achieved (Figure 8). Panoramic radiograph showed no root resorption (Figure 9). Correction of the skeletal deformity improved the patient's speech and pronunciation. As an added benefit, the patient reported a better

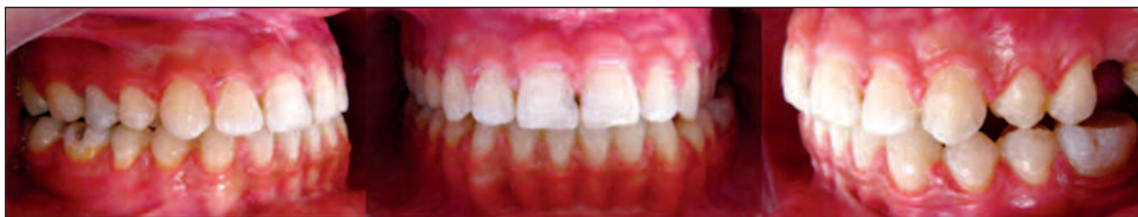

FIGURE 8: Post-treatment intraoral-views.  
(See for colored form <http://dishekimligi.turkiyeklinikleri.com/>)

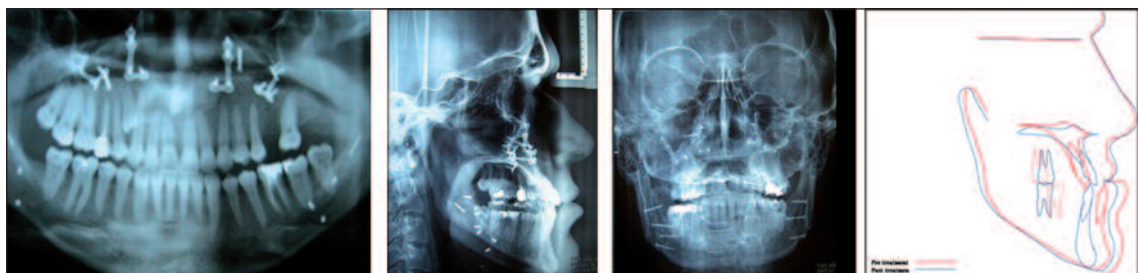

FIGURE 9: Post-treatment-radiographs views and superimposed pretreatment and posttreatment.  
(See for colored form <http://dishekimligi.turkiyeklinikleri.com/>)

self-esteem and a greater degree of pleasure related to his appearance.

## DISCUSSION

Dental clinicians must remember to study on the paranasal prominences routinely for the facial analysis. Various techniques to osteotomize the zygomatic complex and increase malar width have been described in the literature.<sup>4-6</sup>

In naso-maxillary deficiencies, treatment is accomplished by high-level nasomaxillary osteotomies and autogenous grafting. However, use of high osteotomies can present technical difficulties such as large advancements and additional aesthetic distortions of the nasal region. Autogenous bone has been widely used for maxillofacial reconstructive procedures, because of its powerful osteogenic stimulus, rapid reliable bone formation and nonimmunogenic properties. It has been considered the "gold standard" because it is the only bone graft that provides mechanisms for osteoconduction, osteoinduction, and osteogenesis. There are multiple intra- and extra-oral sites for harvesting autogenous bone, but all are associated with postoperative morbidity of the donor site. The high number of prosthetic hip replacements performed nowadays means that iliac crest bone is available as a potential source of grafting material.<sup>7</sup> We prefer onlay autogenous iliac bone grafting for paranasal augmentation in double jaw surgeries because of existing risks of graft harvesting from intraoral donor sites.

Within the ilium, grafts may be harvested from either its anterior or posterior crest. When a larger volume of bone is required, the posterior iliac crest should be considered.<sup>7,8</sup> The posterior ilium provides a greater quantity of both cortical and cancellous bone with less morbidity than the lateral approach to the anterior ilium.<sup>9</sup> However, a major disadvantage of the posterior approach is the need to turn the patient intra-operatively from the spine to the prone position, thus leading to increased operating time plus the risk of injury to the pa-

tient during the change of operating position. Utilizing the anterior ilium allows the graft harvest to be performed simultaneously with the preparation of the recipient site, thereby reducing operative and anaesthetic time. In addition keep in mind, virtually all bone graft undergo some degree of resorption.<sup>10</sup> Swan and Goodacre studied the complications of iliac bone harvesting in 72 patients.<sup>11</sup> The postoperative donor site complications included persistent pain at the donor site in 7% of cases (all resolved within 6 months), and superficial wound infections in 3% of cases (successfully treated with oral antibiotics). A single case of persistent numbness of the scar was reported, and another patient complained of a hyperaesthetic scar. Half of the patients reported a limp postoperatively. This was universally self-limiting with no reports of long-term gait disturbance. The overall complication rate was 13%, but no serious complications arose.

Onlay iliac graft reconstruction was proposed for maxillonasal dysplasia (Binder's syndrome) and concomitant deformity of paranasal area.<sup>12</sup> The use of allogeneic frozen bone grafts (e.g. derived from femoral heads), has been described in oral and maxillofacial surgery, but these allogeneic grafts bear the inherent risk of disease transmission.<sup>9</sup> Alloplastic augmentation is a relatively recent procedure. Advantage of using alloplasts is prevention from secondary operative field, however implant related complications, which are infection host-site foreign body reaction, displacements into maxillary sinus or orbital cavity, lacrimal duct obstructions and underlying bone resorption limit application of these materials.

In our experience, augmentation of the paranasal in association with orthognathic surgery has proved to result into a high degree of certainty of outcome. But long-term follow up is necessary before definitive conclusions about the response of the grafted bone can be made, but short-term results were promising.

## REFERENCES

1. Proffit WR, White RP. Treatment planning: the search for wisdom. *Surgical Orthodontic Treatment*. 1<sup>st</sup> ed. St Louis: Mosby-Year Book; 1991. p.142-91.
2. Yücel G, Marşan G, Cura N, Hocaođlu E. Treatment of a patient with a severe Class III and open bite: a case report. *World J Orthod* 2009;10(1):57-66.
3. Enacar A, Aksoy AÜ. [Profile changes following orthognatic surgery in skeletal class III patients]. *Turkish Journal of Orthodontics* 1988; 1(1):80-9.
4. Maas CS, Merwin GE, Wilson J, Frey MD, Maves MD. Comparison of biomaterials for facial bone augmentation. *Arch Otolaryngol Head Neck Surg* 1990;116(5):551-6.
5. Uçkan S, Ataođlu H, Durmuş E. [Intraoral ver-  
tical ramus osteotomy for the management of mandibular prognatism]. *Turkiye Klinikleri J Dental Sci* 2002;8(1):52-6.
6. Başıftıçı FA, Orhan M, Uçkan S, Üşümez S. [Combined orthodontic-surgical approaches in skeletal class III cases (two case reports)]. *Turkiye Klinikleri J Dental Sci* 2001;7(3):138-44.
7. Mrazik J, Amato C, Leban S, Mashberg A. The ilium as a source of autogenous bone for grafting: clinical considerations. *J Oral Surg* 1980; 38(1):29-32.
8. Bloomquist DS, Feldman GR. The posterior ilium as a donor site for maxillo-facial bone grafting. *J Maxillofac Surg* 1980;8(1):60-4.
9. Marx RE, Morales MJ. Morbidity from bone harvest in major jaw reconstruction: a randomized trial comparing the lateral anterior and posterior approaches to the ilium. *J Oral Maxillofac Surg* 1988;46(3):196-203.
10. Tayapongsak P, Wimsatt JA, LaBanc JP, Dolwick MF. Morbidity from anterior ilium bone harvest. A comparative study of lateral versus medial surgical approach. *Oral Surg Oral Med Oral Pathol* 1994;78(3):296-300.
11. Swan MC, Goodacre TE. Morbidity at the iliac crest donor site following bone grafting of the cleft alveolus. *Br J Oral Maxillofac Surg* 2006;44(2):129-33.
12. Holmström H, Kahnberg KE. Surgical approach in severe cases of maxillonasal dysplasia (Binder's syndrome). *Swed Dent J* 1988;12(1-2):3-10.