

Letrozole Induced Linear Lichenoid Eruption in a Patient with Breast Cancer: Case Report

Meme Kanseri Tanılı Hastada Letrozol ile İndüklenen Lineer Likenoid Erüpsiyon

Ayşe ÖKTEM,^a
Pınar İNCEL UYSAL,^a
Ferda ARTÜZ,^a
Fatma YILMAZ ERTÜRK^b

Clinics of
^aDermatology,
^bPathology,
Ankara Numune Training and
Research Hospital, Ankara

Geliş Tarihi/Received: 24.07.2015
Kabul Tarihi/Accepted: 05.04.2016

Yazışma Adresi/Correspondence:
Ayşe ÖKTEM
Ankara Numune Training and
Research Hospital,
Clinic of Dermatology, Ankara,
TÜRKİYE/TURKEY
ayseoktem@yahoo.com

ABSTRACT Letrozole which acts as an aromatase inhibitor is used in the treatment strategy for oestrogen receptor-positive breast cancer. Cutaneous adverse effects including vasculitis and erythema nodosum of letrozole have been rarely described in literature. Recently reported eczematous skin eruption due to letrozole is one of the side effects that known to be developed by this drug. To our knowledge letrozole induced linear drug eruption has not been described in previous reports. We report 52-year-old woman who had unilateral pruritic lichenoid eruption over left thigh following Blaschko lines after using letrozole. Cutaneous side effects of aromatase inhibitors can be serious as progressive cutaneous vasculitis or can be presented with mild cutaneous side effects as in our case. The physicians should be aware of this benign clinical condition. The decision to discontinue medication is dependent to the knowledge of severity of the side effects.

Key Words: Letrozole; lichenoid eruptions; aromatase inhibitors

ÖZET Aromataz inhibitörü olarak etki gösteren letrozol, östrojen reseptörü pozitif meme kanserinde kullanılan tedavi seçeneğidir. Letrozol kullanımına bağlı gelişebilen vaskülit ve eritema nodosum gibi kutanöz yan etkiler nadiren de olsa bildirilmektedir. Yakın zamanda bildirilen letrozol kullanımına bağlı gelişen ekzematöz deri erüpsiyonu da bu ajana bağlı geliştiği bilinen yan etkilerden biridir. Bizim bilgimize göre letrozol ile indüklenen lineer ilaç erüpsiyonu daha önce literatürde bildirilmemiştir. 52 yaşında kadın hastada letrozol kullanımı sonrası gelişen, sol uylukta Blaschko çizgilerini izleyen ünilateral kaşıntılı likenoid erüpsiyon olgusunu sunuyoruz. Aromataz inhibitörlerine bağlı gelişen kutanöz yan etkiler progresif kutanöz vaskülit gibi ciddi olabilirken bizim olgumuzda olduğu gibi hafif kutanöz yan etkiler şeklinde prezente olabilir. Klinisyenlerin bu benign yan etkiden haberdar olmaları önemlidir. İlacın kesilme kararı aromataz inhibitörlerinin yan etkilerinin şiddetinin bilinmesine bağlıdır.

Anahtar Kelimeler: Letrozol; likenoid erüpsiyonlar; aromataz inhibitörleri

Türkiye Klinikleri J Dermatol 2016;26(2):114-6

Linear eruptions of lichen planus can occur in association with drug usage.¹⁻⁵ We describe a case of lichenoid eruption with linear configuration induced by letrozole, third generation, aromatase inhibitor for oestrogen receptor-positive breast cancer, in a 52-year old woman who has been diagnosed breast cancer. Linear lichenoid drug eruptions following Blaschko lines are rare subtype of lichenoid drug eruptions and it is important to differentiate from zosteriform lichen planus lesions that occur due to Koebner phenomenon.

Before deciding to discontinue of medication, physicians should be aware of this type benign side effect. Awareness of letrozole induced cutaneous adverse reactions may lead to prevent treatment interruption. We report 52-year-old woman who had unilateral pruritic lichenoid eruption over left thigh following Blaschko lines after usage letrozole.

CASE REPORT

A 52-year-old woman with a two years history of breast cancer presented with an itchy eruption on her left thigh. She had been taking letrozole (2.5 mg/day, orally) for one month and she indicated that this eruption has begun at the third week of letrozole usage. She had not taken any other drugs. Her medical history was unremarkable other than letrozole. There was no family history of eczema or drug induced skin reaction. She had no known drug reaction, history of rash caused by drugs, history of atopy or eczema. There were slightly erythematous and violaceous lichenoid papules and plaques with fine scale in a linear distribution following Blaschko lines on dermatologic examination (Figure 1). Oral mucosa, genital mucosa and nails were not involved. Haematological and biochemical parameters were within normal limits. Serologies for hepatitis B and C viruses were negative.

Patient consent form for skin biopsy and for case report has been taken. Histopathologic examination of skin biopsy revealed hyperkeratosis, hypergranulosis, irregular acanthosis, eosinophil rich lichenoid infiltration of superficial dermis and colloid bodies in the dermoepidermal junction (Figure 2).

With these findings we concordant with lichenoid drug eruption. The patient has been diagnosed as letrozole induced linear lichenoid drug eruption. She was prescribed betametasone dipropionate (0,025%) ointment until she could return for follow-up. After one month after initial presentation, on follow-up examination, lesions have not resolved but pruritus has improved significantly. Topical treatment was changed with super-potent corticosteroid ointment and she was asked

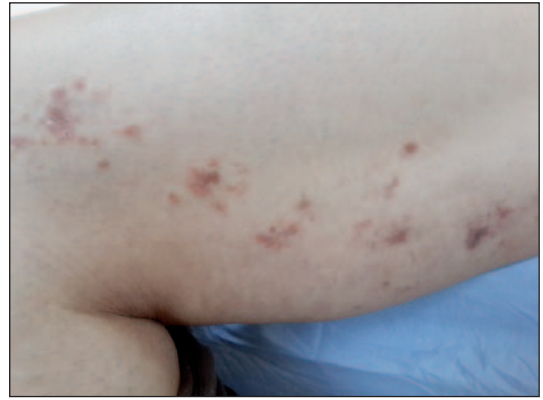

FIGURE 1: Erythematous and violaceous lichenoid papules and plaques in a linear distribution on the thigh.

(See color figure at <http://www.turkiyeklinikleri.com/journal/dermatoloji-dergisi/1300-0330/>)

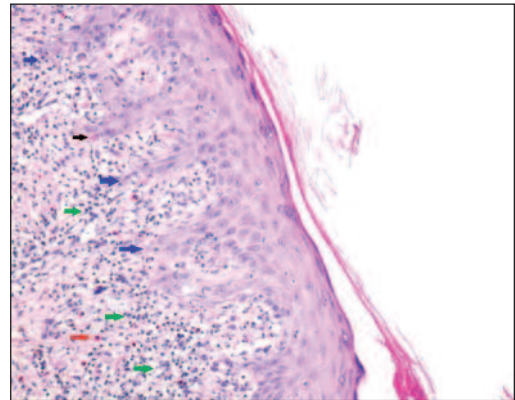


FIGURE 2: Red arrow: Eosinophil leukocytes; Green arrow: Band like mononuclear cell infiltration; Blue arrow: Saw-tooth acanthosis.

(See color figure at <http://www.turkiyeklinikleri.com/journal/dermatoloji-dergisi/1300-0330/>)

for control appointment a month later. She is still under follow-up.

DISCUSSION

Drug eruptions occur very frequently and show the relationship between the environmental factors and genetic predisposition.⁶ In most cases discontinuation of medication is required. Although laboratory examinations are helpful, anamnesis of drug usage with dermatological examination is essential for diagnosis.

Lichenoid drug eruption (LDE) refers a cutaneous adverse reaction induced by several drugs which shows lichenoid interface dermatitis on histological examination. Time interval between ini-

tiation of the drug intake and cutaneous eruption varies from months to year.⁷ Clinical presentation is similar to idiopathic lichen planus (LP) which is characterized with inflammatory, pruritic, violaceous colored, polygonal, papular lesions. Histopathological findings except eosinophil infiltration are also similar to idiopathic LP. Linear/segmental (mosaic) lichenoid drug eruption with blaschkoid pattern is a quite rare variant of this group disorders and is different from zosteriform LP which is related with Koebner phenomenon.^{8,9} Linear lichen planus following Blaschko lines that is associated with drug usage has been reported first time by Muñoz et al. and in literature there are case reports induced by bismuth, valsartan, ibuprofen, salazopyrine and nicergoline.¹⁻⁵ Acquired dermatoses following Blaschko lines are termed as blaschkitis and this pattern has been explained by cellular mosaicism that is result to clone of cells

with different histocompatibility antigen in a particular area of the skin.³

Our case is also an example of linear lichenoid drug eruption that is occurred due to letrozole. Letrozole, a third generation, nonsteroidal aromatase inhibitor, is approved for first- and second-line treatment of advanced breast cancer in postmenopausal women. Cutaneous adverse effects including vasculitis and erythema nodosum of letrozole have been rarely described in literature.¹⁰ Recently reported eczematous skin eruption due to letrozole is one of the side effects that known to be developed by this drug.¹¹ Cutaneous side-effects secondary to use of aromatase inhibitors, including letrozole, in breast cancer patients may cause potentially pitfalls in the management of patients. Awareness of letrozole induced cutaneous adverse reactions may lead to prevent patient inadherence and treatment interruption.

REFERENCES

1. Shaffer L. A case for diagnosis. *Arch Dermatol Syph* 1939;40:305.
2. Stransky L. Unilateral multiplex naevoid zosteriform Lichen ruber planus following oral administration of salazopyrine. *Derm Beruf Umwelt* 1991;39(2):54-5.
3. Muñoz MA, Pérez-Bernal AM, Camacho FM. Lichenoid drug eruption following the Blaschko lines. *Dermatology* 1996;193(1):66-7.
4. Krasowska D, Schwartz RA, Lecewicz-Torun B. Generalized lichenoid drug eruption following Blaschko lines. *Int J Dermatol* 2001; 40(12):774-6.
5. Gencoglan G, Ceylan C, Kazandi AC. Linear lichenoid drug eruption induced by valsartan. *Clin Exp Dermatol* 2009;34(7):e334-5.
6. Akpınar F, Dervis E. Drug eruptions: an 8-year study including 106 inpatients at a dermatology clinic in Turkey. *Indian J Dermatol* 2012;57(3):194-8.
7. Brauer J, Votava HJ, Meehan S, Soter NA. Lichenoid drug eruption. *Dermatol Online J* 2009;15(8):13.
8. Arfan-ul-Bari, Rahman SB. Zosteriform lichen planus. *J Coll Phys Surg Pak* 2003;13(2):104-5.
9. Grosshans E, Marot L. [Blaschkitis in adults]. *Ann Dermatol Venereol* 1990;117(1): 9-15.
10. Santoro S, Santini M, Pepe C, Tognetti E, Cortelazzi C, Ficarelli E, et al. Aromatase inhibitor-induced skin adverse reactions: exemestane-related cutaneous vasculitis. *J Eur Acad Dermatol Venereol* 2011;25(5): 596-8.
11. Tripathy A, Kumari KM, Babu AVM, Pai SB, Kumar DM. Anything rare is possible: letrozole induced eczematous skin eruption. *J Clin Diagn Res* 2014;8(6):YD03-4.