

Evaluation of the Effect of Fixed Prosthesis on Trabecular Structure of Condyle: Radiographic Texture Analysis

Sabit Protezin Kondilin Trabeküler Yapısına Etkisinin Değerlendirilmesi: Radyografik Doku Analizi

İ Gülđane MAGAT,^a
 İ Begüm BÜYÜKERKMEŖ,^b
 İ Sevgi ÖZCAN ŞENER^a

Departments of
^aOral and Maxillofacial Radiology,
^bProsthodontics,
 Konya Necmettin Erbakan University
 Faculty of Dentistry,
 Konya

Received: 26.02.2018
 Received in revised form: 09.04.2018
 Accepted: 30.04.2018
 Available online: 06.07.2018

Correspondence:
 Gülđane MAGAT
 Konya Necmettin Erbakan University,
 Faculty of Dentistry,
 Department of Oral and
 Maxillofacial Radiology, Konya,
 TURKEY/TÜRKİYE
 gul_dent@hotmail.com

ABSTRACT Objective: The point of this research was to assess impact of the fixed prosthesis on the trabecular structure of condyle using fractal analysis (FA). **Material and Methods:** In this retrospective research, 100 dental panoramic radiographs of males and females taken for routine dental examination of patients between 30-44 years who are utilizing unilateral fixed prosthesis were chosen. Regions of interest (50×50 pixels) were selected within the cortical boundary of the mandibular condyle, and the fractal dimension (FD) was calculated using the box-counting method with ImageJ version 1.48. **Results:** The mean age was 37.78±0.44 years. The mean FD was 1.26±0.12. There was no statistically significant difference between the right and left condyles on both genders for FD values (p>0.05). It was found that a significant difference in FD values between males and females (p<0.01). Males had greater FD values than females. Whereas the mean FD value was 1.21±0.19 in females, the mean FD value of males was 1.32±0.08. A positive significant correlation was found between age and FD values for both condyles (p<0.05). **Conclusion:** The findings of this study showed that the use of fixed prosthesis had no effect on the trabecular structure of the condyle. The FD value decreased with age, especially in females. Radiographic findings should be supported electromyographic results to clarify the relationship between masticatory activity and mandibular remodeling in this region.

Keywords: Fractal; fixed prosthesis; condyle; mandible

ÖZET Amaç: Bu araştırmanın amacı sabit protezin kondilin trabeküler yapısına olan etkisini fraktal analiz (FA) kullanarak değerlendirmektir. **Gereç ve Yöntemler:** Bu retrospektif araştırmada, rutin diş muayenesi için alınmış dental panoramik radyografisi olan hastalar arasından 30-44 yaş arasında olan ve tek taraflı sabit protez kullanan 50 kadın ve 50 erkek birey, toplam 100 kişi seçildi. İlgilenilen bölgeler (50 x 50 piksel), mandibular kondilin kortikal sınırları içinde seçilmiştir ve fraktal boyut (FB), ImageJ versiyon 1.48 olan kutu sayma yöntemi kullanılarak hesaplanmıştır. **Bulgular:** Yaş ortalaması 37,78±0,44 yıl idi. Ortalama FB değeri 1,26±0,12 idi. FB değerleri için her iki cinsiyette sağ ve sol kondiller arasında istatistiksel olarak anlamlı bir farklılık yoktu (p>0,05). Erkekler ve kadınların FB değerleri arasında anlamlı bir farklılık olduğu tespit edildi (p<0,01). Erkeklerin FB değerleri kadınlara göre daha fazlaydı. Kadınlarda ortalama FB değeri 1,21±0,19 iken erkeklerin ortalama FB değeri 1,32±0,08 idi. Her iki kondil için de yaş ve FD değerleri arasında pozitif yönde anlamlı bir ilişki bulundu (p<0,05). **Sonuç:** Bu çalışmanın bulguları sabit protez kullanımının kondilin trabeküler yapısına bir etkisi olmadığını göstermiştir. Özellikle kadınlarda FD değeri yaşla birlikte azalmaktadır. Bu bölgedeki çiğneme aktivitesi ile mandibular remodeling arasındaki ilişkiyi netleştirmek için radyografik bulgular, elektromiyografik sonuçlarla desteklenmelidir.

Anahtar Kelimeler: Fraktal; sabit protez; kondil, mandibula

The fractal analysis describes very complex images such as the trabecular bone microarchitecture using statistical texture analysis. It express a numerical value named as the fractal dimension (FD).¹ It is

noninvasive technique and measures changes in alveolar bone.¹ Moreover, this strategy is likewise answered to stay unaffected by varieties in exposure, arrangement, and decision of region of interest (ROI).²

In medical radiology, the FD count is utilized to improve the finding of osteoporosis or breast cancer.^{3,4} In dental area, FD is usually utilized as a part of non-standardized radiographs, to assess and evaluate a cancellous bone structure for the determination of bone changes, apical healing, periapical bone, and systemic situations such as osteoporosis.⁵⁻⁹

In the stomatognathic system, the mandible hosts the teeth and supports attachment of the masticatory muscles. Mechanical stimulation is imperative for bone improvement, maintaining, modeling, and remodeling.¹⁰⁻¹² Likewise, mandibular morphology and structure are affected by the proper bite and muscle force. A lessening in physical movement may prompt to an increase in loss of bone and in the prevalence of osteoporotic fracture.¹³⁻¹⁵ In this way, occlusal hypofunction may influence jawbone structures. As the jaws get physical incitement from mastication and biting, it is essential to research the relations amongst function and jawbone structure.^{16,17} On the other hand, little information has been obtained about the bone mineral density (BMD) of the jawbone after healing of functional occlusion.

In any case, most researches have focused on the impact of occlusal stimulus on alveolar bone in the molar region.^{18,19} The mandible comprises of the mandibular body and mandibular ramus physiologically. The changes in the alveolar bone do not reflect the reaction of the whole mandible to occlusal hypofunction. Besides, it is unknown whether the recurrence of occlusal stimuli positively affects mandibular remodeling. These subjects should be pointed out in detail.²⁰

The utilization of FD of condyle on panoramic radiographs has not been investigated. Accordingly, the point of this research was to assess the impact of fixed prosthesis on the trabecular structure of condyle using FD.

MATERIAL AND METHODS

In this retrospective research, 100 dental panoramic radiographs taken for routine dental examination of subjects (50 males and 50 females) beyond 18 years old years between 30-44 years who are utilizing unilateral fixed prosthesis in the posterior region were chosen. The patients had fixed prosthesis (at least three and at most five crowns) on maxilla or mandibula at the least one year. The fixed prosthesis had implant-supported. None of the subjects had systemic disease or conditions affecting bone metabolism, and none were using medications that would interfere with bone turnover. The patients with error and elevations in fixed prosthesis and bruxism findings, inadequate radiographic materials, presence of condensing osteitis, osteosclerosis, images with local destructive lesions of the jaws, and radiographs with undesirable anatomical structures or superimpositions of ghost images of anatomical structures were also excluded. The research was affirmed by action of our Local Research Ethics Committee (decision no: 2016.005), and conformed to the guidelines laid out in the Declaration of Helsinki.

The chosen dental panoramic radiographs were obtained with the same panoramic machine (Eastman Kodak® 8000; Rochester, NY) by the same person. Patients were situated in the machine in a manner that the vertical line delivered by the machine was adjusted to the patient's sagittal plane and the horizontal line parallel to the floor.

The methods for FD calculation were performed utilizing Image J 1.49s programme (United States National Institutes of Health, <http://rsb.info.nih.gov/nih-image>). The measurements were made by one observer (G.M.) for two times. The observer had professional experience of 7 years in the oral radiology department and repeated the measurements at an interval of 1 month. The FD values were measured for both condyles of each individual. Condyle on the side without prosthesis was evaluated as control group.

ROIs were chosen inside every image by utilizing Photoshop CS4 program (Adobe Inc. San

Jose, CA). ROIs were chosen as 50×50 pixel-sized squares that located condyle and were delineated physically in every radiograph (Figure 1). The ROIs were chosen as centeredly as possible in order to keep the superimposition of other structure (e.g articular eminence) inside the condyle bone on the FD measurements. The ROIs saved as TIFF. file and were submitted to Image J 1.49s software. The cropped ROI was duplicated and a Gaussian filter (sigma=3) was used to remove brightness variations. The resulting image was then subtracted from the first image and then the resultant image was converted to binary by threshold at the gray value of 128. Through this procedure, the regions that represent trabecular bone were set to black and marrow spaces were set to white. The erosion and the outlines of the structures were emphasized using dilation. Finally, the image was skeletonized and was used for fractal analysis (Figure 2).²¹

The FD of the skeletonized image was determined with Image J 1.49s utilizing the box-counting function from 'analyze' menu. The widths of the square boxes were stated as 2-64 pixels. The subsequent number of the computed tiles was plotted as a detriment to the total number of the tiles in twofold logarithmic scale and FD was computed from the slope of the line fitted on the data points.

Statistical evaluation of the data was generated utilizing the product bundles SPSS® 21.0 (IBM Corp., Armonk, NY; earlier SPSS Inc., Chicago, IL).

The intraclass correlation coefficient was calculated for measurements. Descriptive statistics for every variable were calculated. The Kolmogorov–Smirnov test was utilized to detect the distribution homogeneity. In this way, the correlations between the study groups were evaluated with non-parametric tests. The Wilcoxon test was utilized to decide the distinctions of the mean values between the right and left FD. The Mann-Whitney U test was utilized in order to test the differences between the genders in terms of measurements. Significance level was determined as 5%.

RESULTS

Intra-class correlation coefficient values were 0.887 and 0.854 (almost excellent) for right and left FD measurements, respectively. Table 1 demonstrates the descriptive statistics of the measurements.

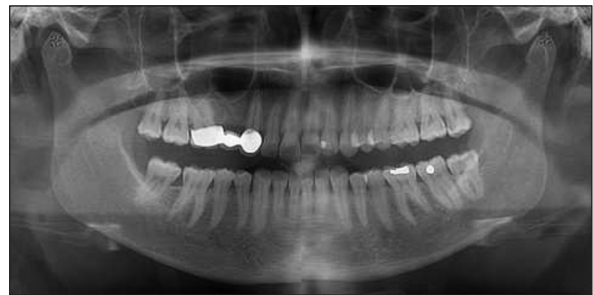

FIGURE 1: ROIs were selected within each image to provide the maximum available area for measurement. Lamina dura, periodontal ligament and related regions, and root apices were not included within the ROI.




FIGURE 2: a) The cropped region of interest (ROIs), b) The duplicated ROI c) Gaussian filtered image, d) Subtracted from the original image, e) Added 128 image, f) Binary image, g) Eroded image, h) Dilated image, i) The skeletonized image.

TABLE 1: Descriptive statistics of variables.

	N	Minimum	Maximum	Mean	Total SE
Female	50				
Age (year)		30	43	36.78	0.65
FD with fixed prosthesis		.96	1.50	1.21	0.02
FD with non-fixed prosthesis		.80	1.45	1.19	0.02
Male	50				
Age (year)		30	44	38.78	0.55
FD with fixed prosthesis		1.19	1.44	1.33	0.01
FD with non-fixed prosthesis		1.14	1.45	1.33	0.01
Total	100				
Age (year)		30	44	37.78	0.44
FD with fixed prosthesis		0.96	1.50	1.27	0.01
FD with non-fixed prosthesis		0.80	1.45	1.26	0.01

N: Total number of individuals; SE: Standard error of means; FD: Fractal dimension.

While the mean age of females was 36.78 ± 0.65 years, it was 38.78 ± 0.55 in males. There was no significant difference between female and males in terms of age ($p > 0.05$). The mean FD was 1.26 ± 0.12 for both condyles. The data of FD was demonstrating no uniform distribution ($p < 0.05$); and it was non-homogeneous ($p < 0.05$). There were no significant differences between the condyles on both gender for FD values ($p > 0.05$). As stated by Mann-Whitney U test, it was found that a significant difference in FD values amongst males and females ($p < 0.01$). Males had greater FD values than females. In females, the mean FD value was 1.21 ± 0.19 . In males, the mean FD value was 1.32 ± 0.08 (Figures 3 and 4). The Spearman's correlation test revealed that there was a positive correlation between age and FD values for both condyles ($p < 0.01$).

DISCUSSION

All of the measurements were evaluated on panoramic radiographs taken for routine dental examination of patients. To ensure reliability and consistency, one dentomaxillofacial radiologist assessed every image to choose just those radiographs of the most elevated quality. The intraclass correlation coefficient was great. This shows the strategy for indice for appraisal is extremely dependable.

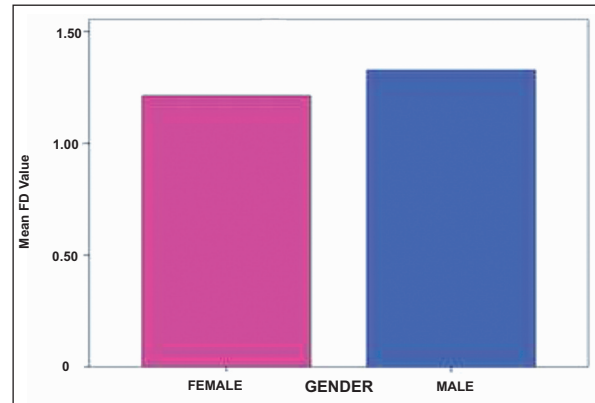


FIGURE 3: The mean FD values of the condyle on the side with the unilateral fixed prosthesis. FD: Fractal dimension.

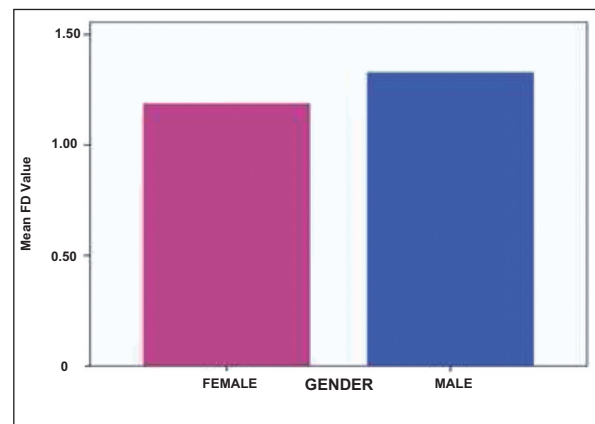


FIGURE 4: The mean FD values of the condyle on the contralateral side without the unilateral fixed prosthesis. FD: Fractal dimension.

Evaluation of the pattern of trabecular bone is a fundamental factor for analyzing quality of mandibular bone during surgical arrangement, placement of the implant, orthodontic movements, and prosthetic support. The mandible is a single bone, and it has a place in the axial skeleton. The impact of masticatory forces on mandibular trabeculae is still conflicting.⁸ Panoramic radiography has been generally utilized as a part of screening and epidemiological reviews because of the convenience of their utilization. Also, this technique can offer a dosage advantage over substantial quantities of intraoral radiographs.²²

FD is a kind of mathematical method which can help for the measures of complex structures. Generally, the shapes with more complexity have FD with higher degree. This system has been accounted for to be utilized with varying degrees of accomplishment in several imaging modalities, for example, plain film radiography, mammography, computed tomography (CT), and magnetic resonance imaging (MRI).⁹ Different researchers assessed the structure of the trabecular bone on dental radiographs by utilizing different FD methods with the purpose of separating person with osteoporosis from the ones who do not have.²³ FD measurements have additionally been utilized as a part of separating periodontitis and sickle cell anemia patients from healthy individuals.²⁴⁻²⁶ In this research, FD analysis was implemented to panoramic radiographs of patients with unilateral fixed prosthesis so as set up a noninvasive assessment of their bone structures to compare differences FD values between the left and right sides.

In fractal investigation, a box-counting algorithm is for the most part utilized to evaluate the trabecular structure by numbering the trabecular bone and bone marrow interface, and it measures the boundary of trabecular bone and marrow.²⁷ In this technique, a grid of squares is placed over the object, and the quantity of squares which any part of the object goes through is measured. This technique is rehashed with different grids with various sizes. A chart on log-log scale is plotted with the amount of squares put over the object and side length of the square. A regression line is obtained from the plots,

and incline of this line gives the measurement. This procedure can give the evaluation of the level of uneven intricacy of a point of confinement or a coast.²⁸ In this research, we utilized a basic approach to decide the FD called box counting, as well.

A few researchers have revealed that structures with high FD have more structural complexity. Lower FD qualities are demonstrative of more straightforward structures.²⁹ It is known that the mechanical properties and architecture of the trabecular bone, depending on the physiological function and the mechanical loading on the skeleton, show the directional anisotropy of the architecture.³⁰ FD measurements belonging to healthy bone vary from 1.20 to 2.68.^{2,31-33} These varieties were principally brought about by the issues of the fractal examination itself as opposed to by various materials utilized as a part of every study. In the present research, the mean FD value was 1.21 ± 0.19 for female and the mean FD value was 1.32 ± 0.08 for male, separately. These results were consistent with the study conducted by Sindaux et al.³⁴ Kavitha et al.³⁵ stated that FD values of males was higher than females at every age and FD decreased with age in both genders. Watanabe et al.³⁶ reported that the FD of male group showed a higher degree of trabecular bone architecture and indicated that the structure of their bone is less prone to osteoporotic fractures. In the literature, there was only one study³⁷ evaluated of FD values of the condyle. They found that the FDs of the condylar heads in TMJs with disc displacement without reduction were higher than the FDs of those with disc displacement and reduction. It should be noted that the methodology of their study is different, while the mean FD values obtained are compatible with their FD values.

The reliability of FD calculations from radiographs has been evaluated in a few studies, which revealed that they have not sensitivity for little alignment variations, over- or sub-exposure.^{21,31} Moreover, ROI position was resolved to be more basic contrasted with ROI estimate.⁷ Standardized panoramic radiographs were used in our study and ROIs were heedfully placed in order to reduce potential unknown impacts of these components to minimum.

In our study, the ROIs of the trabecular bone were 2.11 mm (50×50 pixels). We have selected this ROI size based on a study that stated that the lower and upper limits within which trabecular bone is effectively fractal are 0.025 mm and 4.25 mm respectively.³⁸ Our study had also used digitized panoramic images similarly to Yasar et al. and box counting method for FD calculation.³⁹ This method of FD calculation was the most used in the previous clinical studies, probably due to its simplicity and availability.^{8,9,39}

Extraction of permanent first molars could adversely influence the adjust of all occlusion.⁴⁰ The asymmetrical function and imbalanced occlusion may change trabecular bone structure of the right and left sides of the mandible, which may bring about remodeling of the condyle.⁴¹ In our research, the patients were utilizing settled prosthesis no less than one year. Therefore, we did not observe any differences between the left and right FD values.

CONCLUSION

According to the results, there was no effect of fixed prosthesis on the trabecular structure of condyle. Future studies which were evaluated different clinical parameters such as the duration of use and type of prosthesis, occlusion type, and habit of chewing, bruxism may give obvious information

about the changes of condyle FD values. Radiographic findings should be supported electromyographic results by future studies to clarify the relationship between masticatory activity and mandibular remodeling in this region.

Source of Finance

During this study, no financial or spiritual support was received neither from any pharmaceutical company that has a direct connection with the research subject, nor from a company that provides or produces medical instruments and materials which may negatively affect the evaluation process of this study.

Conflict of Interest

No conflicts of interest between the authors and / or family members of the scientific and medical committee members or members of the potential conflicts of interest, counseling, expertise, working conditions, share holding and similar situations in any firm.

Authorship Contributions

Idea/Concept: Güldane Magat, Begüm Büyükerkmen, Sevgi Özcan Şener; **Design:** Güldane Magat, Begüm Büyükerkmen; **Supervision/Consultancy:** Güldane Magat, Begüm Büyükerkmen; **Data Collection/or Processing:** Begüm Büyükerkmen; **Analysis and / or Interpretation:** Güldane Magat, Sevgi Özcan Şener; **Source Browsing:** Güldane Magat; **Writing the Makalen:** Güldane Magat; **Critical Review:** Güldane Magat, Sevgi Özcan Şener; **Resources and Funding:** Güldane Magat; **Materials:** Güldane Magat, Begüm Büyükerkmen, Sevgi Özcan Şener.

REFERENCES

- Huh KH, Baik JS, Yi WJ, Heo MS, Lee SS, Choi SC, et al. Fractal analysis of mandibular trabecular bone: optimal tile sizes for the tile counting method. *Imaging Sci Dent* 2011;41(2):71-8.
- Bianchi AE, Dolci Jr G, Sberna MT, Sanfilippo S. Factors affecting bone response around loaded titanium dental implants: a literature review. *J Appl Biomater Biomech* 2004;3:135-40.
- Yi WJ, Heo MS, Lee SS, Choi SC, Huh KH. Comparison of trabecular bone anisotropies based on fractal dimensions and mean intercept length determined by principal axes of inertia. *Med Biol Eng Comput* 2007;45(4):357-64.
- Huh KH, Yi WJ, Jeon IS, Heo MS, Lee SS, Choi SC, et al. Relationship between two-dimensional and three-dimensional bone architecture in predicting the mechanical strength of the pig mandible. *Oral Surg Oral Med Oral Pathol Oral Radiol Endod* 2006;101(3):363-73.
- Baksi BG, Fidler A. Fractal analysis of periapical bone from lossy compressed radiographs: a comparison of two lossy compression methods. *J Digit Imaging* 2011;24(6):993-8.
- Huang CC, Chen JC, Chang YC, Jeng JH, Chen CM. A fractal dimensional approach to successful evaluation of apical healing. *Int Endod J* 2013;46(6):523-9.
- Yi WJ, Heo MS, Lee SS, Choi SC, Huh KH, Lee SP. Direct measurement of trabecular bone anisotropy using directional fractal dimension and principal axes of inertia. *Oral Surg Oral Med Oral Pathol Oral Radiol Endod* 2007;104(1):110-6.
- González-Martín O, Lee EA, Veltri M. CBCT fractal dimension changes at the apex of immediate implants placed using undersized drilling. *Clin Oral Implants Res* 2012;23(8):954-7.

9. Jolley L, Majumdar S, Kapila S. Technical factors in fractal analysis of periapical radiographs. *Dentomaxillofac Radiol* 2006;35(6):393-7.
10. Rot I, Mardesic-Brakus S, Costain WJ, Saraga-Babic M, Kablar B. Role of skeletal muscle in mandible development. *Histol Histopathol* 2014;29(11):1377-94.
11. Rubin CT, Lanyon LE. Kappa Delta Award paper. Osteoregulatory nature of mechanical stimuli: function as a determinant for adaptive remodeling in bone. *J Orthop Res* 1987;5(2):300-10.
12. Kunii R, Yamaguchi M, Aoki Y, Watanabe A, Kasai K. Effects of experimental occlusal hypofunction, and its recovery, on mandibular bone mineral density in rats. *Eur J Orthod* 2008;30(1):52-6.
13. Chilibeck PD, Sale DG, Webber CE. Exercise and bone mineral density. *Sports Med* 1995;19(2):103-22.
14. von Wowern N, Hjørtting-Hansen E, Stoltze K. Changes in bone mass in rat mandibles after tooth extraction. *Int J Oral Surg* 1979;8(3):229-33.
15. Sato H, Kawamura A, Yamaguchi M, Kasai K. Relationship between masticatory function and internal structure of the mandible based on computed tomography findings. *Am J Orthod Dentofacial Orthop* 2005;128(6):766-73.
16. Maeda H, Suzuki H. [An experimental study of the orthodontic force effect on internal remodeling of mandibular bone]. *Nihon Kyosei Shika Gakkai Zasshi* 1990;49(2):100-17.
17. Steigman S, Michaeli Y, Yitzhaki M, Weinreb M. A three-dimensional evaluation of the effects of functional occlusal forces on the morphology of dental and periodontal tissues of the rat incisor. *J Dent Res* 1989;68(8):1269-74.
18. Shimomoto Y, Chung CJ, Iwasaki-Hayashi Y, Muramoto T, Soma K. Effects of occlusal stimuli on alveolar/jaw bone formation. *J Dent Res* 2007;86(1):47-51.
19. Termsuknirandom S, Hosomichi J, Soma K. Occlusal stimuli influence on the expression of IGF-1 and the IGF-1 receptor in the rat periodontal ligament. *Angle Orthod* 2008;78(4):610-6.
20. Liu J, Liu SY, Zhao YJ, Gu X, Li Q, Jin ZL, et al. Effects of occlusion on mandibular morphology and architecture in rats. *J Surg Res* 2016;200(2):533-43.
21. Lee DH, Ku Y, Rhyu IC, Hong JU, Lee CW, Heo MS, et al. A clinical study of alveolar bone quality using the fractal dimension and the implant stability quotient. *J Periodontal Implant Sci* 2010;40(1):19-24.
22. Ludlow JB, Davies-Ludlow LE, White SC. Patient risk related to common dental radiographic examinations: the impact of 2007 International Commission on Radiological Protection recommendations regarding dose calculation. *J Am Dent Assoc* 2008;139(9):1237-43.
23. Law AN, Bollen AM, Chen SK. Detecting osteoporosis using dental radiographs: a comparison of four methods. *J Am Dent Assoc* 1996;127(12):1734-42.
24. Melsen B, Lang NP. Biological reactions of alveolar bone to orthodontic loading of oral implants. *Clin Oral Implants Res* 2001;12(2):144-52.
25. Yasar F, Akgünlü F. Fractal dimension and lacunarity analysis of dental radiographs. *Dentomaxillofac Radiol* 2005;34(5):261-7.
26. White SC, Cohen JM, Mourshed FA. Digital analysis of trabecular pattern in jaws of patients with sickle cell anemia. *Dentomaxillofac Radiol* 2000;29(2):119-24.
27. Uchiyama T, Tanizawa T, Muramatsu H, Endo N, Takahashi HE, Hara T. Three-dimensional microstructural analysis of human trabecular bone in relation to its mechanical properties. *Bone* 1999;25(4):487-91.
28. Umemori S, Tonami K, Nitta H, Mataka S, Araki K. The possibility of digital imaging in the diagnosis of occlusal caries. *Int J Dent* 2010;2010:860515.
29. Sánchez I, Uzcátegui G. Fractals in dentistry. *J Dent* 2011;39(4):273-92.
30. Alman AC, Johnson LR, Calverley DC, Grunwald GK, Lezotte DC, Hokanson JE. Diagnostic capabilities of fractal dimension and mandibular cortical width to identify men and women with decreased bone mineral density. *Osteoporos Int* 2012;23(5):1631-6.
31. Southard TE, Southard KA, Jakobsen JR, Hillis SL, Najim CA. Fractal dimension in radiographic analysis of alveolar process bone. *Oral Surg Oral Med Oral Pathol Oral Radiol Endod* 1996;82(5):569-76.
32. Wilding RJ, Slabbert JC, Kathree H, Owen CP, Crombie K, Delpont P. The use of fractal analysis to reveal remodelling in human alveolar bone following the placement of dental implants. *Arch Oral Biol* 1995;40(1):61-72.
33. Geraets WG, van der Stelt PF. Fractal properties of bone. *Dentomaxillofac Radiol* 2000;29(3):144-53.
34. Sindeaux R, Figueiredo PT, de Melo NS, Guimarães AT, Lazarte L, Pereira FB, et al. Fractal dimension and mandibular cortical width in normal and osteoporotic men and women. *Maturitas* 2014;77(2):142-8.
35. Kavitha MS, Park SY, Heo MS, Chien SI. Distributional variations in the quantitative cortical and trabecular bone radiographic measurements of mandible, between Male and female populations of Korea, and its utilization. *PLoS One* 2016;11(12):e0167992.
36. Aranha Watanabe PC, Moreira Lopes De Faria L, Mardegan Issa JP, Caldeira Monteiro SA, Tioffi R. Morphodigital evaluation of the trabecular bone pattern in the mandible using digitized panoramic and periapical radiographs. *Minerva Stomatol* 2009;58(3):73-80.
37. Arsan B, Köse TE, Çene E, Özcan İ. Assessment of the trabecular structure of mandibular condyles in patients with temporomandibular disorders using fractal analysis. *Oral Surg Oral Med Oral Pathol Oral Radiol* 2017;123(3):382-91.
38. Parkinson IH, Fazzalari NL. Methodological principles for fractal analysis of trabecular bone. *J Microsc* 2000;198(Pt 2):134-42.
39. Yasar F, Akgunlu F. Evaluating mandibular cortical index quantitatively. *Eur J Dent* 2008;2(4):283-90.
40. Lin YT, Lin WH, Lin YT. Immediate and six-month space changes after premature loss of a primary maxillary first molar. *J Am Dent Assoc* 2007;138(3):362-8.
41. Pirttiniemi P, Kantomaa T. Relation of glenoid fossa morphology to mandibulofacial asymmetry, studied in dry human Lapp skulls. *Acta Odontol Scand* 1992;50(4):235-43.