

Anatomical Features of the Extensors to the Index Finger

El İşaret Parmağının Ekstensörlerinin Anatomik Özellikleri

Okan BİLGE, MD,^a
Figen GÖVSA, MD,^a
Yelda PINAR, MD,^a
Servet ÇELİK, MD^a

^aDepartment of Anatomy,
Ege University Faculty of Medicine,
İzmir

Geliş Tarihi/Received: 30.04.2009
Kabul Tarihi/Accepted: 27.04.2010

*This study was presented as
a poster presentation i
n XIX. International Symposium of
Morphological Sciences, Budapest 2007,
August 19-24, Hungary.*

Yazışma Adresi/Correspondence:
Figen GÖVSA, MD
Ege University Faculty of Medicine,
Department of Anatomy,
İzmir,
TÜRKİYE/TURKEY
figen.govsa@ege.edu.tr

ABSTRACT Objective: Extensor indicis proprius (EIP), the extensor medii proprius (EMP) and the extensor indicis medii proprius (EIMP) are important tendons in the surgery of hand as a graft, apart from performing the function of extension. In cases which require surgical treatment of the hand like trauma, rheumatoid arthritis, ulnar nerve palsy, and hypoplasia of the thenar muscle, the EIP, the EMP and the EIMP are suitable muscles for tendon transfer operations. **Material and Methods:** The variations of the extensor tendons to the index finger were examined in fifty-four dissected hands. **Results:** The most common pattern of the tendons was a single extensor digitorum indicis (ED-indicis) and a single EIP. The EIP was observed as a single tendon in 87.03% of the specimens, and as a double tendon in 12.96% of them. The EMP was seen in 24.07% of the specimens. In one hand, the muscle had a shared belly with the EMP and the EIMP. **Conclusion:** The existence of the supernumerary tendons was more frequently encountered at the ulnar side of the ED-indicis than at the radial side. These extra tendons may be of great value in cases of traumatized hands which require tendinoplasty.

Key Words: Anatomy; hand; hand deformities; trigger finger disorder

ÖZET Amaç: Ekstensor indicis proprius (EIP), ekstensor medii proprius (EMP) ve ekstensor indicis medii proprius (EIMP) sadece ekstensiyon fonksiyonu olmanın yanı sıra el cerrahisinde greft olarak da önemli kaslardır. Travma, romatoid artrit, ulnar sinir felci ve elin tenar kaslarının atrofisi gibi elin cerrahi yöntemle tedavisi gerektiren durumlarda EIP, EMP ve EIMP kasları, tendon transferi açısından uygun kaslardır. **Gereç ve Yöntemler:** Elli dört elde işaret parmağın ekstensör kaslarının varyasyonları incelendi. **Bulgular:** En sık rastlanılan tendon örneği tek ekstensor digitorum indicis (ED-indicis) ve tek EIP'di. EIP olguların %87.03'ünde tek ve %12.96'sında çift tendon olarak bulundu. EMP'ye ise %24.07 sıklıkla rastlanıldı. Bir elde EMP ve EIMP kasları ortak karınlı olarak görüldü. **Sonuç:** İşaret parmağın tendon sayı fazlalığına ED-indicis'in radial tarafından daha çok, ulnar tarafında rastlanıldı. Bu tendonların, tendon tamiri gerektiren hasarlı ellerde bir değeri olacağı inancındayız.

Anahtar Kelimeler: Anatomi; el; el deformiteleri; tetik parmak bozukluğu

Turkiye Klinikleri J Med Sci 2010;30(6):1779-86

Both the extensor digitorum indicis (ED-indicis) and the extensor indicis proprius (EIP) muscles, together or individually, produce the extension of the index finger joints.¹⁻⁴ The independent ability to extend the index finger is thought to be caused by the independent function of the EIP tendon and the lack of a juncturae tethering the ED-indicis to the extensor pollicis.^{5,6}

The aberrant extensor tendons to the index finger are the extensor medii proprius (EMP), the extensor indicis medii proprius (EIMP), the extensor digitorum brevis manus and the extensor indicis accessories.⁷⁻¹⁰ In various clinical and anatomical studies, anatomic variations, arrangement and prevalence of these tendons have been documented. In literature, the incidence of these muscles and the insertion points of their tendons have been controversial.^{2,5,12-14} These muscles were not described in anatomical studies because they are often small in width and are almost covered by the ED tendons.

Since the ED-indicis tendon and the EIP to the index finger have independent functions, the EIP, EMP and EIMP tendons have been transferred to restore mobility for a variety of hand movements in tendon transfer.^{2,7} Furthermore, the variation muscles can cause pain and disability at the wrist during finger flexion such as the extensor indicis proprius syndrome and they have often been misdiagnosed as a ganglion or a tumor.¹⁵⁻²¹

It is essential to have an awareness of the anatomy and variations of the extensor tendons of the index finger when assessing a traumatized or diseased hand and when considering tendons for transfer. Although many researchers have examined the number of tendons, there is still doubt concerning the exact definition of the ED because the criteria in their definitions were not expressed in detail. The aim of this study is to provide a better description of the variant muscles of the index finger.

MATERIAL AND METHODS

Selected fifty-four adult male hands, aged between 38 and 87, were preserved in 10% formalin and examined. The hands were dissected from the level of the distal third of the forearm to the middle phalanx of the index finger. After the removal of the skin and a careful dissection of the superficial fascia on the back of each hand, the extensor retinaculum was divided longitudinally to expose the tendons, and the juncturae tendinum (JT). Microdissection was performed under a loop at original magnification (4X to 6X). All the extensor tendons were inspected with a particular attention to the number of tendons originating at the level of the

musculotendinous junction and the number of tendons or slips inserting into the extensor hood of the index finger. If the tendon was originating from the extensor retinaculum as a single tendon and was covered with a single fascial sheath, it was called as a single tendon; if it originated as two separate tendons and was covered with separate fascial sheaths, it was defined as a double tendon.

STATISTICAL ANALYSIS

Measurements were made by means of a digital flexible calliper in millimetres. Student-t test was applied for statistical analysis. SPSS 15.0 (Statistical Packages of Social Science) was used. Measurements of width (ED-indicis and EIP) and thickness (ED-indicis and EIP) were studied on right and left were studied with Student-t test. Measurements of width and thickness of EIP-ulnar and EIP-radial were performed and right and left sides were compared using Mann-Whitney U test. $P < 0.05$ was considered to be significant.

The dissection was approved by the ethics committee of the institution in which the work was undertaken, and the study conforms to the Declaration of Helsinki.

RESULTS

The extension of the index finger metacarpophalangeal joints was provided by the EIP and the ED-indicis. The most common pattern of the extensor tendons of the index fingers was as follows: 1- a single ED-indicis; 2- a single EIP tendon which inserted ulnar to the ED-indicis. The ED-indicis tendon was observed as a single tendon in all specimens. The EIP tendon was most consistently observed as a single tendon in 47 specimens (87.03%); and as a double tendon, called EIP-ulnar and EIP-radial, in seven cases (12.96%) (Tables 1-3). The analysis in this study showed that no significant differences were observed between the parameters of the extensor tendons in right and left sides ($p > 0.05$) (Table 2). According to our measurements it can be stated that the measurements of EI-indicis and EIP were close to each other. It has also been observed that the EIP-ulnar had greater dimensions than EIP-radial (Table 2).

TABLE 1: The number of the extensor tendons to the index finger.

Tendons	Number of Tendon							
	Absent		Single		Double		Triple	
	Left	Right	Left	Right	Left	Right	Left	Right
ED-indicis	0	0	31 (57.4%)	23 (42.6%)	0	0	0	0
EIP	0	0	27 (50%)	20 (37%)	4 (7.4%)	3 (5.5%)	0	0
EMP	0	0	6 (11.1%)	5 (9.3%)	0	0	0	0
EMP + EIMP				1 1.8%				

For abbreviations, see Table 3.

TABLE 2: The results of measurement of the extensor tendons at the middle level of the metacarpus on the dorsum of the hand.

Tendons	Width (mean ± SD mm) [n]		Thickness (mean ± SD mm) [n]	
	Left	Right	Left	Right
ED-indicis*	3.4 ± 1.09 [31]	3.65 ± 0.86 [23]	1.5 ± 0.4 [31]	1.53 ± 0.38 [23]
p		0.310		0.520
EIP*	3.71 ± 0.54 [20]	3.66 ± 1.1 [27]	1.47 ± 0.38 [20]	1.56 ± 0.67 [27]
p		0.791		0.204
EIP-radial	1.74 ± 0.13 [4]	1.69 ± 0.09 [3]	1.2 ± 0.08 [4]	1.19 ± 0.09 [3]
p		0.167		0.119
EIP-ulnar	2.11 ± 0.16 [4]	2.31 ± 0.16 [3]	1.34 ± 0.05 [4]	1.27 ± 0.04 [3]
p		0.999		0.683
EMP	1.46 ± 0.79	1.74 ± 1.13	1.22 ± 0.81	0.84 ± 0.61

Mann-Whitney U and Student-t test*.

For abbreviations, see Table 3.

TABLE 3: Features of the insertio of the EMP and the EIMP.

Sides	n	EMP	EIMP	Insertion of the tendon of the EMP/EIMP		
				Radial near ED-middle	Palmar face of ED-middle	Ulnar near ED-middle
Left	31	6 (11.1%)	0	1 (1.8%)	2 (3.7%)	3 (5.5%)
Right	23	6 (11.1%)	1 (1.9%)	2 (3.7%)	2 (3.7%)	3 (5.5%)
Total	54	12 (22%)	1 (1.9%)	3 (5.5%)	4 (7.4%)	6 (11.1%)

EIMP: Extensor indicis medii proprius; EMP: Extensor medii proprius; ED: Extensor digitorum; EIP: Extensor indicis proprius.

EXTENSOR INDICIS PROPRIUS MUSCLE (EIP)

Extensor indicis proprius muscle (EIP) originated from the posterior surface of the distal third of the ulna and the interosseous membrane, coursed distally within the fourth dorsal compartment deep in the ED tendons in all 54 hands (Figures 1-6). The absence of the EIP tendon was not observed. The EIP tendon originated from its muscle belly as a single tendon in 47 specimens (87.03%) (Figure 1a, 2a). A double tendon which was called EIP-ulnar and EIP-radial occurred in seven of the cases (12.96%) (Figure 1b,1c, 2c, 2d). Triple tendon of the EIP was not observed.

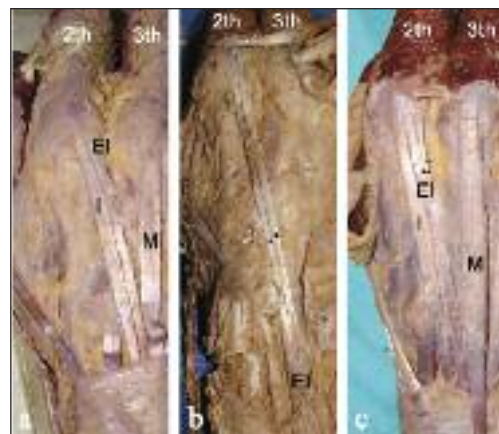


FIGURE 1: a: single extensor indicis proprius (EI), b and c: double EIP (arrow). I: extensor digitorum-indicis, M: extensor digitorum-middle.

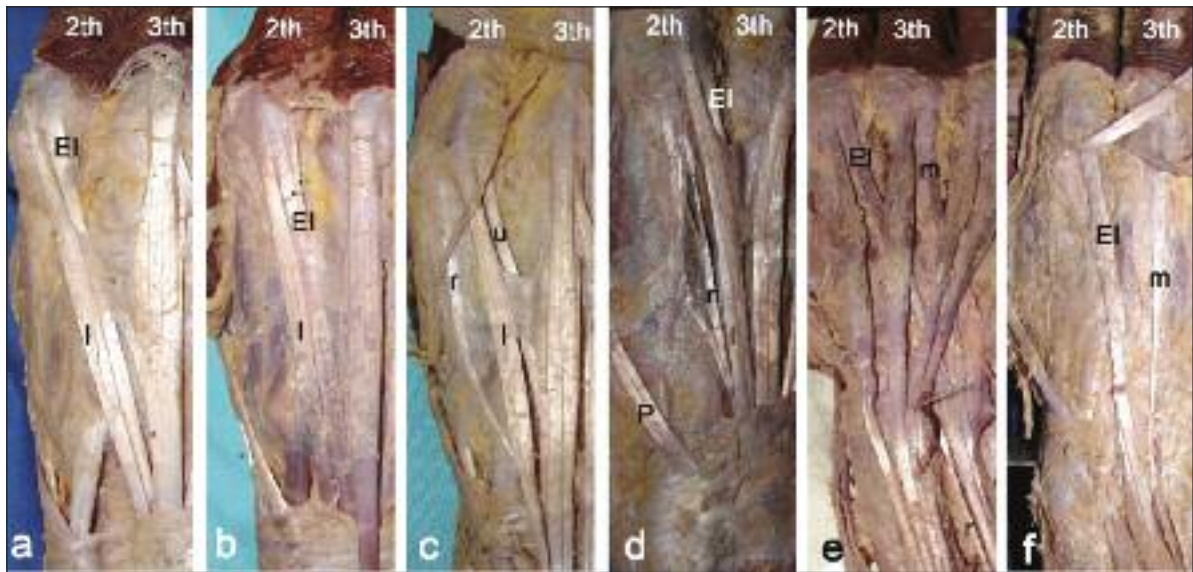


FIGURE 2: Types of the extensor indicis proprius muscle (EI). **a:** Classic type of the EIP muscle. **b:** The EIP tendon is dividing into two slips on the index finger. **c:** The EIP tendon dividing into the radial (r) and the ulnar (u) tendons. **d:** The r is connected to the tendon of the extensor pollicis longus muscle by the intertendinous fascia (*). **e:** Additional extensor medii proprius muscle (m) tendon to type B. **f:** There is extensor medii proprius muscle (m) additional to type A. I: extensor digitorum-indicis, u: the ulnar tendon of the EIP, r: the radial tendon of the EIP, P: extensor pollicis longus muscle.

Fifty-four dissected hands were examined in order to study the variations of extensor tendons to the index finger, and the arrangements were classified into six types from A to F by referring to Komiyama's study (Figure 2a-f).³ The most frequently observed type was the classical type. The EIP generally ran ulnar to the ED-indicis in the classical type (Type A). As this was the only tendon found in 36 specimens (66.7%), this type was regarded as the classical type (Figure 1a, 2a). Bilateralism was observed in hands with 83.3% frequency.

Variations of the EIP were found in 18 hands (33.3 %) (Types B-F). In one case (1.85%), both of the bifurcated slips were situated at the ulnar side of the ED tendon of the index finger (Figure 2B), and this type was called as Type B. In Type C, which was observed in four specimens (7.4%), the variational second tendon was attached to the radial side of the dorsum of the index finger. This tendon and its muscle belly were regarded as the EIP-radial (Figure 2c). In Type D, a bilaterally different type was observed in two specimens (3.7%). In these specimens, the radial tendon bifurcated at the middle level of the metacarpus (Figure 2d). One

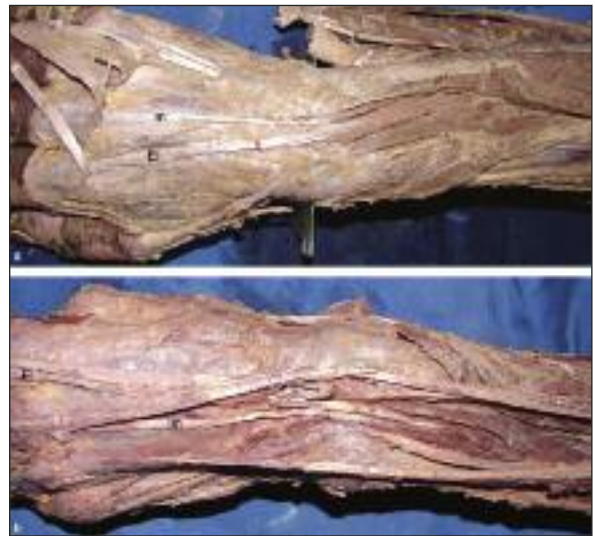

FIGURE 3: **a:** The extensor medii proprius muscle (m) had a belly originating from the distal third of the ulna near the extensor indicis proprius muscle (EI) **b:** In one specimen, the m had a shared belly with the extensor indicis medii proprius muscle (im).

of these slips inserted into the radial side of the dorsum of the index finger. The other slip was connected to the tendon of the extensor pollicis longus. In Type E, bilaterally additional to this sample, Type D with the EMP muscle was observed in two hands

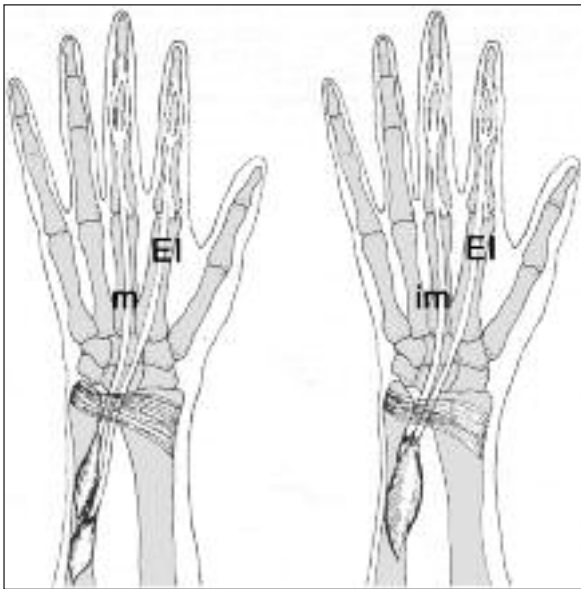


FIGURE 4: Schematic illustrations of the extensor indicis proprius muscle (EI), tendon of the extensor indicis medii proprius muscle (im) and extensor medii proprius muscle (m).

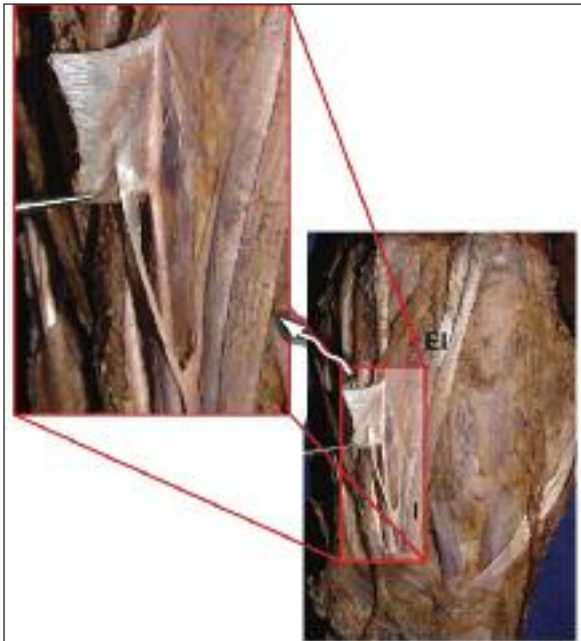


FIGURE 5: A slip from the extensor indicis proprius muscle (EI) tendon joins type 1 junctura in the second intermetacarpal space.

(3.7%), (Figure 2e). In Type F, Type A and the EMP muscle was observed in nine specimens (16.6%) (Figure 2f). In one specimen, a slip from the EIP tendon was attached to type 1 junctura in the second intermetacarpal space (IMC). This insertion was very thin (Figure 5).

EXTENSOR MEDII PROPRIUS MUSCLE (EMP) AND EXTENSOR INDICIS MEDII PROPRIUS (EIMP)

The EMP had a belly originating from the distal third of the ulna near the EIP and its tendon inserted into the dorsal aponeurosis of the proximal phalanges of the third finger in 12 hands (22.2%) (Figures 2e, 2f, 3, 4). In all the specimens, the muscle passed through the 4th compartment and it was seen at the ulnar side of the EIP in 11 of the specimens. In one right specimen, the EMP had a shared belly with the EIMP (1.85%) (Figure 3b).

The insertion features of the EMP and the EIMP are shown in Table 3. Whether EMP or EIMP, the tendon to the middle finger on the hand was at the radial side of ED-middle in three specimens, on the palmar side in four specimens (Figure 3b), and at the ulnar side in six specimens (Figure 3a, Table 3). In one right hand, a thin tendon slip from the radial side of the EIP inserted into the ED-indicis, which was more superficial. A bilateral difference was observed in the EMP insertion in two hands. It was placed at the radial side of the ED-middle tendon and inserted on the palmar side of the JT type 1 in the second IMC space. In all the other specimens, however, the insertion of EMP ended in the dorsal aponeurosis of the proximal of the first phalanx. In one specimen, an aponeurotic thickening was detected between the tendons of the EIMP on the hand in the second intermetacarpal space.

JTs of the finger extensors were seen in three types. In this series, the JT of the first IMC space was absent in 100% of the specimens. The JT of the

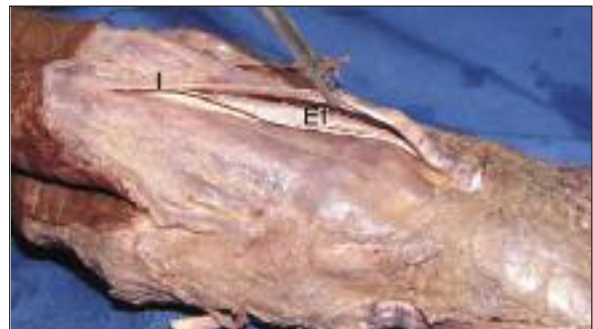

FIGURE 6: A slip from the extensor indicis proprius muscle (EI) tendon joins the extensor digitorum-indicis (I).

second IMC space was classified as type I and it was seen in 57.4% of the hands while it was absent in 38.8% (Figures 5, 6). Neither the EMP nor the EIMP tendons had a JT attachment (Figures 3b, 4). The extensor digitorum brevis manus and the extensor indicis accessories were not seen in any of the specimens.

DISCUSSION

The arrangements of the extensor tendons of the hand have a great variability, however, various investigators are not in agreement.^{2,4,11} The index finger receives two tendons that the EIP is never observed to have a junctural connection with, allowing a greater independent motion.^{2,4,7,11,12}

The EIP is commonly used to restore mobility for a variety of hand movements, owing to its ease of exposure, appropriate length and excursion, and retention of function after transfer. Previous researchers reported that the transfer of the EIP might be contraindicated in patients whose occupation requires independent movements of the index finger (e.g typists and musicians) as the use of the EIP focuses on extensor lag or residual weakness.¹⁶ Furthermore, an increase in the second or third IMC space caused by the presence of the variational muscles may result in pain and disability.¹³ In clinical cases, these variational muscles have often been misdiagnosed as a ganglion or tumor.²² Therefore, the variations of tendons of the index finger are important.

As it is reported in literature, distribution patterns of the EIP tendons reported by various investigators are not all in agreement.^{6,7,11,14} The tendons of the EIP muscle are always positioned at the ulnar side of the ED-indicis tendon, a finding in agreement with the previous studies.^{4,7,14,23,24} The EIP tendon inserts ulnar to the ED-indicis finger in 81-87% of the specimens.^{12,14,23} The EIP tendon is directly palmar to the ED tendon in 10-11% of the specimens, and radial to the ED tendon in 3-8% of them.^{2,4,7}

This feature of insertion of the EIP tendon is a valuable data for making transfer through a small incision. Double tendons have been reported to oc-

cur at the origin in 2.2 to 16% of the specimens and at the insertion in 5.5 to 12% of the specimens.^{2,5,14} Triple tendons have previously been reported in 2.8 to 5% of the specimens at the origin and in 2 to 3.9% at the insertion.^{2,5,11,14} Four tendons have been observed to occur in 0.5% of the specimens.¹⁴

In the present study, there was a single tendon at the insertion in 87% of specimens, and a double tendon in 13% of the specimens. The EIP-radial has previously been observed in 1.3 to 6.9% of the specimens.^{2,4,7,11,12} In our study, the EIP-radial was observed in 14.8% of the specimens (Types C,D,E).

The EMP is a deep muscle analogous to the EIP, but it inserts into the palmar and ulnar aspects of the ED-middle. Similar to the present study, a high incidence (3.5 to 12%) of EMP has been reported in literature.^{6,7,11,14} The EIMP is an EIP muscle with its tendon splitting to insert into both index and middle fingers with a reported incidence of 2% and 6.5% in previous studies.^{7-9,13} In our study, this rate was found as 1.85%.

The JTs are also useful for proper identification of the tendons of the hand and have been used in the repair of the dorsal aponeurosis.^{4,24} The JT in the second IMC space was believed to play an insignificant role in the normal functions because type 1 JT was very thin and not strong enough to transmit force. In von Schroeder and Botte series, the JT of the first IMC space was absent in 100% of the cases.^{2,7} The JT of the second IMC space which was classified as type I was present in 88% of the hands while it was absent in 12%. While the low incidence of the JT from the index finger to the thumb and to the middle finger increase the mobility of the digit, it may also cause the tendon to have more damage during a possible tendon damage. In this study, the JT of the first IMC space was absent in 100% of the specimens. The JT of the second IMC space was classified as type I and it was seen in 57.4% of the hands while it was absent in 38.8%. The EIP, EMP and EIMP never had a JT attachment. Therefore, we agree with von Schroeder and Botte² in that we believe the EIP tendon transfer is a reliable method for maintaining inde-

pendent index finger extension if the hood is preserved, and if the JT, whether type 1 and 2, is present.

To understand the existence of the variant muscles of the EIP, it is necessary to investigate the developmental features of the extensor muscle layer of the forearm. During limb development the tendons originate from the lateral plate mesoderm, while the limb musculature is derived from the migrating somatic mesoderm.^{14,25} Phylogenetic comparisons between the species show that the EMP or the EIMP are found in the Old World monkey, the EIP is seen in chimpanzee and gorilla, when the EMP or the EIMP are variable in man.^{24,25} The variations of the extensor tendons of the index finger result from the proximal migration of the deep layer muscles and the distal migration of the superficial layer muscles, the function of the two groups become redundant; hence, the EMP, the EIMP, or other variations of the deep group are lost. This suggests that the variant muscles of EIP are evolutionary remnants and not variations of a normal arrangement. El-Badawi et al. suggested that these variations might be related to the ethnic differences.¹⁴

This study is important in terms of giving accurate knowledge on the pattern of the variational extensor tendons of the index finger. Findings about the landmarks of the tendons and side symmetry are to be carefully considered. No differences at a significance level of $p > 0.01$ was observed in the right-left side comparison of the data, in all of the parameters. It has been stated that the variations observed in the EIP and the EMP can occur due to the symmetrical development of the right and left

sides. Our results showed that there was a general agreement between the studies regarding the incidence of supernumerary tendons were more frequently encountered at the ulnar side of the ED-indicis tendon than at the radial side. There was no junctural connection. In this study, the first surprise was the large incidence of EMP (24%). The second one is that of a double sling EIP (13%); a well-known variation which was never encountered by the reviewer. During the EIP tendon transposition to the ED-indicis, the tendons must be identified very carefully because of the numerous variants of the deep extensors. Transposition of the ED-indicis or just one tendon of a double-tendoned EIP by mistake, will make separate extension of the index impossible postoperatively. However, there is no previous detailed research that investigated whether EIP had a double insertion ulnar and radial to the EDC-indicis.

An understanding of the anatomical features of the extensor tendons is important to get successful results from the surgical procedures. Because the extensor tendon is a structure at risk in many surgical procedures (a serious traffic accident, an incisor brow wounds, foreign bodies, and hand trauma), the hand surgeon and the plastic surgeon would benefit from a clearer understanding of its anatomy and relationship. It is an indisputable fact that the success in surgical strategy and planning mainly relies on the surgeon's knowledge of the variational muscles of the index finger.

Acknowledgements

Authors express their gratitude to Funda Yılmaz for providing English Language support.

REFERENCES

1. Rockwell WB, Butler PN, Byrne BA. Extensor tendon: anatomy, injury, and reconstruction. *Plast Reconstr Surg* 2000;106(7):1592-603.
2. von Schroeder HP, Botte MJ. Anatomy of the extensor tendons of the fingers: variations and multiplicity. *J Hand Surg Am* 1995;20(1):27-34.
3. Komiyama M, Nwe TM, Toyota N, Shimada Y. Variations of the extensor indicis muscle and tendon. *J Hand Surg Br* 1999;24(5):575-8.
4. Celik S, Bilge O, Pinar Y, Govsa F. The anatomical variations of the extensor tendons to the dorsum of the hand. *Clin Anat* 2008;21(7):652-9.
5. Hirai Y, Yoshida K, Yamanaka K, Inoue A, Yamaki K, Yoshizuka M. An anatomic study of the extensor tendons of the human hand. *J Hand Surg Am* 2001;26(6):1009-15.
6. Gonzalez MH, Weinzeig N, Kay T, Grindel S. Anatomy of the extensor tendons to the index finger. *J Hand Surg Am* 1996;21(6):988-91.

7. von Schroeder HP, Botte MJ. The extensor medii proprius and anomalous extensor tendons to the long finger. *J Hand Surg Am* 1991; 16(6):1141-5.
8. Cigali BS, Kutoglu T, Cikmaz S. Musculus extensor digiti medii proprius and musculus extensor digitorum brevis manus - a case report of a rare variation. *Anat Histol Embryo* 2002; 31(2):126-7.
9. Cavdar S, Sehirli U. The accessory tendon of the extensor indicis muscle. *Okajimas Folia Anat Jpn* 1996;73(2-3):139-42.
10. Yalçın B, Kutoglu T, Ozan H, Gürbüz H. The extensor indicis et medii communis. *Clin Anat* 2006;19(2):112-4.
11. Yoshida Y. Anatomical studies on the extensor pollicis et indicis accessorius muscle and the extensor indicis radialis muscle in Japanese. *Okajimas Folia Anat Jpn* 1995;71(6): 355-63.
12. Zilber S, Oberlin C. Anatomical variations of the extensor tendons to the fingers over the dorsum of the hand: a study of 50 hands and a review of the literature. *Plast Reconstr Surg* 2004;113(1):214-21.
13. Tan ST, Smith PJ. Anomalous extensor muscles of the hand: a review. *J Hand Surg Am* 1999;24(3):449-55.
14. el-Badawi MG, Butt MM, al-Zuhair AG, Fadel RA. Extensor tendons of the fingers: arrangement and variations--II. *Clin Anat* 1995;8(6): 391-8.
15. Karapinar H, Altay T, Sener M. [Extensor tendon injuries]. *Türkiye Klinikleri J Surg Med Sci* 2006;2(17):21-6.
16. Browne EZ Jr, Teague MA, Snyder CC. Prevention of extensor lag after indicis proprius tendon transfer. *J Hand Surg Am* 1979;4(2): 168-72.
17. Gelb RI. Tendon transfer for rupture of the extensor pollicis longus. *Hand Clin* 1995;11(3): 411-22.
18. Goloborod'ko SA. Treatment of interphalangeal hyperflexion and metacarpophalangeal hyperextension of the thumb in combined low median-ulnar nerve palsy. *J Hand Surg Am* 1998;23(6):1059-62.
19. Ertaş NM, Çelebioğlu S. [The treatment of complicated digital defects by cross-finger adipofascial flap]. *Türkiye Klinikleri J Med Sci* 2004;24(2):153-8.
20. Özkan T. [Paralytic hand]. *Türkiye Klinikleri J Surg Med Sci* 2006;2(17):89-93.
21. Shah MA, Buford WL, Viegas SF. Effects of extensor pollicis longus transposition and extensor indicis proprius transfer to extensor pollicis longus on thumb mechanics. *J Hand Surg Am* 2003;28(4):661-8.
22. Patel MR, Moradia VJ, Bassini L, Lei B. Extensor indicis proprius syndrome: a case report. *J Hand Surg Am* 1996;21(5):914-5.
23. Tan ST, Smith PJ. Reversed extensor indicis proprius muscle and dorsal wrist pain. *Br J Plast Surg* 1998;51(2):128-30.
24. Yamaguchi S, Viegas SF. Extensor indicis proprius tendon: case report of a rare anatomic variation. *Clin Anat* 2000;13(1):63-5.
25. Chevallier A, Kieny M, Maugey A. Limb-somite relationship: origin of the limb musculature. *J Embryol Exp Morphol* 1977;41:245-58.