

A Rare Case: ST Segment Elevation Myocardial Infarction due to Spontaneous Extensive Left Coronary Artery Dissection

Nadir Bir Olgu: Spontan Sol Ön İnen Arter Diseksiyonuna Bağlı Gelişen ST Yükselmeli Miyokard İnfarktüsü

Taner ŞEKER,^a
Ahmet Oytun BAYKAN,^a
Mustafa GÜR,^b
Alaa QUISI,^a
Murat ÇAYLI^a

^aClinic of Cardiology,
Adana Numune Training and
Research Hospital, Adana

^bDepartment of Cardiology,
Kafkas University Faculty of Medicine,
Kars

Geliş Tarihi/Received: 22.11.2015
Kabul Tarihi/Accepted: 06.04.2016

Yazışma Adresi/Correspondence:
Taner SEKER
Adana Numune Training and
Research Hospital,
Clinic of Cardiology, Adana,
TÜRKİYE/TURKEY
atanerseker@hotmail.com

ABSTRACT Spontaneous coronary artery dissection is a rare cause of acute coronary events or sudden cardiac death. It most commonly occurs in young women in the peri-partum period. The etiology remains uncertain. Possible mechanisms are hormonal changes, hemodynamic stress and modifications in the immune system during pregnancy. Treatment strategies include medical management, percutaneous coronary intervention (PCI) and surgical revascularization. We describe the case of a young woman presenting with spontaneous coronary artery dissection of the left anterior descending coronary artery, which was successfully treated with PCI. Spontaneous coronary artery dissection is a rare but important cause of myocardial ischaemia and infarction in young, healthy women, without classical coronary risk factors. Immediate coronary angiography is essential to establish an early diagnosis and allowing a therapeutic decision.

Key Words: Acute coronary syndrome; dissection

ÖZET Spontan koroner arter diseksiyonları akut koroner sendrom ve ani kardiyak ölümün nadir bir sebebidir. Daha çok peripartum dönemdeki genç kadınlarda görülmektedir. Etiyolojisi tam olarak bilinmemekle beraber gebelikteki hormonal değişiklikler, hemodinamik stres ve immün sistemdeki değişiklikler muhtemel mekanizmalardır. Tedavi seçenekleri arasında medikal takip, perkütan koroner girişim ve cerrahi revaskülarizasyon bulunmaktadır. Biz bu olgu raporumuzda spontan koroner diseksiyonuna bağlı ST yükselmeli miyokard infarktüsü ile başvuran genç kadın hastanın perkütan koroner girişim ile başarılı tedavi edilmesini sunduk. Spontan koroner arter diseksiyonları klasik kardiyovasküler risk faktörü eşlik etmeyen genç sağlıklı kadınlarda miyokardiyal iskeminin ve infarktüsün nadir fakat önemli bir sebebidir. Bu hastalarda tedavi stratejisinin belirlenmesi için acil anjiyografi ile tanısı konulup tedavi stratejisi belirlenmelidir.

Anahtar Kelimeler: Akut koroner sendrom; diseksiyon

Türkiye Klinikleri J Case Rep 2016;24(2):118-22

Spontaneous coronary artery dissection (SCAD) is a rare cause of acute coronary syndrome.¹ SCAD has been described in three groups of patients: in patients with significant coronary atherosclerotic disease, women in the peripartum and early post-partum period or using oral contraceptives (pregnancy-associated SCAD, P-SCAD), and in patients without risk factors, termed idiopathic SCAD.^{2,3} It often affects young women and usually involves a single coronary artery, mainly the left anterior descending (LAD) artery.^{4,5} The clinical presentation ranges from asymptomatic patients to the whole spectrum of acute coronary syndrome

doi: 10.5336/caserep.2015-48697

Copyright © 2016 by Türkiye Klinikleri

manifestations.¹ Pathogenesis and optimal management of SCAD are still controversial.^{6,7} Treatment strategies include medical management, percutaneous coronary intervention and surgical revascularization.⁷⁻¹⁰

We report the case of a young woman who presented with anterior ST elevation myocardial infarction due to SCAD of LAD and underwent successful percutaneous coronary intervention (PCI).

CASE REPORT

A 32-year-old woman with no significant medical history was admitted with sudden onset of substernal chest pain. Ten days earlier she underwent an uncomplicated cesarean delivery performed at 38 weeks' gestation and this was her third baby (G3P3). Her pregnancy and delivery was uneventful. On the day of presentation she was breastfeeding her infant when her chest pain recurred and persisted. Initially mild, it became progressively more severe over the course of several hours, with radiation to her back and left shoulder. It was sharp, substernal, associated with shortness of breath (SOB) and diaphoresis. She also

noticed left arm numbness and tingling. She had never experienced this pain before. She had no known risk factors for atherosclerotic disease and no history of any connective tissue disorder. She did not smoke and did not use alcohol or drugs. There was no family history of premature coronary artery disease.

On admission, physical examinations were unremarkable. Initial electrocardiography (ECG) demonstrated ST-segment elevation at V1-6 (Figure 1). She was given 300 mg aspirin and 600 mg clopidogrel, unfractionated heparin and treated with antiischemic drugs. The patient underwent emergency cardiac catheterization which revealed long, linear filling defect in whole LAD, beginning from the LAD ostium and extending to the end of LAD and involving Diagonal-2 branch (Figures 2, 3). Otherwise the coronary arteries were free of angiographically visible atherosclerosis. The patient was still having pain at the time of catheterization and ST elevation on ECG. The LAD dissection was treated with primary stenting without predilation. A 2.5x26 mm drug eluting stent (DES) (Scimed, Boston Scientific, Natick, MA) was deployed dis-

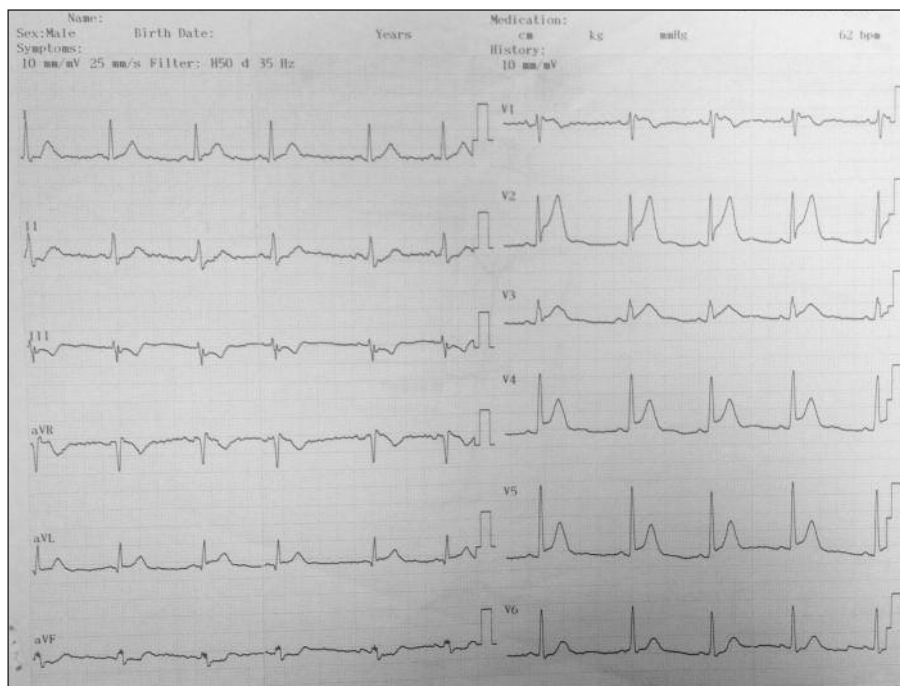


FIGURE 1: Emergency Department electrocardiogram (ECG) demonstrating sinus rhythm and evolving anterior ST-elevation myocardial infarction.

tally. A second 2.75x24 mm DES (Scimed, Boston Scientific, Natick, MA) was then deployed proximal to the first stent with an overlap of 1 mm. The third stent 3.0x24 mm DES (Scimed, Boston Scientific, Natick, MA) was deployed finally for proximal LAD. After deployment, the last stent was postdilated with a 3.5.x15 mm non-complaint balloon (Brosmed Medical, Netherlands). An excellent angiographic result was achieved (Figures 4, 5). She had no pain after the catheterization and the ECG after angiography was show no ST elevation (Figure 6). A serum lipid profile was normal. During hospitalization there was no further ischemic chest pain. To assess the cardiac function transthoracic echocardiography was performed that showed left

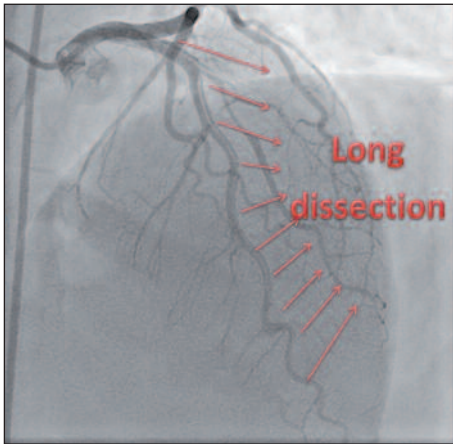


FIGURE 2: Coronary angiogram shows the large spiral shaped dissection distal to proximal along the left anterior descending coronary artery (arrows).

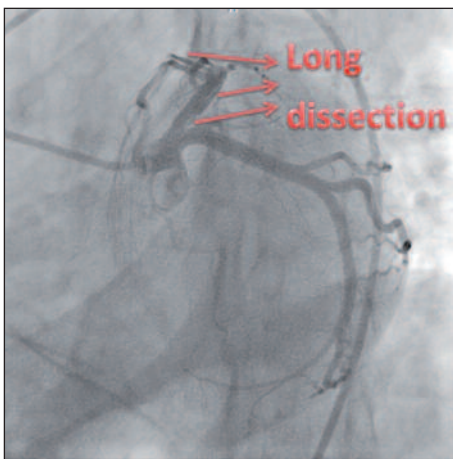


FIGURE 3: Left anterior coronary artery with a dissection starting from ostium (arrows).

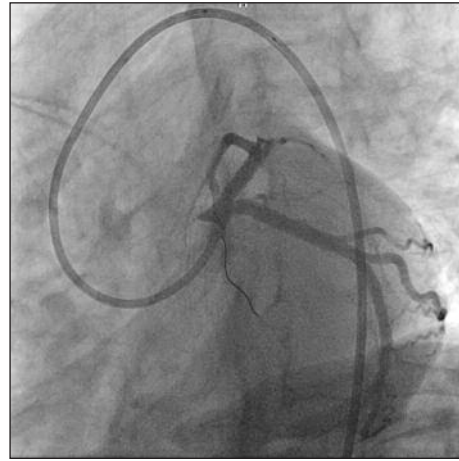


FIGURE 4: After stenting Left anterior coronary artery with an excellent result and distal thrombolysis myocardial infarction (TIMI-3) flow.

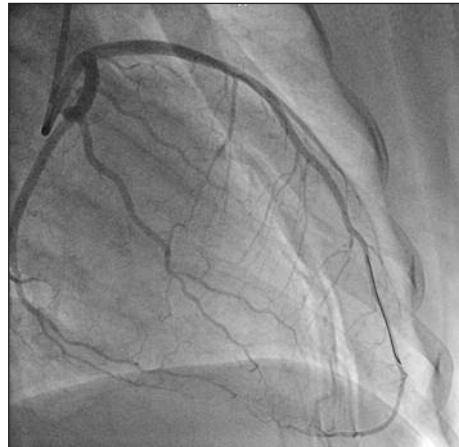


FIGURE 5: After stenting Left anterior coronary artery with an excellent result and distal TIMI-3 flow in other view.

ventricular apical hypokinesia with an ejection fraction (EF) of 40% to 45%.

The patient was discharged after fourth day on an antiplatelet regimen of aspirin 100 mg and clopidogrel 75 mg and anti-ischemic drugs including ACE inhibitory and beta blocker. After 3 mo of follow-up, the patient remains well, with no recurrence of ischemic symptoms.

DISCUSSION

Spontaneous coronary artery dissection is one of the rare causes of acute coronary syndrome, particularly among young healthy individuals. Its incidence ranges from 0.07 to 1.1% in angiographic series.^{1,9} The most of the cases (70-75%) are diag-

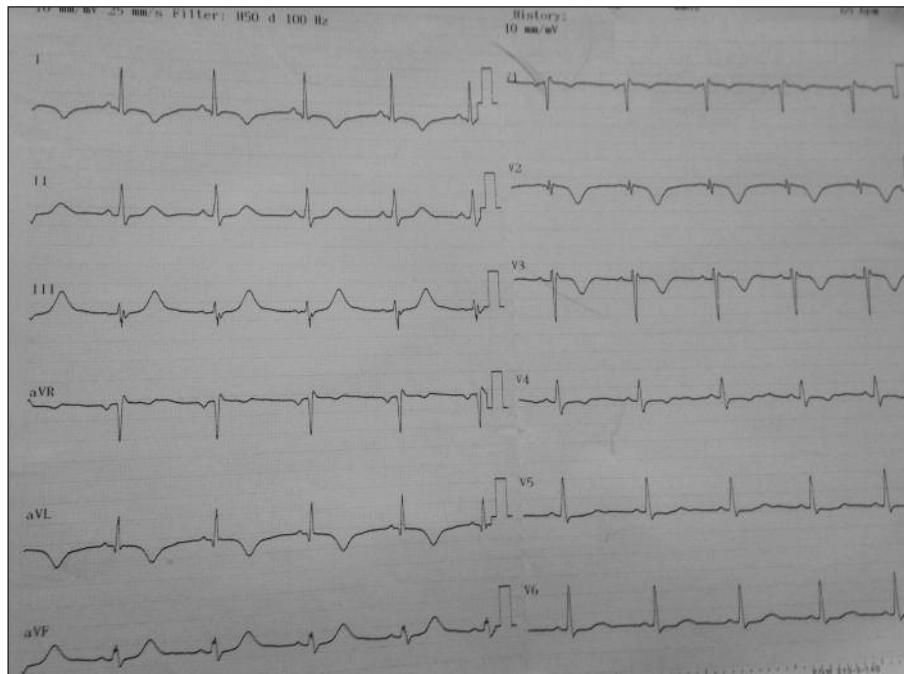


FIGURE 6: ECG after stenting shows no ST elevation and keep R wave progression was preserved on anterior leads with biphasic T wave in V1-V3 and d1-aVL.

nosed post mortem.¹¹ More frequently spontaneous coronary dissection is observed in women, particularly during the post-partum period or in women on oral contraception.^{3,12} The etiologies of spontaneous dissection may include hypertension, Marfan syndrome, connective tissue disease or immune system disease and sometimes, a recent chest trauma is related to a spontaneous dissection. Intense physical exercise, prolonged sneezing, cyclosporine and cocaine abuse are rarer causes.^{1,3,4,9} Dissection is commonly observed at LAD (75%) and with multivessel and left main coronary artery (LMCA) involvement in 20% and 12% of cases.^{1,3,4} Also, spontaneous dissections of right coronary artery (RCA) were reported in literature.⁵ The initial event leading to dissection is not clear, and no single factor has been found to be causative.¹³ Many of the proposed mechanisms pertain to changes in vascular wall properties that lead to weakening of the media and connective tissue. These include changes in smooth-muscle-cell metabolism, the effect of proteases released from eosinophilic infiltrates, and pregnancy related changes in connective tissue.¹³

Given the rarity of the condition, there is no prospective randomized controlled data available

to guide management of SCAD. Management decisions are generally based on clinical presentation, angiographic characteristics, and to prevent potential adverse clinical outcomes. Conservative medical therapy, percutaneous coronary revascularization, and coronary artery bypass grafting (CABG) are available options. The treatment selection should be made on the clinical symptoms, extent and location of dissection, as well as the preservation of distal coronary flow.

Conservative management has yielded positive results. Medical treatment can be considered in asymptomatic patients.¹² Medical management includes antithrombotic therapy with heparin or low molecular weight heparin, aspirin, clopidogrel and glycoprotein IIb/IIIa inhibitors, and anti-ischemic therapy with beta-blockers and nitrates. However, it should be borne in mind that while potent antithrombotic therapy decreases thrombus formation in the false lumen, enhancing blood flow in the true lumen, which can also increase bleeding into the false lumen, causing extension of the dissection. This is especially true for fibrinolytics and their use should generally be avoided.¹ Medical treatment in stable patients without evidence for

ongoing ischemia has a good overall prognosis with a majority of them showing spontaneous healing of the SCAD on follow-up angiography.¹⁴

If there is an evidence of ongoing ischemia such as cardiogenic shock, hemodynamic or electrical instability, revascularization should be considered with CABG or PCI.¹⁵ In single-vessel dissection not involving the LMCA, with persistent impairment of blood flow and signs of ongoing ischemia, PCI with stenting is the procedure of choice.^{1,3,8} However, PCI in patients with SCAD have been reported to have higher initial technical failure rates in approximately one-third of the patients, requiring additional stenting due to extension of dissection or intramural hematoma.^{3,15} So, intravascular ultrasound and optical coherence tomography may be of value in identification of the true lumen.⁸ The use of drug-eluting stents (DES) in SCAD is questionable. While the frequent need for long stented segments in these cases may justify the preferential use of DES, on the other hand, these stents may delay vessel wall healing. The choice between baremetal stents and DES remains

subject of disagreement.⁸ We used DES for our case because of long dissection. CABG is usually reserved for patients with LMCA dissection, multi-vessel involvement and failed PCI.^{1,8} Nevertheless, in selected cases LMCA and multivessel dissections may be treated by stenting as well.^{8,10}

The treatment selection should be made on the clinical symptoms, extent and location of dissection, as well as the preservation of distal coronary flow. Our case illustrates that intracoronary stenting may prove to be the treatment of choice for patients with single-vessel SCAD not involving the left main coronary artery and chest pain with ST elevation on ECG.

Spontaneous coronary artery dissection is a rare but important cause of myocardial ischaemia and infarction in young, healthy women, without classical coronary risk factors. Immediate coronary angiography is essential to establish an early diagnosis and allowing a therapeutic decision. We describe a case report diagnosed with ST elevation myocardial infarctus due to SCAD which treated with primer percutaneous coronary intervention.

REFERENCES

- Vrints CJM. Spontaneous coronary artery dissection. *Heart* 2010;96:801-8.
- DeMaio SJ Jr, Kinsella SH, Silvermann ME. Clinical course and longterm prognosis of spontaneous coronary artery dissection. *Am J Cardiol* 1989;64(8):471-7.
- Maeder M, Ammann P, Angehrn W, Rickli H. Idiopathic spontaneous coronary artery dissection: incidence, diagnosis and treatment. *Int J Cardiol* 2005;101(3):363-9.
- Mortensen KH, Thuesen L, Kristensen IB, Christiansen EH. Spontaneous coronary artery dissection: a Western Denmark Heart Registry Study. *Catheter Cardiovasc Interv* 2009;74(5):710-7.
- Cilingiroğlu M, Rahman S, Helmy T, Seshieh P. Spontaneous right coronary artery dissection possibly associated with clonidine transdermal patch. *Turk Kardiyol Dern Ars* 2011;39(3):224-7.
- Kamini R, Sadhu A, Alpert J. Spontaneous coronary artery dissection: report of two cases and a 50-year review of the literature. *Cardiol Rev* 2002;10(5):279-84.
- Sarmento-Leite R, Machado PR, Garcia SL. Spontaneous coronary artery dissection: stent or wait for healing. *Heart* 2003;89(2):164.
- Adlam D, Cuculi F, Lim C, Banning A. Management of spontaneous coronary artery dissection in the primary percutaneous coronary intervention era. *J Invasive Cardiol* 2010;22(11):549-53.
- McCann AB, Whitbourn RJ. Spontaneous coronary artery dissection: a review of the etiology and available treatment options. *Heart Vessels* 2009;24(6):463-5.
- Thistlethwaite PA, Tarazi RY, Giordano FJ, Jamieson SW. Surgical management of spontaneous left main coronary artery dissection. *Ann Thorac Surg* 1998;66(1):258-60.
- Jorgensen MB, Aharonian V, Mansukhani P, Mahrer PR. Spontaneous coronary dissection: a cluster of cases with this rare finding. *Am Heart J* 1994;127(5):1382-7.
- Evangelou D, Letsas KP, Korantzopoulos P, Antonellis I, Sioras E, Kardaras F. Spontaneous coronary artery dissection associated with oral contraceptive use: a case report and review of the literature. *Int J Cardiol* 2006;112(3):380-2.
- Dhawan R, Singh G, Fesniak H. Spontaneous coronary artery dissection: the clinical spectrum. *Angiology* 2002;53(1):89-93.
- Alfonso F, Paulo M, Lennie V, Dutary J, Bernardo E, Jiménez-Quevedo P, et al. Spontaneous coronary artery dissection: long-term follow-up of a large series of patients prospectively managed with a "conservative" therapeutic strategy. *JACC Cardiovasc Interv* 2012;5(10):1062-70.
- Saw J, Aymong E, Sedlak T, Buller CE, Starovoytov A, Ricci D, et al. Spontaneous coronary artery dissection: association with predisposing arteriopathies and precipitating stressors and cardiovascular outcomes. *Circ Cardiovasc Interv* 2014;7(5):645-55.