

One Stage Operation for the Treatment of a Complicated Maxillary Sinusitis Due to Complication of Sinus Lifting Procedure: Case Report

Sinüs Lifting Operasyonuna Bağlı Olarak Gelişen Komplike Maksiller Sinüzit Olgusunun Tek Aşamalı Tedavisi

S. Cemil İŞLER,^a
Erol CANSIZ,^a
Murat ULUSAN,^b
Yahya GÜLDİKEN^b

^aDepartment of Oral and Maxillofacial Surgery, İstanbul University Faculty of Dentistry,
^bDepartment of Ear-Nose-Throat Diseases, İstanbul University Faculty of Medicine, İstanbul

Geliş Tarihi/Received: 07.05.2012
Kabul Tarihi/Accepted: 07.01.2013

This study was presented as a poster at European Association for Osseointegration Congress, 13-15 January 2007, Atina, Greece.

Yazışma Adresi/Correspondence:
Erol CANSIZ
İstanbul University Faculty of Dentistry,
Department of Oral and Maxillofacial Surgery, İstanbul,
TÜRKİYE/TURKEY
erolca@yahoo.com

ABSTRACT Sinus lifting procedure is one of the most popular techniques for the dental implant placement in deficient maxillary alveolar ridges. Generally, autogenous, alloplastic or allogenic bone materials are used for the augmentation of the maxillary sinus. When the residual bone height of alveolar ridge is suitable, the bone augmentation and the implantation can be performed at the same time to reduce total rehabilitation period. Although, sinus lifting procedure is not considered as a difficult procedure, it is technically delicate. Poor operation technique or inappropriate indications can cause complications like perforation of sinus membrane, disturbed wound healing and maxillary sinusitis. In this case report we present a patient who has unilateral pansinusitis as a result of sinus lifting operation with immediate implantation. Functional Endoscopic Sinus Surgery and endoscopy assisted intraoral approach is used to remove the infected graft material and drain infected sinuses. Rotational palatal island flap and autogenous bone grafting is used for the closure of the oroantral fistula.

Key Words: Sinusitis; endoscopy; complications; sinus floor augmentation

ÖZET Sinüs lifting operasyonu, maksilla posterior bölgede kemik yetersizliği bulunan olgularda tercih edilen kemik ögментasyon yöntemleri arasında en popüler tekniklerden biridir. Genellikle kemik ögментasyonu için, otojen, allojen, alloplastik ya da ksenojeik kemik greftleri kullanılır. Kemik yüksekliğinin uygun olduğu olgularda, kemik ögментasyonu için gerçekleştirilen sinüs lifting operasyonu ve implant uygulaması aynı seansta gerçekleştirilebilir. Bu sayede total tedavi süresi kısalmır. Sinüs lifting operasyonu zor bir işlem olarak değerlendirilmese de, operasyonun teknik hassasiyet gerektiren bir işlem olduğu unutulmamalıdır. Ameliyat tekniğinin hatalı olması ya da yanlış endikasyon konulması gibi nedenlerle, sinüs membranı perforasyonu, yara iyileşme bozuklukları ya da maksiller sinüzit gibi komplikasyonlar gelişebilir. Bu vaka raporunda, sinüs lifting operasyonu sonrasında akut maksiller ünilateral pansinüzit gelişen olgu aktarılmıştır. Enfekte greft materyalinin çıkarılması için endoskopi destekli intraoral yaklaşım ve fonksiyonel endoskopik sinüs cerrahisi yapılmış, rotasyonel palatinal ada flebi ve otojen blok greftleme ile oroantral fistül tedavi edilmiştir.

Anahtar Kelimeler: Sinüzit; endoskopi; komplikasyonlar; sinüs taban yükseltmesi

Türkiye Klinikleri J Dental Sci 2015;21(3):240-6

Sinus lifting procedure is one of the most popular techniques for the dental implant placement in deficient maxillary alveolar ridges.¹ The procedure involves, gently elevation of the maxillary sinus mucosa and the placement of graft material between the bony floor and the elevated sinus mucosa.² Autogenous, allogenic or alloplastic bone grafts are mostly used for the augmentation.³

There are two main surgical approaches for sinus lifting procedure. First is the lateral window (external) and the other is crestal (internal) approach.¹ Due to its advantage related to the direct visualization of the sinus mucosa, lateral window approach is most frequently preferred. Although the complication rate is low in this technique, there are intraoperative and postoperative risks like perforation of sinus membrane, disturbed wound healing and maxillary sinusitis.⁴⁻⁸ Of those, perforation of the sinus membrane is very important, because it may lead to sinusitis, graft material spillage into the sinus and wound healing problems.⁹ If there is a perforation during operation, treatment of the perforation with resorbable barriers, such as collagen membranes etc., can be helpful.^{9,10}

Disturbed physiological air circulation and drainage in the maxillary sinus is the major factor of maxillary sinusitis development. When the ostium is obstructed by any reason, disturbed air circulation and physiological drainage of mucous secretions cause acceleration of bacterial activity. Under these circumstances, if there is also a perforation of the sinus membrane and spilled graft material in the sinus, infection may be inevitable.^{11,12}

The treatment of maxillary sinusitis in this scenario requires surgical removal of the graft material and the correction of the physiologic ostium activity, especially when the graft material is spilled into sinus and got infected. For this aim, functional endoscopic sinus surgery (FESS) and the removal of the infected graft material by intraoral approach can be performed.^{12,13}

In this case report we present a patient who have acute maxillary sinusitis, also affected the ethmoidal and frontal sinuses, due to complication of a sinus lifting operation and immediate implantation. FESS and endoscopy assisted intraoral approach is performed for the removal of the infected graft material and the correction of the ostium activity. Then, rotational palatal island flap technique and autogenous bone grafting is used for the closure of the oroantral fistula.

CASE REPORT

A 54-year-old, female, otherwise healthy patient was referred to our department by an otorhinolaryngologist with a history of recurrent left maxillary sinusitis after dental implantation. A sinus lifting procedure and immediate placement of two dental implants, for the rehabilitation of the teeth 26 and 27, were performed eight months ago by a dental practitioner. At the fourth month of the healing period, the anterior implant has failed and a new implant was placed immediately after the extraction of the tooth 25. No further information including the preoperative panoramic radiograph or computed tomography was available.

In her physical examination pain, swelling around the maxillary sinus region, post-nasal mucopurulent drip, bad odor in the mouth were observed but there were no signs about an oroantral fistulae formation. When the nasal region was examined by endoscopy, obstruction of the left maxillary sinus ostium was determined.

Radiographic examination revealed 2 implants placed into the left maxillary sinus and Water's projection revealed radiopacity filling in the left maxillary sinus (Figure 1). CT scan and MRI confirmed radiopacity in the left maxillary sinus and hypertrophy of the sinus mucosa (Figure 2,3). It was also observed that left ethmoidal sinuses and the frontal sinus were affected by the infection.

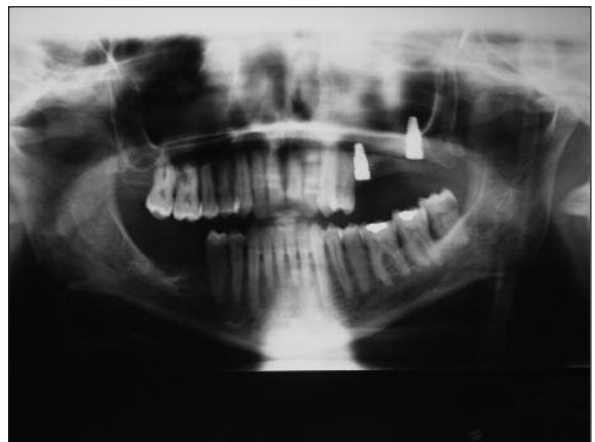

FIGURE 1: Panoramic radiograph of the patient.

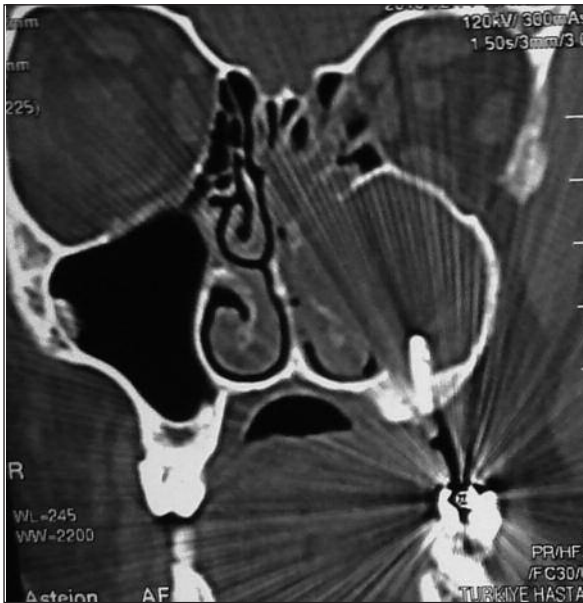

FIGURE 2: Computed tomography of the patient.

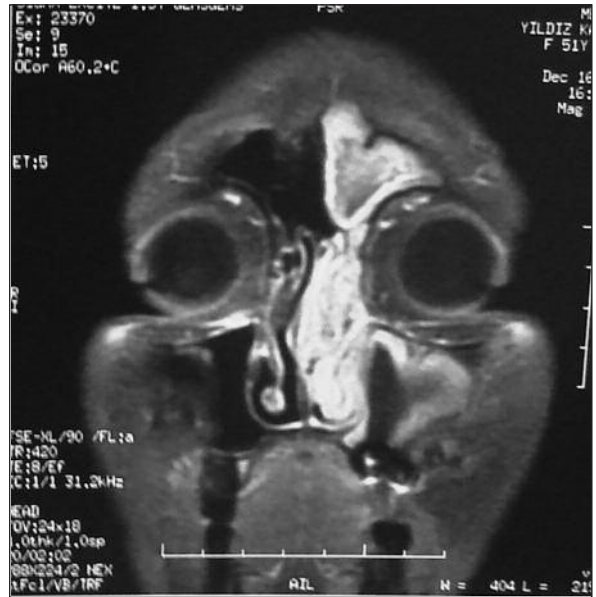

FIGURE 3: MRI of the patient.

Owing to the persistent signs and symptoms, functional endoscopic sinus surgery for the treatment of the ostium obstruction and endoscopy assisted intraoral approach for the removal of the infected graft material was planned. An attempt to treat the patient using only a standard intraoral approach was excluded because it would have allowed efficient removal of the alloplastic graft material but, it might not have assured adequate treatment of the obstructed maxillary ostium. Our experience with that kind of patients showed us that, the adequate ventilation of the maxillary sinus must be provided for the ideal treatment of the patients who suffer from sinusitis.

After induction of general anesthesia using orotracheal intubation, the procedure was started with alveolar crest incision and flap rising at the left posterior maxillary alveolar process. Although it was expected that there would be a bony window previously created to graft the sinus at the buccal site of the crest, it was observed that the sinus lifting was tried to perform from the top of the alveolar crest (Figure 4). By the assistance of endoscopy, mucopurulent secretions, infected bone grafts and infected granulomatous tissues were removed surgically followed by abundant rinsing with sterile saline solution through the bony window at the top of the crest. During this procedure

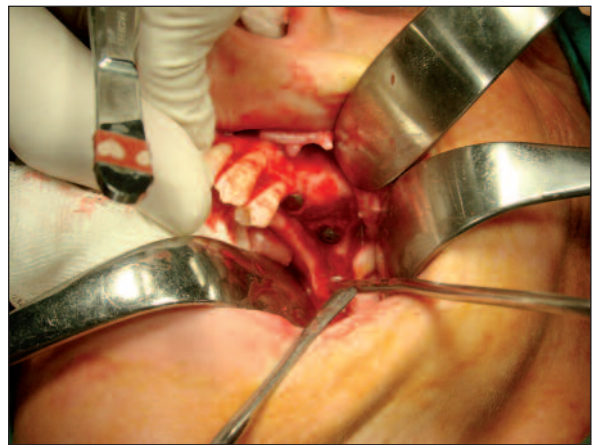


FIGURE 4: Initial stage of operation.

30 and 45° angled endoscopes and angled curettes were used. After that, implants placed into the sinus were removed (Figure 5).

At the end of the complete debridement of the sinus, FESS was performed by left uncinectomy, middle meatal antrostomy and left anterior ethmoidectomy (Figure 6). Frontal sinus and sphenoid sinus ostiums seem to be clear at the operation. At the first inspection through the natural ostium by 30° angled endoscope, the passage between the sinus and the middle meatus appeared to be obstructed with hyperplastic mucosa and infectious granulomatous tissues. Then, middle

meatal antrostomy was performed. After that, hyperplastic mucosa, residual infected bone graft material and infectious granulomatous tissues surrounding them were removed followed by abundant rinsing with sterile saline solution.

After the clearance of the sinus and the enlargement of the obstructed ostium, two pieces of autogenous block bone grafts were harvested from the mandibular symphysis region by trephine burs for the further reconstruction of the deficient alveolar crest (Figure 7). These blocks were harvested as the same diameter with the removed implants and they were adapted and stabilized to the holes of the extracted implants (Figure 8).

After the bony reconstruction, palatal island flap was raised and rotated preserving the descending palatine artery and passed through the full-thickness

tissue tunnel for the closure of the oroantral fistula (Figure 9). Then, the rotational and the buccal flaps were sutured to each other and to the incision sites with 3/0 polyglactin 910. After that, palatal bone remained open after the rotation of the flap was covered with a piece of oxydized cellulose (Figure 10).

At the end of the surgical operation, sinus pack was applied to prevent the postoperative bleeding. Broad spectrum antibiotics, nasal decongestions and non-steroid anti-inflammatory analgesic drugs were prescribed. The patient was discharged two days after.

After the surgery and the recovery period was uneventful. Six months later, there were no clinical symptoms and radiologic signs of sinusitis (Figure 11). However, the patient refused another dental implantation for the prosthodontic rehabilitation of the edentulous left posterior maxilla.

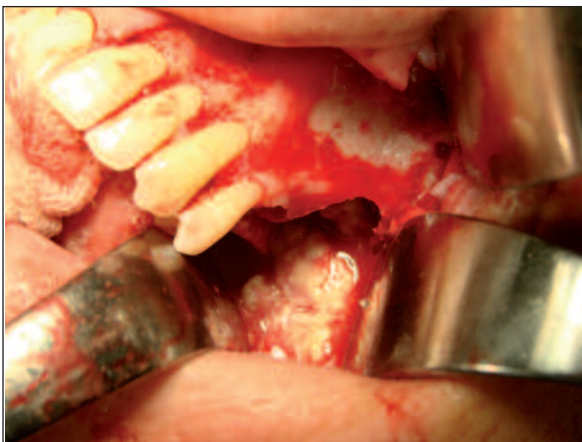

FIGURE 5: Complete removal of infected substance and implants.

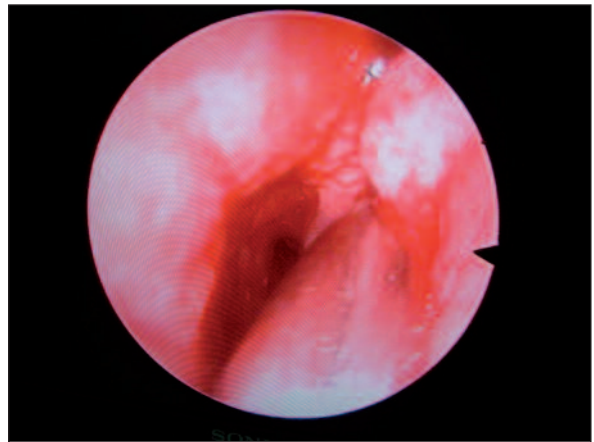


FIGURE 6: Functional endoscopic sinus surgery.

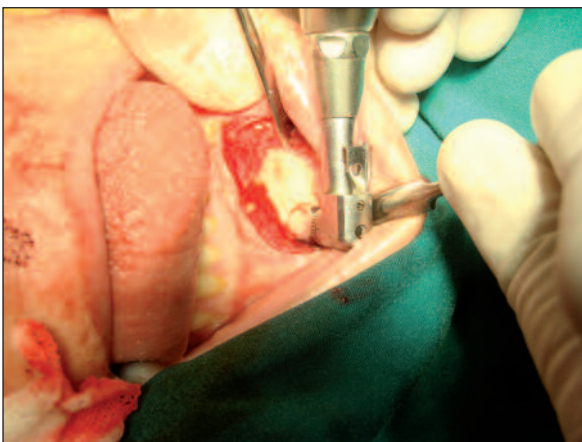


FIGURE 7: Bone harvesting from the anterior mandible with trephine burs.

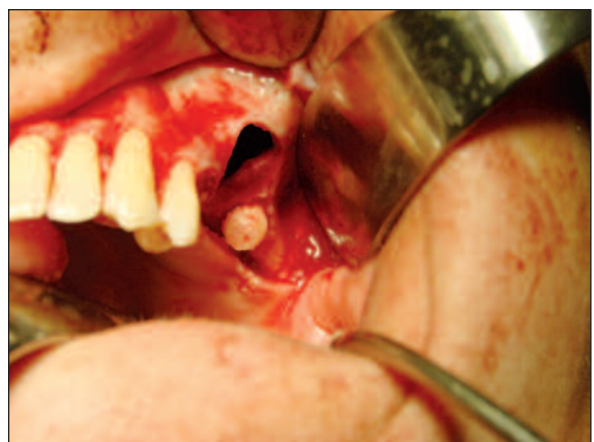

FIGURE 8: Stabilization of bone grafts.

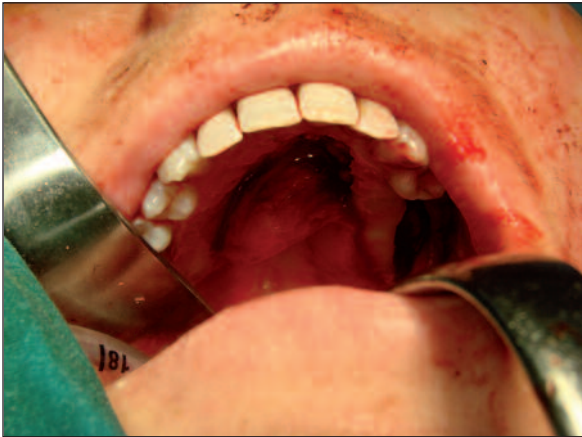

FIGURE 9: Palatal rotational island flap.

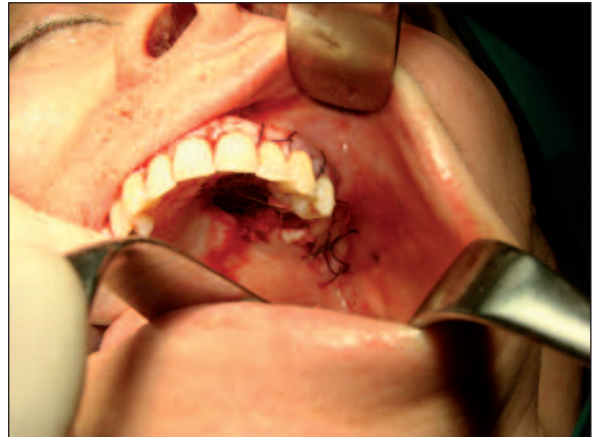

FIGURE 10: Flap closure and postoperative appearance.

DISCUSSION

Recently sinus lifting procedures have become very popular. Although, the rate of the sinus lifting complications are low (4%), the possibility should be taken into consideration.¹⁴ Perforation of the sinus membrane and disturbed wound healing are the major intraoperative complications and they can cause maxillary sinusitis due to contamination of the graft material from the oral and nasal bacterial flora.⁴ In this case, the patient suffered from severe maxillary sinusitis also affecting ethmoidal and frontal sinuses due to complication of sinus lifting procedure.

Our experience with the maxillary sinusitis due to infected graft material showed us that, ideal healing can be obtained only by the complete removal of the graft from the sinus. For this purpose, intraoral or nasal approaches can be performed.

Nasal approach is performed by the assistance of endoscopy. If the ostium is obstructed, the reopening of the ostium and the debridement of the sinus can be performed by functional endoscopic sinus surgery. 30 and 45° angled endoscopes are very helpful for the direct visualization of the ostium or sinus and angled curettes are needed for the clearance of the inferior sites of the sinus. Although, the angled curettes are useful, most of the time, complete debridement of the sinus cannot be performed by the angled curettes.¹³ For this reason, in this case, the nasal and the oral approaches were combined to remove the infected debris completely.

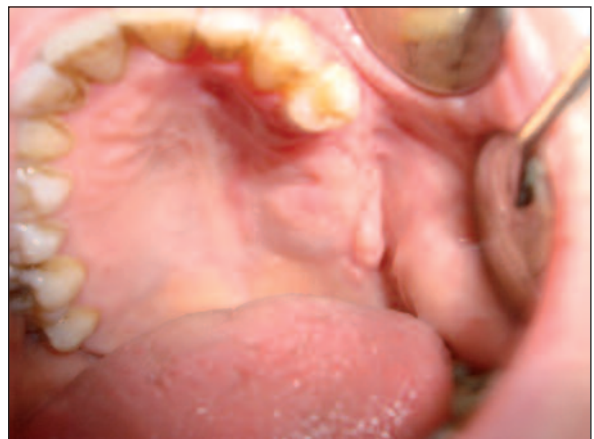

FIGURE 11: Postoperative appearance after six months.

The lateral window technique is the most preferred method for the sinus lifting procedure and the graft material is placed through the prepared bony fenestration between the oral cavity and the sinus.⁴⁻⁶ When the graft material is infected, mostly, oroantral fistula formation is occurred at the level of the prepared lateral window.¹⁵ Under these conditions, bony fenestration prepared to graft the sinus can be used for the removal of the debridement. In this instance, the lack of lateral window prepared to graft the sinus was complicated the treatment.

Lateral wall approach is preferred more than the FESS, because access to infected graft material in the floor of the maxillary sinus is more difficult with a rigid endoscope and angled curettes.¹⁵ Although, complete removal of the infected graft is very important, only the clearance of the maxillary

sinus is not enough for the ideal healing. The correction of the physiological air circulation and drainage of the maxillary sinus must be provided with the complete removal of the infected graft material.¹³ For this purpose, it is beneficial to perform the functional endoscopic sinus surgery in conjunction with the intraoral approach.

After the correction of the ostium and the removal of the infected debris from the sinus, closure of the oroantral fistula is another challenging problem. There are lots of methods described for the treatment of the oroantral fistula and the most preferred one is the simple vestibular mucosal flap technique.^{16,17} Although, simple vestibular mucosal flap technique is easy to perform, it may result in a very shallow vestibular sulcus. And also, periosteal releasing incision to improve the mobility of the flap, decreases the vascular supply of the flap.¹⁸ In this case, because the infected flap margins adjacent to the fistula were removed, the vestibular mucosal flap wouldn't provide sufficient soft tissue volume for the closure of the fistula. On the other hand, rotated palatal island flaps, preserving the descending palatine artery, provide adequate closure of oroantral fistulas. They do not result in a shallow vestibular sulcus as much as simple vestibular mucosal flaps and also they have good vascular supply.¹⁹

In today's dentistry, treatment of this kind of patients must include the bony reconstruction for the further prosthodontic therapy. For this purpose, autogenous bone grafting and oroantral fis-

tula closure can be performed at the same time. By this way, total healing period can be reduced.^{20,21} It is controversial to graft highly infected area in order to reduce the total rehabilitation time, but it does not only reduce total rehabilitation time, but also eliminates the need for another surgery for bony reconstruction. On the other hand, autogenous bone grafting does not increase the incidence of the recurrence of infection or the failure of oroantral fistula closure.

CONCLUSION

Although, the complication rate of sinus lifting procedure is low, its popularity causes many complications to encounter. To reduce the incidence of complications, it should be noted that the sinus lifting procedure is a delicate process. In this case report, treatment of complicated maxillary sinusitis by the combination of functional endoscopic sinus surgery and intraoral approach was presented. Maybe in the future, the technical difficulties of the functional endoscopic sinus surgery can be reduced by appropriately designed instruments and FESS would be sufficient for the treatment of these cases alone. But today, it is beneficial to perform functional endoscopic sinus surgery in combination with intraoral approach. On the other hand, closure of the oroantral fistula is another important step of the treatment and the further prosthodontic rehabilitation must be taken into consideration.

REFERENCES

1. Tatum H Jr. Maxillary and sinus implant reconstructions. *Dent Clin North Am* 1986; 30(2):207-29.
2. Doud Galli SK, Lebowitz RA, Giacchi RJ, Glickman R, Jacobs JB. Chronic sinusitis complicating sinus lift surgery. *Am J Rhinol* 2001;15(3):181-6.
3. Block MS, Kent JN. Maxillary sinus grafting for totally and partially edentulous patients. *J Am Dent Assoc* 1993;124(5):139-43.
4. Barone A, Santini S, Sbordone L, Crespi R, Covani U. A clinical study of the outcomes and complications associated with maxillary sinus augmentation. *Int J Oral Maxillofac Implants* 2006;21(1):81-5.
5. Maksoud MA. Complications after maxillary sinus augmentation: a case report. *Implant Dent* 2001;10(3):168-71.
6. Schwartz-Arad D, Herzberg R, Dolev E. The prevalence of surgical complications of the sinus graft procedure and their impact on implant survival. *J Periodontol* 2004;75(4):511-6.
7. Flanagan D. Arterial supply of maxillary sinus and potential for bleeding complication during lateral approach sinus elevation. *Implant Dent* 2005;14(4):336-8.
8. Ardekian L, Oved-Peleg E, Mactei EE, Peled M. The clinical significance of sinus membrane perforation during augmentation of the maxillary sinus. *J Oral Maxillofac Surg* 2006;64(2):277-82.
9. Proussaefs P, Lozada J, Kim J, Rohrer MD. Repair of the perforated sinus membrane with a resorbable collagen membrane: a human study. *Int J Oral Maxillofac Implants* 2004; 19(3):413-20.

10. Becker ST, Terheyden H, Steinriede A, Behrens E, Springer I, Wiltfang J. Prospective observation of 41 perforations of the Schneiderian membrane during sinus floor elevation. *Clin Oral Implants Res* 2008;19(12):1285-9.
11. Ward BB, Terrell JE, Collins JK. Methicillin-resistant *Staphylococcus aureus* sinusitis associated with sinus lift bone grafting and dental implants: a case report. *J Oral Maxillofac Surg* 2008;66(2):231-4.
12. Cohen NA, Kennedy DW. Revision endoscopic sinus surgery. *Otolaryngol Clin North Am* 2006;39(3):417-35, vii.
13. Felisati G, Borloni R, Maccari A, Mele V, Chiapasco M. Endoscopic removal of alloplastic sinus graft material via a wide middle antrotomy. *Int J Oral Maxillofac Surg* 2008;37(9):858-61.
14. Timmenga NM, Raghoobar GM, van Weissenbruch R, Vissink A. Maxillary sinusitis after augmentation of the maxillary sinus floor: a report of 2 cases. *J Oral Maxillofac Surg* 2001;59(2):200-4.
15. Anavi Y, Allon DM, Avishai G, Calderon S. Complications of maxillary sinus augmentations in a selective series of patients. *Oral Surg Oral Med Oral Pathol Endod* 2008;106(1):34-8.
16. Altuğ HA, Okçu KM, Doğan N, Şençimen M, Şahin S. [Closure of oro-maxillary sinus communications: a study of clinical and treatment aspects]. *Türkiye Klinikleri J Dental Sci* 2009;15(1):18-22.
17. Yih WY, Merrill RG, Howerton DW. Secondary closure of oroantral and oronasal fistulas: a modification of existing techniques. *J Oral Maxillofac Surg* 1988;46(5):357-64.
18. von Wowern N. Closure of oroantral fistula with buccal flap: Rehrmann versus Móczár. *Int J Oral Surg* 1982;11(3):156-65.
19. Anavi Y, Gal G, Silfen R, Calderon S. Palatal rotation-advancement flap for delayed repair of oroantral fistula: a retrospective evaluation of 63 cases. *Oral Surg Oral Med Oral Pathol Oral Radiol Endod* 2003;96(5):527-34.
20. Lee BK. One-stage operation of large oroantral fistula closure, sinus lifting, and autogenous bone grafting for dental implant installation. *Oral Surg Oral Med Oral Pathol Oral Radiol Endod* 2008;105(6):707-13.
21. Sakka S, Krenkel C. Simultaneous maxillary sinus lifting and implant placement with autogenous parietal bone graft: outcome of 17 cases. *J Craniomaxillofac Surg* 2011;39(3):187-91.