

Cerebral Amyloid Angiopathy: Report of Two Cases

Serebral Amiloid Anjiyopati: İki Olgu Sunumu

Emel Ebru PALA,^a
Ümit BAYOL,^a
Özlem TÜRELİK,^a
Ülkü KÜÇÜK,^a
Erdinç ALTINCIK,^b
Nail ÖZDEMİR^b

Clinics of
^aPathology,
^bNeurosurgery,
Tepecik Training and Research Hospital,
İzmir

Geliş Tarihi/Received: 15.12.2011
Kabul Tarihi/Accepted: 08.03.2012

*This case report was presented as a poster at
23rd European Congress of Pathology,
27 August-1 September, 2011,
Helsinki, Finland.*

Yazışma Adresi/Correspondence:
Emel Ebru PALA
Tepecik Training and Research Hospital,
Clinic of Pathology, İzmir,
TÜRKİYE/TURKEY
emelozkok@yahoo.com

ABSTRACT Cerebral amyloid angiopathy (CAA) is characterized by amyloid beta-peptide deposition in the media, adventitia of leptomeningeal, cortical, subcortical arteries and arterioles. No significant associations have been shown between CAA and other systemic/visceral amyloidoses or vascular risk factors, including hypertension. It is generally seen in elderly or demented patients. The amyloid in the vessel lead to fibrinoid necrosis, microaneurysms, cerebral infarction, intracerebral hematomas. Here we report two cases who presented with intracerebral hemorrhage. The histopathologic examination of the tissue obtained during hematoma evacuation demonstrated eosinophilic homogeneous material accumulation in the walls of the leptomeningeal and cortical arterioles. The deposits which stained pink-red by Congo Red showed yellow-green birefringence by the polarizing microscope. In addition, vessels also showed fibrinoid necrosis. Both of the cases were diagnosed as severe grade of CAA. During the hematoma evacuation, a small parenchymal tissue is needed for determining the etiology of the hemorrhage including CAA.

Key Words: Amyloid angiopathy; cerebral hemorrhage; surgery

ÖZET Serebral amiloid anjiyopati (SAA); leptomeningeal, kortikal, subkortikal arter ve arteriollerin media ve adventisyta tabakasında amiloid beta peptid birikimi ile karakterizedir. SAA ile diğer sistemik/viseral amiloidozlar, hipertansiyon gibi vasküler risk faktörleri arasında ilişki gösterilememiştir. Genelde ileri yaş veya demans olgularında görülür. Amiloid birikimi damar duvarında fibrinoid nekroz, mikroanevrizma, serebral infarkt veya intraserebral hematoma yol açar. Biz kliniğe intraserebral hemoraji ile yansıyan iki olguyu sunduk. Hematom boşaltılması esnasında elde edilen materyalin histopatolojik incelemesinde leptomeningeal ve kortikal arteriol duvarında homojen eosinofilik materyal birikimi dikkati çekti. Bu birikimlerin Kongo-kırmızısı ile pembe-kırmızı boyandığı ve polarize mikroskopta yeşil refle verdiği izlendi. Ayrıca damar duvarlarında fibrinoid nekroz görüldü. Her iki olgu da derecesi şiddetli SAA tanısı aldı. İntraserebral hemorajilerde SAA etiolojisini ortaya koymak için hematoma boşaltılırken küçük bir parankim örnekleme gerekmektedir.

Anahtar Kelimeler: Amiloid anjiyopati; serebral hemoraji; cerrahi

Türkiye Klinikleri J Neur 2012;7(2):65-8

Cerebral amyloid angiopathy (CAA) is an important and common cause of spontaneous lobar hemorrhage in elderly and/or demented patients which goes undiagnosed in the absence of histological examination of the blood vessels in the clot. The patients are presented with stroke due to the intracerebral bleeding or cognitive impairment consequent to chronic ischemia. Amyloid deposition in neocortical regions is a hallmark feature of Alzheimer disease (AD).¹ Caselli et al. confirmed that

nondemented APOE ϵ 4 carriers have much more cerebral amyloid pathology than noncarriers supporting the possibility that even in the absence of clinical impairment, neocortical and vascular amyloid represent an early step in AD pathogenesis.² Clinical features and MRI findings are helpful for the diagnosis of probable CAA with leukoencephalopathy and superficial siderosis.³ According to the Boston criteria probable diagnosis is made in elderly patients, with at least two acute or chronic lobar hemorrhagic lesions without any other cause of intracerebral hemorrhage like prior trauma, ischemic stroke, central nervous system tumor, vascular malformation or bleeding diathesis.⁴

CASE REPORTS

CASE 1

A 74-year-old woman admitted to the emergency with sudden loss of consciousness. Her medical history did not reveal any risk factors for intracerebral hemorrhage (ICH) such as systemic hypertension, trauma and there was no history of cognitive impairment. Five years ago she was also hospitalized because of intracranial hemorrhage and got only conservative treatment. Blood pressure was 160/100 and was noted to have right sided hemiplegia. Cranial computed tomography revealed 6x4,5 cm hematoma in the temporoparietal region with midline shift and surrounding edema (Figure 1). Routine blood including coagulation were normal. She underwent emergent parietooccipital craniotomy and subdural, intraparenchymal hematoma was evacuated. The histopathologic examination of hematoma demonstrated the vascular thickening resulted from eosinophilic homogeneous material accumulation in the walls of the leptomeningeal arterioles (Figure 2). The superficial cortical parenchymal arterioles similarly showed round and thickened vascular contours. The deposits which stained pink-red by congo-red (Figure 3, 4) showed yellow-green birefringence when observed by polarizing microscope (Figure 5). There was a severe degree of vascular amyloid changes, characterized by extensive amyloid deposits, vessel wall fragmentation, fibrinoid necrosis (Figure 6).

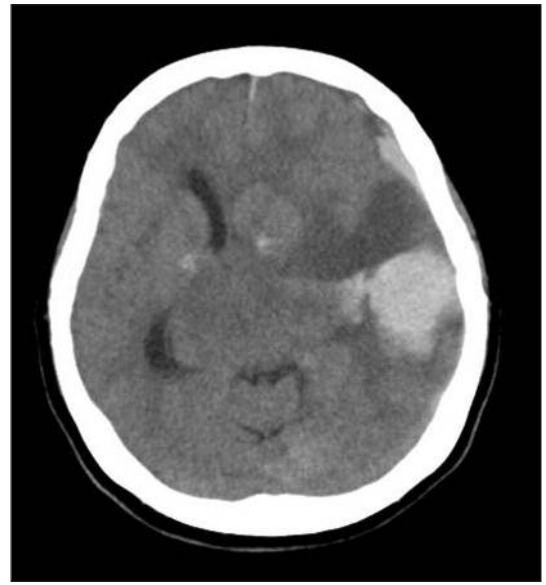

FIGURE 1: CT scan revealed 6x4,5 cm temporoparietal hematoma with midline shift.

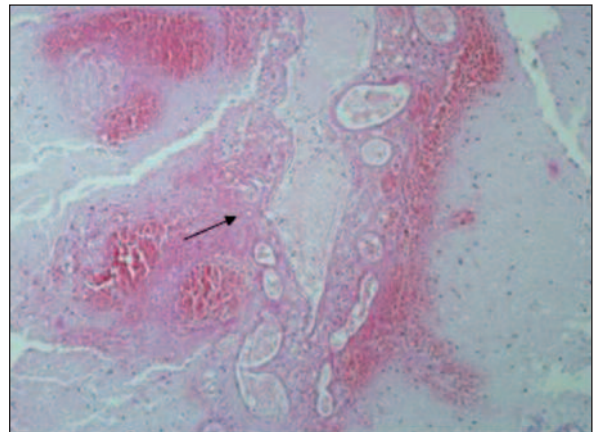


FIGURE 2: Thickened leptomeningeal vessels embedded in a pool of hemorrhage (HE, x10).

CASE 2

A 73-year-old woman presented with impaired orientation. Her spontaneous speech was sparse and not fluent. Her medical history did not reveal any risk factors for ICH. There was no motor deficit. Cranial CT scan showed 4x4 cm hematoma in the left frontal lobe, periventricular multiple chronic lacunar infarction and ischemic signal alterations, atrophic cerebral and cerebellar hemispheres. She underwent emergent left frontal craniotomy and hematoma evacuation. On the first postoperative day, clinical picture was improved. Evacuated

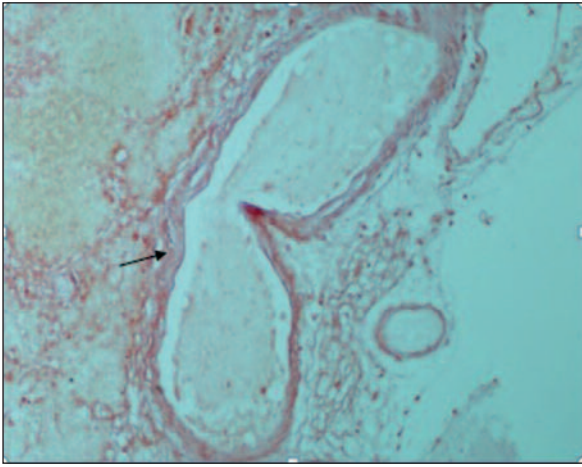


FIGURE 3: Amorphous eosinophilic deposits are congophilic (Congo-red, x10).

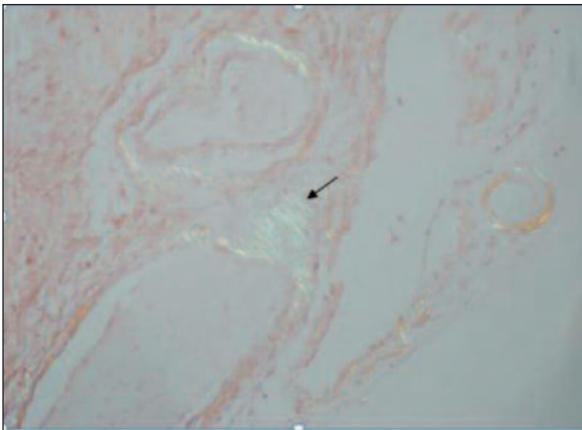


FIGURE 4: The deposits are birefringent under polarized light (Congo-red, x10).

hematomas showed blood clots and few hemorrhagic cortical fragments. There was eosinophilic homogeneous material accumulation in the walls of the leptomenigeal and cortical arterioles which was congophilic and birefringent.

DISCUSSION

Amyloid deposition restricted to the central nervous system, which was first described by Gustav Oppenheim in 1909, is a frequent form of localized amyloidosis.⁵ Its prevalence is strongly associated with increasing age and has been reported to be as high as 57% percent in case series of asymptomatic patients over 60 years of age with or without dementia. CAA occurs mostly sporadic condition and

all of the sporadic cases are due to deposition of amyloid β -peptide ($A\beta$), derived from Amyloid Precursor Protein. The ApoE $\epsilon 4$ ve $\epsilon 2$ alleles are genetic risk factors associated with sporadic $A\beta$ CAA.⁶ Hereditary forms are generally familial, more severe and earlier in onset.⁷ Vonsattel et al. graded CAA with respect to the severity of pathological changes in a blood vessel: mild, amyloid is restricted to the tunica media without significant destruction of smooth muscle cells; moderate, tunica media is replaced by amyloid and is thicker than normal; severe, extensive amyloid deposition

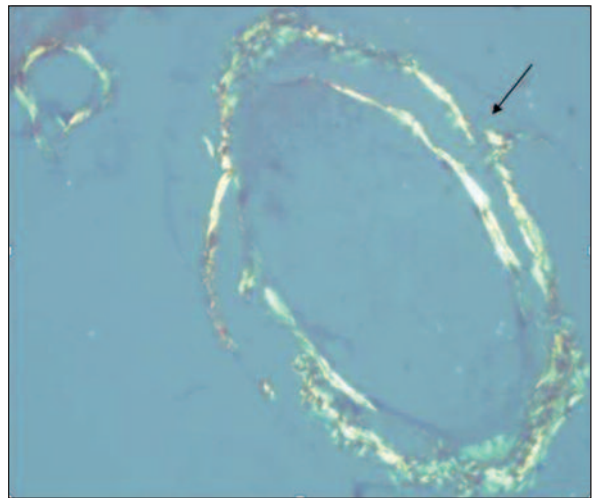


FIGURE 5: Double barreling of the vessel is striking under polarized light (Congo-red, x40).

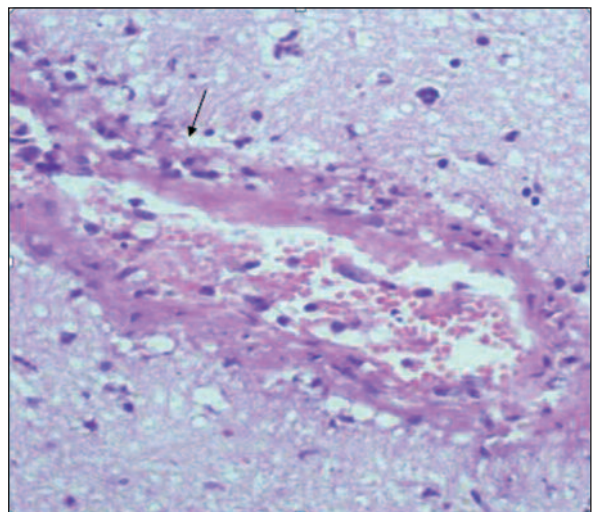


FIGURE 6: Fragmentation of the media, fibrin deposition, luminal narrowing (HE, x40).

with focal wall fragmentation or microaneurysm formation, fibrinoid necrosis and leakage of blood through the blood vessel wall.⁸ Amyloid deposition can weaken cerebral vessel walls, causing rupture leading to asymptomatic microbleeds and lobar ICH or obliterate the vessel lumen leading to ischemia and infarction. Treatment or preventive strategy for CAA doesn't exist at this time. Corticosteroid and other immunosuppressant treatments can ameliorate the symptoms associated with inflammation.⁹ Recent reported results suggest that

controlling blood pressure is likely to reduce risk of CAA-ICH recurrence.¹⁰ Further researches are required to identify therapeutic targets and take caution. Spontaneous intracerebral hemorrhage, defined as hemorrhage in the brain parenchyma in the absence of trauma or surgery accounts for 8 to 15% of all strokes.¹¹ Common causes include hypertension, amyloid angiopathy, coagulopathy, vascular anomalies. Examination of cortical tissue obtained surgically is an important tool for the diagnosis of CAA during life.

REFERENCES

1. Price JL, Morris JC. Tangles and plaques in nondemented aging and "preclinical" Alzheimer's disease. *Ann Neurol* 1999;45(3):358-68.
2. Caselli RJ, Walker D, Sue L, Sabbagh M, Beach T. Amyloid load in nondemented brains correlates with APOE e4. *Neurosci Lett* 2010;473(3):168-71.
3. Feldman HH, Maia LF, Mackenzie IR, Forster BB, Martzke J, Woolfenden A. Superficial siderosis: a potential diagnostic marker of cerebral amyloid angiopathy in Alzheimer disease. *Stroke* 2008;39(10):2894-7.
4. Knudsen KA, Rosand J, Karluk D, Greenberg SM. Clinical diagnosis of cerebral amyloid angiopathy: validation of the Boston criteria. *Neurology* 2001;56(4):537-9.
5. Oppenheim G. [About the cerebral cortex 'glandular necrosis']. *Neurol Centralbl* 1909;28:410-3.
6. Sudlow C, Martínez González NA, Kim J, Clark C. Does apolipoprotein E genotype influence the risk of ischemic stroke, intracerebral hemorrhage, or subarachnoid hemorrhage? Systematic review and meta-analyses of 31 studies among 5961 cases and 17,965 controls. *Stroke* 2006;37(2):364-70.
7. Palsdottir A, Snorraddottir AO, Thorsteinsson L. Hereditary cystatin C amyloid angiopathy: genetic, clinical, and pathological aspects. *Brain Pathol* 2006;16(1):55-9.
8. Vonsattel JP, Myers RH, Hedley-Whyte ET, Ropper AH, Bird ED, Richardson EP Jr. Cerebral amyloid angiopathy without and with cerebral hemorrhages: a comparative histological study. *Ann Neurol* 1991;30(5):637-49.
9. Kloppenborg RP, Richard E, Sprengers ME, Troost D, Eikelenboom P, Nederkoorn PJ. Steroid responsive encephalopathy in cerebral amyloid angiopathy: a case report and review of evidence for immunosuppressive treatment. *J Neuroinflammation* 2010;7:18.
10. Arima H, Tzourio C, Anderson C, Woodward M, Bousser MG, MacMahon S, et al.; PROGRESS Collaborative Group. Effects of perindopril-based lowering of blood pressure on intracerebral hemorrhage related to amyloid angiopathy: the PROGRESS trial. *Stroke* 2010;41(2):394-6.
11. Kadioglu HH, Aydın IH. [Spontaneous intracerebral hemorrhage in adults]. *Turkiye Klinikleri J Surg Med Sci* 2006;2(16):104-9.