

A Case Report of Extreme Hypercalcemia without Classical Manifestations

Klinik Bulguları Olmayan Bir Aşırı Hiperkalsemi Olgusu

Abidin ÖZTÜRK, MD,^a
Gül GÜR SOY, MD,^a
Onur EŞBAH, MD,^a
Yaşar ACAR, MD,^a
Berrin DEMİRBAŞ, MD^a

^aClinic of Internal Medicine,
Ankara Education and
Research Hospital, Ankara

Geliş Tarihi/Received: 13.07.2010
Kabul Tarihi/Accepted: 10.12.2010

Yazışma Adresi/Correspondence:
Gül GÜR SOY, MD
Ankara Education and
Research Hospital,
Clinic of Internal Medicine, Ankara,
TÜRKİYE/TURKEY
gulgursoyyener@yahoo.com

ABSTRACT Primary hyperparathyroidism is a hypercalcemic disorder that results from excessive secretion of parathyroid hormone. It is caused by a single parathyroid adenoma in about 80% of cases and by primary hyperplasia of parathyroids in about 15%. Parathyroid carcinoma is a rare cause of hyperparathyroidism, accounting for 1-2 % of cases. Herein, we reported a case of 63 year old woman who had extreme hypercalcemia associated with a parathyroid adenoma. The patient presented with typical symptoms of hypercalcemia but there were no classical manifestations of hyperparathyroidism in spite of very high serum calcium levels. Serum calcium and parathyroid hormone levels were 20 mg/dl and 423 pg/ml respectively. Firstly the calcium level was decreased and then she underwent surgery. The hypercalcemic crisis of hyperparathyroidism could occasionally result in catastrophic illness and even death. It was important to recognize and appropriately manage this endocrine emergency.

Key Words: Hypercalcemia; parathyroid neoplasms; hyperparathyroidism, primary

ÖZET Primer hiperparatiroidizm, aşırı paratiroid hormon sentezi ile oluşan bir hiperkalsemik hastalıktır. %80 vakada tek bir paratiroid adenoma, %15 vakada paratiroidlerin primer hiperplazisi sonucu meydana gelir. Paratiroid karsinoma vakaların %1-2'sinden sorumlu olan nadir bir nedendir. Bu yazıda, paratiroid adenomuna bağlı aşırı hiperkalsemisi olan 63 yaşında bir kadın hastayı sunduk. Çok yüksek kalsiyum seviyelerine rağmen hasta klasik hiperparatiroidizm bulguları olmadan, tipik hiperkalsemi semptomları ile müracaat etmişti. Serum kalsiyum ve paratiroid hormon seviyeleri sırasıyla 20 mg/dl ve 423 pg/ml idi. Önce hastanın kalsiyum seviyeleri düşürüldü, sonra cerrahi müdahale uygulandı. Hiperparatiroidizme bağlı hiperkalsemik kriz sıklıkla katastrofik hastalık, hatta ölümlerle sonuçlanır. Bu endokrin acili tanımak ve uygun tedavi etmek önemlidir.

Anahtar Kelimeler: Hiperkalsemi; paratiroid tümörleri; hiperparatiroidi, primer

Türkiye Klinikleri J Endocrin 2011;6(1):37-40

Hypercalcaemic crisis is characterised by severe hypercalcemia, usually with a calcium >13 mg/dl. It is a life-threatening endocrine emergency.¹ Clinical features include renal lithiasis, neuromuscular asthenia or psychiatric disorders, gastrointestinal and cardiovascular manifestations and osteopenia or osteoporosis. Hypercalcaemic crisis is first described by Hanes in 1939, the prevalence of it changes from 1% to 2% of patients with hyperparathyroidism.²⁻⁴ The mortality rate of hypercalcaemic crisis was 60%. It is supposed to be decreased after new treatment options.

CASE REPORT

A 63 year old woman was admitted to our department following a 2-day history of nausea, vomiting, severe abdominal pain and constipation. Physical examination on admission showed the patient was dehydrated. She had a tenderness on epigastric region. Her medical history was unremarkable, she did not have any chronic illness. There was no family history of any illness. The radiographs of the abdomen and urinary system were normal. Biochemical assays revealed extreme hypercalcemia 20 mg/dL (8.8-10.6), confirmed by repeated measurement. Serum creatinine and urea levels of 1.7 mg/dL (0.8-1.4) and 60 mg/dL (17-43) respectively, indicated a prerenal azotemia. Blood tests showed hypophosphatemia (1.9 mg/dL, Normal: 2.5-4.5), hypokalemia (2.9 mmol/L, Normal: 3.5-5.0) and alkaline phosphatase elevation (153 U/L, Normal: 30-120). The patient was transferred to the intensive care unit for urgent treatment. Electrocardiography showed normal sinus rhythm with normal QT intervals. To decrease the calcium concentration the patient received intravenous saline, high doses loop diuretics and pamidronate. In the first day 0.9 % saline was given 500 ml/hour and continued with 250 ml/ hour on the other days. Intravenous furosemide was administered 40 mg every 2 hours in the first 2 days, later 4 x 40 mg on proceeding days. In the first two days pamidronate 90 mg was infused over 4 hours. The response to medical treatment was successful and the serum calcium level reduced progressively. On the fourth day of the treatment she presented with acute confusion, disorientation in time and place. Serum calcium level was 13 mg/dL. Cerebral computerised tomography showed no pathological findings. Treatment was continued and in 24 hours her neurological findings resolved. Her intact parathyroid hormone (PTH) concentration was markedly raised at 423 pg/mL (Normal: 15-88). Serum 25-OH-vitamin D3 and 1-25(OH) vitamin D were normal. Bone roentgenograms and a bone scan were normal. There was no pathological finding in urinary system ultrasonography. Ultrasonography and MIBI scintigraphy identified a 16 x 7 mm lesion on the in-

ferior pole of the left thyroid lobe, consistent with a parathyroid adenoma and the thyroid lobe was heterogeneous. The patient underwent parathyroidectomy on day 11. The intraoperative findings confirmed the diagnosis of 25 x 15 x 7 mm adenoma of the left inferior parathyroid gland and it was removed. The remaining parathyroid glands were found normal in size and left untouched. The histopathological examinations revealed a parathyroid adenoma and no evidence of malignancy. Serum calcium and the PTH levels normalized and the patient was free of symptoms within a day after surgery. In spite of the elevated preoperative serum alkaline phosphatase levels hungry bones disease did not follow parathyroidectomy. After dual energy x-ray absorptiometry was performed, osteopenia was diagnosed in lumbar spine and hip of the patient. The patient was discharged well one week after surgery. One month later the control serum calcium and intact parathyroid hormone was 8.9 mg/dL and 48 pg/mL, respectively.

Serum Ca levels of the patient was presented in Figure 1.

DISCUSSION

The hypercalcaemic crisis of hyperparathyroidism is an endocrine emergency that can be mortal if untreated. Primary hyperparathyroidism and malignancy account for more than 90 percent of hypercalcaemic crisis. In many patients primary hyperparathyroidism progress very slowly and there are complications of the illness when diagnosed. But in our patient there was no evidence of complications like renal insufficiency brown tumours, proximal muscle weakness or neuropsychi-

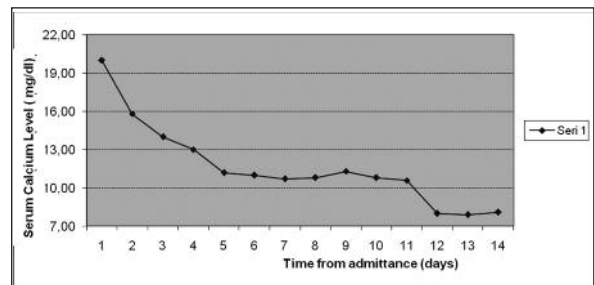


FIGURE 1: Serum calcium levels of the patient.

atric syndrome. Except slight renal dysfunction caused by dehydration no other organ involvement was found, suggesting a relatively quick development of hypercalcemic crisis. In our patient hypercalcaemic crisis was the first manifestation of primary hyperparathyroidism.

Patients with calcium levels greater than 13 mg/dl or symptomatic patients with calcium levels greater 12 mg per dl should be immediately and aggressively treated.⁵ Patients are volume depleted and the mainstay of management is aggressive intravenous rehydration. Normal saline should be used to achieve a urine output of 200 ml/h. Diuresis induced by furosemide increases renal excretion of sodium and calcium.

In many cases such a regimen may not be successful. Especially in cases of humoral hypercalcemia of malignancy the administration of biphosphonates can be considered. Biphosphonates which directly inhibit osteoclast activity, are the most effective of the pharmacological agents that decrease bone resorption. Pamidronate can be given 60 to 90 mg by four hour infusion. But the peak effects of these drugs do not occur until 48 to 72 hours after infusion. Zoledronic acid is also popular nowadays (4 mg iv over 15 minutes). It is a third generation biphosphonate, and is 100-800 times more effective than pamidronate and it reduces Ca levels more rapidly and its effect lasts longer. Zoledronic acid is also very effective in malignancy related hypercalcemia. Calcitonin inhibits bone resorption and augments Ca excretion. It can be given 4 to 8 µg/kg im every 6 hours for 24 hours. Cinacalcet is a calcimimetic agent that binds to sites of the parathyroid glands' extracellular calcium sensing receptor to increase their affinity for extracellular calcium, thereby decreasing PTH secretion. It may be administered orally in oral doses of 30-250 mg twice daily.

Glucocorticoids exert a calcium-lowering effect by reducing calcium absorption. They are indicated only for rare hypercalcemias such as ingestion of large amounts of vitamin D or its analogs.

Another therapeutic consideration in resistant cases is emergency dialysis. Dialysis, using a

solution containing less calcium is very effective in temporarily reducing the levels of serum calcium to safe levels. In cases of primary hyperparathyroidism with hypercalcemic crisis, urgent parathyroidectomy is potentially curative. As for all patients with primary hyperparathyroidism, approximately 85-90% of patients with parathyroid crisis have a single adenoma.⁶ However hyperparathyroidism also can result from hyperplasia of the parathyroid glands or rarely parathyroid carcinoma. Prompt parathyroidectomies may be life-saving in patients with parathyroid adenomas.^{4,7} The mortality rate in untreated patients is 100%. Mortality rates as high as 60% are associated with patients treated by combinations of medical and surgical protocols. Risks of parathyroid surgery include permanent hypoparathyroidism and damage to the recurrent laryngeal nerve. Parathyroidectomy performed by an experienced surgeon usually has a low complication rate (2.3%) and results in prompt recovery. The cure rate is reported as being as high as 98%.⁸

In primary hiperparathyroidism serum Ca level is usually under 13 mg/dl. In our patient we could not find any other predisposing factor for so high Ca levels, such as immobilisation, high Ca diet, medications with Ca, multiple myeloma or severe hypovolemia. We think that in our patient, parathyroid cancer must also be considered with primary hiperparathyroidism. Although the pathological diagnose was benign, we planned to follow up the patient regarding recurrence or metastasis.

Our patient did not exhibit cardiac manifestations or severe impairments of nervous system functions in spite of very high levels of hypercalcemia. We may explain this event by relatively slowly developing hypercalcemia, instead of rapidly developing one.

Mental status of our patient got worse in the fourth day of the successful treatment, as serum Ca levels were considered. We can hardly explain this event. We doubt that if we can make the speculation that rapidly lowering of serum Ca levels from very high levels may cause the same findings in central nervous system like hypocalcemia.

In conclusion, despite all advances in this field, hypercalcemic crisis is a life-threatening condition, especially in patients with extremely high serum calcium levels. Our case shows the importance of diagnosing hypercalcemia in acutely ill patients with nonspecific symptoms.

Patients can present with a wide range of symptoms related to metabolic derangements of multiple organ systems. The treatment is based on hydration, diuresis, pharmacologic agents, dialysis and surgery. Early diagnosis and treatment will be life-saving.

REFERENCES

1. Rodgers SE, Lew JI, Solórzano CC. Primary hyperparathyroidism. *Curr Opin Oncol* 2008;20(1):52-8.
2. Hanes FM . Hyperparathyroidism due to parathyroid adenoma with death from parathormone intoxication. *Am J Med Sci* 1939;197(3):85-90.
3. Aktaran Ş, Akarsu E. [Prolonged elevation of parathyroid hormone in normocalcemic patient after parathyroidectomy for primary hyperparathyroidism: association with vitamin D: case report]. *Türkiye Klinikleri J Med Sci* 2008;28(4):580-3.
4. Korukluoğlu B, Kıyak G, Çelik A, Uçar AE, Ergül E, Kuşdemir A. [Our surgical approach to parathyroid adenoma and the role of localization studies]. *Türkiye Klinikleri J Med Sci* 2008;28(1):24-9.
5. Ziegler R. Hypercalcemic crisis. *J Am Soc Nephrol* 2001;12(17):3-9.
6. Fitzpatrick LA, Bilezikian JP. Acute primary hyperparathyroidism. *Am J Med* 1987;82(2): 275-82.
7. Asagoe T, Takami H, Hanatani Y, Kodaira S. [Parathyroid crisis]. *Nippon Rinsho* 1995; 53(4):925-9.
8. Udelsman R. Six hundred fifty-six consecutive explorations for primary hyperparathyroidism. *Ann Surg* 2002;235(5):665-70.