

Beta Blocker Induced Parapsoriasis: Case Report

Beta Blokerin Uyardığı Parapsöriazis

Rifat Eralp ULUSOY,^a
Hande ULUSAL^b

Clinics of
^aCardiology,
^bDermatology,
Memorial Special Hizmet Hospital,
İstanbul

Geliş Tarihi/Received: 19.10.2013
Kabul Tarihi/Accepted: 28.03.2014

Yazışma Adresi/Correspondence:
Rifat Eralp ULUSOY
Memorial Special Hizmet Hospital,
Clinic of Cardiology, İstanbul,
TÜRKİYE/TURKEY
eralpulusoy@hotmail.com

ABSTRACT A 44-year-old female presented to our dermatology clinic with reddish eruptions located on both of her thighs as well as on the interscapular and subscapular areas. She was prescribed metoprolol to treat her hypertension and she was on metoprolol for 10 months. Cardiologic evaluation revealed mild aortic and mitral regurgitation with controlled hypertension. After consulting with the dermatologist, she had a skin biopsy delineating the diagnosis of parapsoriasis induced by metoprolol. Metoprolol therapy has switched to calcium channel blocker therapy with topical steroid treatment finally healed the whole skin lesions. After three months, still there is no recurrence in terms of parapsoriatic lesion.

Key Words: Parapsoriasis; adverse effects; adrenergic beta-antagonists

ÖZET Kırkdört yaşında kadın hasta her iki uyluk, interskapular ve subskapular alanlarda ortaya çıkan kırmızı döküntülerin değerlendirilmesi için kliniğimize başvurdu. Hipertansiyon nedeni ile metoprolol reçetelenmiş olup bunu 10 aydır kullanmaktaydı. Kardiyolojik bulguları hafif aort ve mitral yetmezliği ile kontrollü hipertansiyon olarak saptandı. Dermatoloji uzmanı ile konsültasyon sonrası yapılan cilt biyopsisi sonucu metoprolol ile uyarılmış parapsöriazis tanısı konuldu. Metoprolol tedavisinin kalsiyum kanal blokleri ve topikal steroid kullanımına çevrilmesi sonucu bütün cilt lezyonları kayboldu. Üç ay sonra halen parapsöriatik lezyon rekürrensi saptanmamıştır.

Anahtar Kelimeler: Parapsöriazis; istenmeyen etkiler; adrenerjik beta-antagonistler

Türkiye Klinikleri J Case Rep 2015;23(2):173-5

Parapsoriasis describes a group of cutaneous diseases that can be characterized by scaly patches or slightly elevated papules and/or plaques that have a resemblance to psoriasis.^{1,2}

Beta blockers are pharmacologic agents commonly and extensively used to treat many clinical conditions such as essential hypertension, coronary artery disease, supraventricular and ventricular tachycardia, migraine and heart failure. Adverse effects directly related to beta blocker therapy rarely threaten life and respond well to discontinuation of drug therapy, has been previously reported as 10% of the cases.^{3,4} We aimed to present a case of new onset parapsoriasis induced by small dose beta blocker (Metoprolol 25 mg/day) therapy in an otherwise cardiovascular healthy female.

doi: 10.5336/caserep.2013-37889

Copyright © 2015 by Türkiye Klinikleri

CASE REPORT

A 44-year-old-female was admitted to our clinic with the diagnosis of chronic hypertension. She was prescribed 25 mg metoprolol 10 months ago. Her past medical history is unremarkable for any surgical or cardiologic intervention except hypothyroidism for 4 years. She is currently on Levothyroxine medication. There was no personal or family history of allergies, anaphylaxis, or atopic diathesis. Her family history is consistent with essential hypertension for her mother and father as well as chronic psoriasis only for her father without any abdominal pathology. She never smoked and used alcohol. Physical examination revealed that she appears to be alert, comfortable, and in no acute distress. She is well oriented to person, time, and place. Her vital signs revealed a heart rate of 77 bpm/regular, a respiratory rate of 18-20 breaths/min. Her body temperature is normal. Her respiratory and cardiovascular examinations revealed 1/6 degree diastolic murmur best heard at the aortic area and 1/6 degree systolic murmur best heard at the mitral area. The abdominal examination revealed any abnormal findings without any masses or organomegaly. Neurologic examination is grossly normal with equal power, tone, and bulk in both upper and lower extremities bilaterally, normal reflexes, and intact cranial nerves. Her mental status examination is normal.

Her skin lesions were located on both of her thighs as well as the back side mostly located at interscapular and subscapular areas, which were red, circular skin lesion with white borders, ranging from 1 to 4 cm wide eruptions (Figure 1a, 1b).

Laboratory investigations; Biochemistry (CBC, Urine analysis, blood chemistry) revealed normal findings. Electrocardiography shows a sinus rhythm with no evidence of ischemic ST-T changes. Transthoracic echocardiography is consistent with mild degree Aortic and mild degree mitral regurgitation, mitral valve myxomatous changes and thickness at the tip of aortic leaflets. Her chief complaints as skin lesions, which had started 10 months after beta blocker therapy,

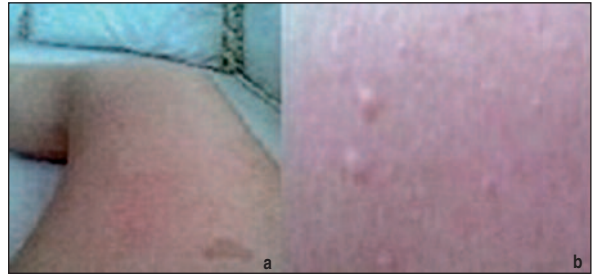


FIGURE 1: a, b) Red, circular parapsoriatic skin lesions with white borders, ranging from 1 to 4 cm wide eruptions.

was consulted with the dermatology department, and after obtaining the skin biopsies which revealed epidermal orthohyperkeratosis, small lymphoid cell group with dark chromatin in the basal layer and in the papillary dermis around the vessels small lymphoid cells in lichenoid pattern, she was finally diagnosed as parapsoriasis yielding a side effect of beta blocker therapy. According to adverse drug reaction probability scaling system, her Naranjo scale is 5. This scale yields a diagnosis of probable beta blocker induced parapsoriasis.

Metoprolol therapy was switched to calcium channel blocker (Diltiazem 30 mg/day) and topical corticosteroid treatment was initiated. In about three weeks' time, all skin lesions were totally healed. Her follow-up in the first three months was free of any recurrences for the skin lesions.

DISCUSSION

The advantages, clinical indications and adverse effects for beta blockers have been studied extensively and took its place in daily cardiology life as well as certain cardiology guidelines.³⁻⁷ The vast majority of its usage is for hypertension, acute or chronic coronary artery disease as well as heart failure and arrhythmias.⁴ The major usage of this drug have brought attention among all the worldwide physicians and besides its usage, physicians also get used to of the beta blocking drugs side effects.⁴ However there are well-known common side effects manifest in the pulmonary, cardiac and neurologic systems, very rarely seen side effects are cutaneous lesions such as psoriasis and parapsoriasis.^{8,9}

A possible pathogenetic mechanism of beta blocker aggravated psoriasis has been previously reported although the parapsoriasis is still unknown.^{3-6,8} The mechanism for the exacerbation of psoriasis with beta blocker use is thought to be related to a blockade in the activation of the messenger system of cyclic adenosine 3',5'-cyclic monophosphate.⁹ This blockade results in reduced intracellular concentrations of calcium and may, in turn, cause an accelerated proliferation of keratinocytes or polymorphonuclear leukocytes, both of which may play a role in inducing or exacerbating psoriasis.⁹ Although the previously reported mechanism for psoriasis is not delineated clearly,

which may diagnosed as a paradoxical phenomenon.^{3,5,6,8-11}

Our case is an atypical presentation of parapsoriasis induced by very low dose of metoprolol, which cardiologists very rarely seen during the daily cardiology clinic life. Withdrawal of beta blocker therapy and switching to calcium channel blocker (Diltiazem in this case) generally results in the soothing and healing of the immunologic reaction as well as provide a continuum for the hypertension therapy. Therefore we suggest switching to another therapy for all patients in whom parapsoriasis has developed or worsened during beta blocker therapy.

REFERENCES

1. Naldi L. Epidemiology of psoriasis. *Curr Drug Targets Inflamm Allergy* 2004;3(2):121-8.
2. Kurd SK, Gelfand JM. The prevalence of previously diagnosed and undiagnosed psoriasis in US adults: results from NHANES 2003-2004. *J Am Acad Dermatol* 2009;60(2):218-24.
3. Tsankov N, Kazandjieva J, Drenovska K. Drugs in exacerbation and provocation of psoriasis. *Clin Dermatol* 1998;16(3):333-51.
4. Frishman W, Silverman R, Strom J, Elkayam U, Sonnenblick E. Clinical pharmacology of the new beta-adrenergic blocking drugs. Part 4. Adverse effects. Choosing a beta-adrenoreceptor blocker. *Am Heart J* 1979;98(2):256-62.
5. Gudjonsson JE, Johnston A, Sigmundsdottir H, Valdimarsson H. Immunopathogenic mechanisms in psoriasis. *Clin Exp Immunol* 2004;135(1):1-8.
6. Tagami H. Triggering factors. *Clin Dermatol* 1997;15(5):677-85.
7. Hunt SA, Abraham WT, Chin MH, Feldman AM, Francis GS, Ganiats TG, et al.; American College of Cardiology Foundation; American Heart Association. 2009 Focused update incorporated into the ACC/AHA 2005 Guidelines for the Diagnosis and Management of Heart Failure in Adults A Report of the American College of Cardiology Foundation/American Heart Association Task Force on Practice Guidelines Developed in Collaboration With the International Society for Heart and Lung Transplantation. *J Am Coll Cardiol* 2009;53(15):e1-e90.
8. Arntzen N, Kavli G, Volden G. Psoriasis provoked by beta-blocking agents. *Acta Derm Venereol* 1984;64(4):346-8.
9. Waqar S, Sarkar PK. Exacerbation of psoriasis with beta-blocker therapy. *CMAJ* 2009;181(1-2):60.
10. Hu CH, Miller AC, Peppercorn R, Farber EM. Generalized pustular psoriasis provoked by propranolol. *Arch Dermatol* 1985;121(10):1326-7.
11. O'Brien M, Koo J. The mechanism of lithium and beta-blocking agents in inducing and exacerbating psoriasis. *J Drugs Dermatol* 2006;5(5):426-32.