

Evaluation of the Effects of Inferior Oblique Muscle Weakening Surgery on Macula by Optical Coherence Tomography

İnferior Oblik Kas Zayıflatma Cerrahisinin Makulaya Etkilerinin Optik Koherens Tomografi ile Değerlendirilmesi

© Mehmet Erkan DOĞAN^a,
© Yaşar DURANOĞLU^a,
© Abdulkadir ALIŞ^b

^aDepartment of Ophthalmology,
Akdeniz University Faculty of Medicine,
Antalya, TURKEY
^bSehit Prof Dr. İlhan Varank Training and
Research Hospital,
İstanbul, TURKEY

Received: 28.11.2018
Received in revised form: 05.01.2019
Accepted: 08.01.2019
Available online: 29.01.2019

Correspondence:
Mehmet Erkan DOĞAN
Akdeniz University Faculty of Medicine,
Department of Ophthalmology, Antalya,
TURKEY/TÜRKİYE
m.erkandogan@gmail.com

ABSTRACT Objective: To evaluate the success of the surgical procedure and investigate the impact of inferior oblique muscle traction on macula. To this end, evaluation of the possible macular changes by optical coherence tomography (OCT) due to disinsertion+distal muscle resection + tucking method used in inferior oblique muscle weakening procedure is planned. **Material and Methods:** 27 eyes of 20 patients who underwent surgery of inferior oblique muscle weakening procedure in the Akdeniz University Faculty of Medicine were included in this prospective study. The success rate of the procedure and complications were analyzed. In all cases, OCT examination was performed preoperatively and also postoperative second day, first week, first month, 3 months later and 6 months later and these results were evaluated. **Results:** 27 eyes of 20 cases were examined. The mean age at the time of presentation was 10.65±5.9 years (range 5-27). 11 (55%) cases had primary inferior oblique muscle overaction and 9 (45%) cases had secondary inferior oblique muscle overaction. Success rate of operation was 77.8%. There were no statistically significant differences between preoperative and postoperative (at the end of 2nd day, 1st week, 1st month, 3rd month and 6th month) macular thickness measurements. **Conclusion:** We have concluded that the inferior oblique muscle disinsertion + distal muscle resection and tucking process is a safe, simple and effective procedure which doesn't cause any morphological damage of the macula in patients with inferior oblique muscle overaction.

Keywords: Oculomotor muscles; optical coherence tomography; macula lutea; fourth cranial nerve palsy; strabismus

ÖZET Amaç: Bu çalışmadaki amacımız alt oblik kas traksiyonunun makula üzerindeki etkisini araştırmak ve uygulanan cerrahi prosedürün başarısını değerlendirmektir. Bu amaçla dezensersiyon + distal kas rezeksiyonu+tucking yöntemiyle uygulanan alt oblik kas zayıflatılması prosedürünün olası makula etkilerinin optik koherens tomografi (OKT) ile değerlendirilmesi planlanmaktadır. **Gereç ve Yöntemler:** Bu prospektif çalışmada Akdeniz Üniversitesi Tıp Fakültesi'nde alt oblik kas zayıflatılması prosedürü uygulanan 20 hastanın 27 gözü çalışmaya dahil edildi. Cerrahi başarı oranı ve komplikasyonlar analiz edildi. Tüm olgularda ameliyat öncesi ve sonrası postoperatif ikinci gün, birinci hafta, birinci ay, 3. ay ve 6. ay OKT incelemesi yapıldı ve bu sonuçlar değerlendirildi. **Bulgular:** 20 olgunun 27 gözü incelendi. İlk muayene sırasındaki yaş ortalaması 10,65±5,9 yıl (5-27) idi. Olguların 11 (%55)'inde primer alt oblik kas hiperfonksiyonu, 9 (%45)'unda sekonder alt oblik kas hiperfonksiyonu vardı. Operasyon başarısı %77,8 idi. Preoperatif ve postoperatif (2. gün, 1. hafta, 1. ay, 3. ay ve 6. ay sonunda) makula kalınlığı ölçümleri arasında istatistiksel olarak anlamlı bir farklılık yoktu. **Sonuç:** Alt oblik kas hiperfonksiyonu olan hastalarda uygulanan alt oblik kas dezensersiyonu + distal kas rezeksiyonu+ tucking prosedürünün güvenli, basit ve etkili bir yöntem olduğu ayrıca makulaya herhangi bir morfolojik zarar vermediği sonucuna varılmıştır.

Anahtar Kelimeler: Okülomotor kaslar; optik koherens tomografi; makula lutea; dördüncü kranial sinir felci; şaşılık

Inferior oblique muscle overaction (IOOA), an eye movement disorder, is characterized by upshoot on adduction which can lead to up-shift at primary position or the contralateral side gaze. Symptoms such as diplopia and asthenopia, and abnormal head position may accompany the

clinical presentation. IOOA, may be primary or secondary.¹ In both states, inferior oblique muscle weakening procedures are applied in the treatment. Surgical correction of IOOA is performed with functional and cosmetic purposes. Amblyopia with lateral gaze causes diplopia and cosmetic problems such as upshot.²

During the inferior oblique muscle weakening operation; separating the muscle and drawing by crochet while bringing the globe in adduction and elevation, cause traction of the globe at the adhesion site. The sticking place of the muscle to the globe shows close proximity to macula. Distance of the muscle insertion's rear boundary from the fovea is 2.5 ± 0.8 mm. The effect of the traction force generated on macula was previously reported by El Massri who had suggested that it may cause retinal tear and macular hole development in elderly or high myopia patients.³

The purpose of this study is to investigate the impact of inferior oblique muscle traction on macula. To this end, evaluation of the possible macular changes by optical coherence tomography (OCT) due to disinsertion + distal muscle resection + tucking method used in inferior oblique muscle weakening procedure is planned.

MATERIAL AND METHODS

Twenty seven eyes of 20 patients, who underwent disinsertion + distal muscle resection + tucking surgery were included in the study at Akdeniz University hospital, Department of Ophthalmology. This prospective study was approved by Akdeniz University Clinical Research Ethics Committee (04.09.2013/107). The potential risks and benefits of the surgical treatment were explained to all patients and/or their parents. Before surgery, informed consents for both the surgery and the research were obtained separately, according to the Helsinki declaration.

Genders and ages of the patients at the examination time were recorded. All patients underwent routine ophthalmologic examination. Visual acuity of the compatible cases was measured by Snellen or Lea symbols. Refractive errors, if deter-

mined, were corrected and recorded. Refraction examinations were performed with and without cycloplegia using autorefractometer or retinoscopy. Anterior segment examination and fundus examination through dilated pupils were performed by direct or indirect ophthalmoscope. Changes in the torsion were followed by evaluating the relationship of optical disc and macula. Muscle functions of the cases were appraised at primary and the other eight gaze positions. Degree of gaze shift was made with prism cover test with far, near and middle distance. In the patients who could not be evaluated because of their ages or bad fixation, approximate gaze shift degree was determined by Krinsky test. IOOA was classified as +1 for 10 degrees, +2 for 20 degrees, +3 for 30 degrees and +4 for 40 degrees according to the elevation excess of the eye. Patients with restrictive strabismus, neurological disease, orbital pathology, cranio-facial anomalies, retinal or macular pathology, inadequate cooperation to optic coherence tomography (OCT), discontinuity to follow-up were excluded from the study. Surgical treatment was applied to the patients with primary and secondary IOOA, binocular vision disorder, abnormal head position, cosmetic problems and hypertropia due to superior oblique muscle paralysis. Hyperdeviation at primary gaze or IOOA at adduction were accepted as failure criteria.

Preoperative and postoperative (at the end of 2nd day, 1st week, 1st month, 3rd month and 6th month) macular thickness measurements were made by Spectral OCT/SLO (Opko/OTI Miami, FL) device which provides imaging with a resolution of $512 \times 64 \mu\text{m}$ at the fixation area of 9×9 mm. In patients with eccentric fixation, imaging and measurements were carried out by providing pupillary dilation. In these cases, centralized screening was performed as much as possible. Subsequently, the center was set on the fovea manually. Macular thickness was measured quantitatively at central macula, 1 mm in diameter, para-foveolar area, 3 mm in diameter which surrounds the central area and includes superior, inferior, temporal and nasal quadrants, peri-foveolar area, 6 mm in diameter. Thickness was determined as average of the four quadrants in para-foveolar and peri-foveolar areas.

Data were analyzed with PASW 18 (SPSS/IBM, Chicago, IL, USA). To define the sample, descriptive statistics such as frequency distribution, mean values and standard deviation were used. To analyze the different timed repeated measurements of macular thickness variable, analysis of variance (repeated measures design) was used. In the analysis, 95% significance level (or margin of error $\alpha=0.05$) was adopted to identify differences. P value less than 0.05 was considered statistically significant.

SURGICAL PROCEDURES

Operations were performed under general anesthesia. Eye was brought to the elevation in adduction by applying traction to the inferior temporal quadrant of the limbus with 5/0 silk su-

ture (Figure 1.1). Conjunctiva and tenon were cut and dissected at inferior - temporal quadrant, 8 mm from the limbus. Curvature of the inferior oblique muscle was observed and tenon was perforated from the upper edge. Muscle was hold with crochet and taken out of the incision to check completely grasped (Figure 1.2). By pulling the tenon with a second crochet, scleral adhesion area of the muscle was directly observed and tenotomy was performed (Figure 1.3). Traction tests have been done to make sure that the posterior muscle fibers left. Pushed the muscle into tenon, easy repositioning was observed. In patients who were retracted or did not tend to easy repositioning, tip of the muscle was resected of 5 mm and the muscle was pushed back into the tenon (Figure 1.4). After achieving easy repositioning and obtaining neces-

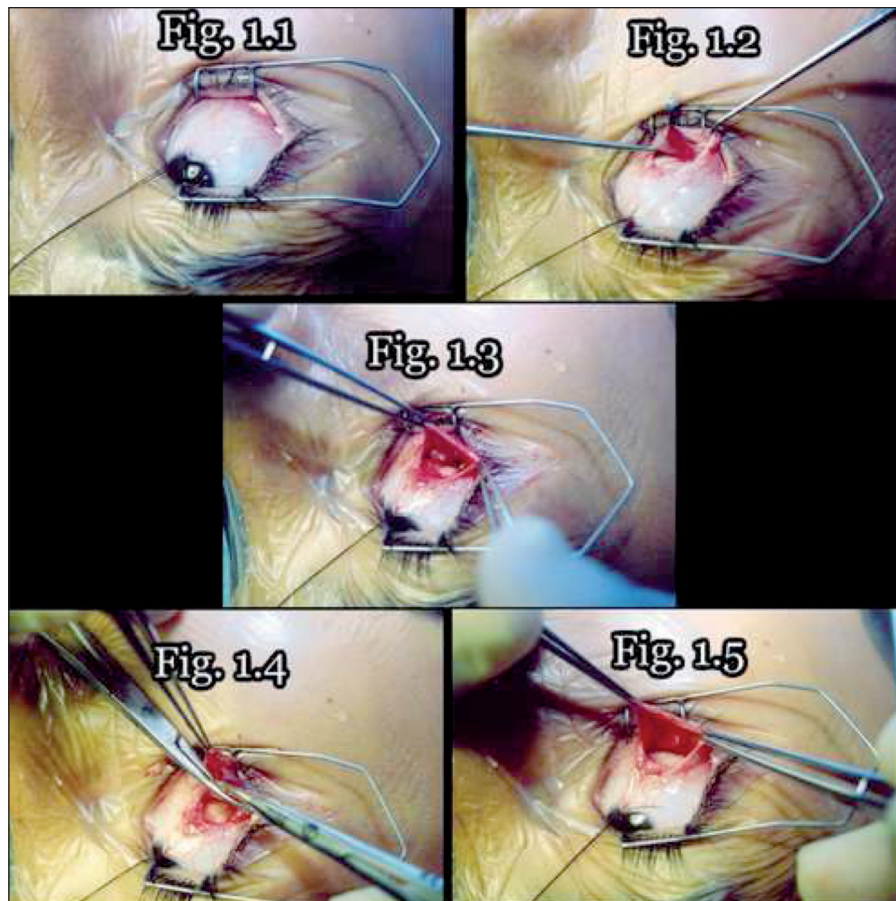


FIGURE 1: 1. Surgical Procedures; **Figure 1.1:** Elevation of the eye in adduction; **Figure 1.2:** Capture of the inferior oblique muscle; **Figure 1.3:** Muscle retraction after the disinsertion of the inferior oblique muscle; **Figure 1.4:** Distal muscle resection; **Figure 1.5:** Loss of the retraction after muscle resection.

sary hemostasis, operation has been ceased (Figure 1.5). Incisions were sutured with 7/0 vicryl in necessary cases. Horizontal deviation, if any, was also corrected at the same session.

In the postoperative period, all examinations together with OCT measurements were repeated periodically. Identifiable complications, IOOA or inferior oblique muscle hypofunctions and the amounts of horizontal deviation were noted.

RESULTS

Totally twenty seven eyes from 20 patients, including 14 men (70%) and 6 women (30%), were examined in our study. Mean age of the patients was 10.65±5.9 years (5-27 years) and the mean follow-up duration was 13.75±5.6 months (6-24 months). Demographic data of patients are seen in (Table 1).

In cycloplegic refraction measurements, hypermetropia was found in all cases (average refraction+1.50±1 D). No refraction change was detected between pre- and post-operative measurements of the cases. Likewise, the visual acuity of patients did not change after the operation. The number of patients with primary and secondary IOOA was found to be 11 (55%) and 9 (45%) respectively. In 7 patients (63.6%) with primary IOOA, the disorder was observed bilaterally. In 7 of 9 patients with secondary IOOA, abnormal head position was determined. In all these cases, Bielschowsky head tilt test was positive. The patients showed improvement in head position during the postoperative period and follow-up. IOOA was accompanied with esotropia in 6 patients (30%), exotropia in 3 patients (15%) and hypertropia in 6 patients (30%) (Table 2). Preoperative IOOA degrees of 27 operated eyes were +4 in 22 eyes,+3 in 4 eyes. The mean preoperative IOOA degree was found to be + 3.7. While postoperative overaction did not observed in 21 eyes, IOOA degree was found as +1 in 5 eyes and +2 in 1. Operation success rate was 77.8% (Table 3).

There were no complications during surgery. In the postoperative period; morphological changes such as macular hole, pseudo-hole, loss of foveolar

depression, retinal detachment and posterior vitreous detachment were not detected.

There were no statistically significant differences between preoperative and postoperative (at the end of 2nd day, 1st week, 1st month, 3rd month and 6th month) macular thickness measurements at foveolar, para-foveolar and peri-foveolar areas (Figure 2). The mean values of totally six preoperative and postoperative macular thickness measurements are given in (Table 4).

DISCUSSION

IOOA can be seen with congenital or acquired strabismus characterized by extreme elevation in adduction and it is usually common in 1-3 years, but it may also occur at any time in the first few years.² Although disinsertion+ distal muscle resection+ tucking method, applied in our study, is a simple, effective, easy to learn and advantageous procedure because of the controlled and short bleeding time; it can create dissection around the macula and cause serious complications such as adherence syndrome.⁴

TABLE 1: Gender, mean age and the follow-up duration.

Gender (man/woman)	14 (70%) /6 (30%)
Mean age (year)	10.65±5.9 years (5-27 years)
Average follow-up duration (month)	13.75±5.6 months (6-24 months)

TABLE 2: IOOA and concomitant shift.

Primary / secondary IOOA	11/9 55 %45%
Shift in the primary position	ortotropia: 5 (25%) esotropia: 6 (30%) exotropia: 3 (15%) hypertropia: 6 (30%)

TABLE 3: Pre- and postoperative IOOA degrees.

Preoperative IOOA degree	+ 4 overaction in 22 eyes + 3 overaction in 4 eyes + 2 overaction in 1 eyes
Postoperative IOOA degree	+ 2 overaction in 1 eye + 1 overaction in 5 eyes No overaction in 21 eyes

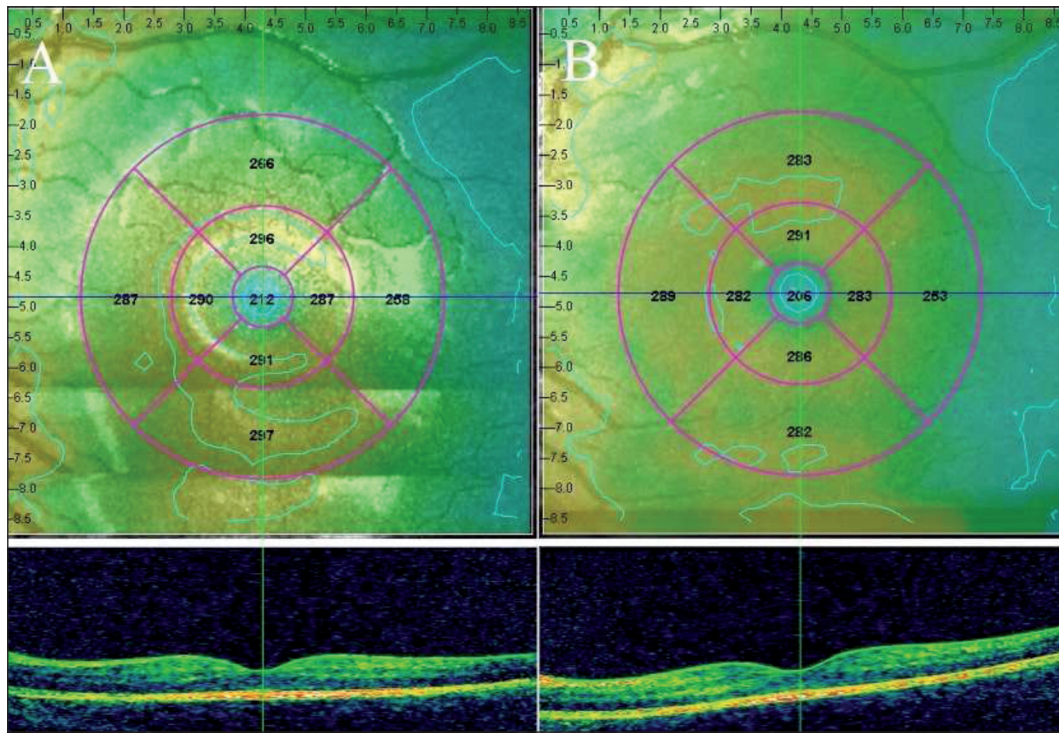


FIGURE 2: Preoperative and postoperative (6th month) OCT images of the case who underwent inferior oblique weakening surgery (A. preoperative, B. postoperative 6th month).

TABLE 4: Mean macular thickness.

	Preop	Postop 2 nd day	Postop 1 st week	Postop 1 st month	Postop 3 rd month	Postop 6 th month	P value
Central	203.5µ	205.2 µ	203.5 µ	203.3 µ	204.4 µ	202.4 µ	0.131
Para-foveolar	260.1 µ	265.7 µ	262.4 µ	263.4 µ	264.9 µ	263.5 µ	0.470
Peri-foveolar	279.3 µ	279.8 µ	282.1 µ	278.8 µ	280.0 µ	277.9 µ	0.197

Various studies indicate that, the most important issue in this surgery is the selection of the appropriate method due to the condition of the patient and the surgeon’s experience. Because each method has its own advantages and disadvantages. Processes applied to inferior oblique muscle weakening, except myectomy, are applied to the distal portion of the muscle. Inferior oblique muscle is the shortest muscle of the eye. During the weakening process, muscle separation by bringing the globe in adduction, elevation and traction by the mean of crochet; leads to traction on the adhesion area of the muscle over globe. In addition, the insertion patterns of the inferior oblique muscle vary widely.⁵⁻⁹ Yalcin et al. in their study carried out on 30 cadavers, reported that inferior oblique muscle had single connection to the

sclera in only 8.3% of the subjects while two or more binding points were existing in the remaining 91.7%.¹⁰ They also emphasized the need to a careful evaluation of the lower temporal quadrant of the sclera for not to miss different attachment points of the muscle during surgery. This assessment applied during surgery causes more traction on the muscle insertions. Insertion area of the muscle to globe shows close proximity to macula. Distance of the muscle insertion’s rear boundary from the fovea is only 2.5 mm.¹¹ Traction force generated on macula is potentially considered to damage it, and retinal tears and macular hole developments may occur especially in the elderly and patients with high myopia.³

The first use of OCT in strabismus was in comparison of macular and retinal nerve fiber layer

thickness of amblyopia with normal eye and it was underlined that central macular thickness increases but retinal nerve fiber layer shows no change especially in anisometropic amblyopia.^{12,13}

Kasem and Sabry, in their study on 16 cases, evaluated the results of traction forces generated on the macula during inferior oblique muscle surgery by OCT thickness analysis at the 1st day, 1st week and 1st month. They indicated that there was no increase in macular thickness and standard weakening procedures show no harmful effects to macula.¹⁴ The surgical technique used in our study, varies from the standard weakening procedures. Pushing action applied to the root portion of the muscle during surgery, can cause an additional trauma on macular region through sclera. This procedure may contribute some changes in the formation of macula in a long term.

Mintz et al. evaluated macular thickness in 30 patients undergoing all strabismus surgery.¹⁵ They were performed OCT one day prior to surgery and one day postoperatively. The authors found sub-clinical increases in the foveal and perifoveal macular thicknesses following extraocular muscle surgery and advocated that these findings could be attributed to change in the mechanical forces caused by the new position of the extraocular muscles and transmitted via the sclera or, alternatively, to postoperative inflammation and alterations in the blood-retinal barrier. In another article evaluated macular thickness and choroidal thickness by enhanced depth imaging spectral domain OCT in 24 patients with IOOA. When the patients with IOOA were assigned to two distinct groups according to the degree of IOOA, the macular thickness did not differ between groups (P=0.66), whereas subfoveal choroidal thickness measures were significantly lower in eyes with severe IOOA compared to eyes of the controls (P=0.01). The authors advocated that IOOA has no effect on the morphology and the thickness of the macula but severe IOOA seems to be related to thinning of subfoveal choroid due to possible external mechanical effect.¹⁶ Unlike previous study, in our study OCT thicknesses were evaluated also at 3th and 6th

months, so long-term effects on macula were also monitored. No increase in macular thickness was observed in OCT macular thickness analysis. The lack of advanced age and high myopia may have contributed to these results.

CONCLUSION

Successes, complications and especially their effects on macula of the surgical techniques applied to the patients with IOOA were examined in our study. The aim of the study was highlighting the advantages and disadvantages of the technique and to enable further comparative studies. Although more and larger studies needed to reveal the long-term results, we concluded that disinsertion of the inferior oblique muscle + distal muscle resection+ tucking procedure for IOOA treatment is a safe, simple and effective method which does not damage the macula.

Informing

Due to the presence of the name of the journal editor's among the authors, the assessment process of the study was conducted by the guest editor.

Source of Finance

During this study, no financial or spiritual support was received neither from any pharmaceutical company that has a direct connection with the research subject, nor from a company that provides or produces medical instruments and materials which may negatively affect the evaluation process of this study.

Conflict of Interest

No conflicts of interest between the authors and / or family members of the scientific and medical committee members or members of the potential conflicts of interest, counseling, expertise, working conditions, share holding and similar situations in any firm.

Authorship Contributions

Idea/Concept: Yaşar Duranoğlu; **Design:** Yaşar Duranoğlu; **Control/Supervision:** Yaşar Duranoğlu, Abdulkadir Alış; **Data Collection and/or Processing:** Mehmet Erkan Doğan; **Analysis and/or Interpretation:** Mehmet Erkan Doğan, Abdulkadir Alış; **Literature Review:** Mehmet Erkan Doğan; **Writing the Article:** Mehmet Erkan Doğan; **Critical Review:** Yaşar Duranoğlu; **References and Fundings:** Yaşar Duranoğlu; **Materials:** Abdulkadir Alış.

REFERENCES

1. von Noorden GK. Binocular Vision and Ocular Motility: Theory and Management of Strabismus. 6th ed. Cyclovertical Deviations. St Louis: Mosby; 2002. p.377-95.
2. Wilson ME, Parks MM. Primary inferior oblique overaction in congenital esotropia, accommodative esotropia, and intermittent exotropia. *Ophthalmology*. 1989;96(7):950-5. [[Crossref](#)]
3. El Massri A. Relation of macular and other holes to the insertin of the inferior oblique. *Br J Ophthalmol*. 1963;47:90-4. [[Crossref](#)] [[PubMed](#)] [[PMC](#)]
4. Duranoglu Y, Yücel I, Kivrakdal S. [The results of classical and combined inferior oblique muscle tenotomy]. *Turkiye Klinikleri J Ophthalmol*. 2003;12(3):145-50.
5. Isenberg S. Inferior oblique weakening procedures: technique and indications. In: Rosenbaum A, Santiago P, eds. *Clinical Strabismus Management: Principles and Surgical Techniques*. 1st ed. Philadelphia: Saunders; 1999. p.449-57.
6. Dyer JA. Tenotomy of the inferior oblique muscle at its scleral insertion. An easy and effective procedure. *Arch Ophthalmol*. 1962;68:176-81. [[Crossref](#)] [[PubMed](#)]
7. Davis G, McNeer KW, Spencer RF. Myectomy of the inferior oblique muscle. *Arch Ophthalmol*. 1986;104(6):855-8. [[Crossref](#)] [[PubMed](#)]
8. Del Monte MA, Parks MM. Denervation and extirpation of the inferior oblique. An improved weakening procedure for marked overaction. *Ophthalmology*. 1983;90(10):1178-85. [[Crossref](#)]
9. Elliott RL, Nankin SJ. Anterior transposition of the inferior oblique. *J Pediatr Ophthalmol Strabismus*. 1981;18(3):35-8.
10. Yalçın B, Ozan H. Insertional pattern of the inferior oblique muscle. *Am J Ophthalmol*. 2005;139(3):504-8. [[Crossref](#)] [[PubMed](#)]
11. Feng X, Pilon K, Yaacobi Y, Olsen TW. Extraocular muscle insertions relative to the fovea and optic nerve: humans and rhesus macaque. *Invest Ophthalmol Vis Sci*. 2005;46(10):3493-6. [[Crossref](#)] [[PubMed](#)]
12. Al-Haddad CE, Mollayess GM, Cherfan CG, Jaafar DF, Bashshur ZF. Retinal nerve fibre layer and macular thickness in amblyopia as measured by spectral-domain optical coherence tomography. *Br J Ophthalmol*. 2011;95(12):1696-9. [[Crossref](#)] [[PubMed](#)]
13. Andalib D, Javadzadeh A, Nabai R, Amizadeh Y. Macular and retinal nerve fiber layer thickness in unilateral anisometric or strabismic amblyopia. *J Pediatr Ophthalmol Strabismus*. 2013;50(4):218-21. [[Crossref](#)] [[PubMed](#)]
14. Kasem MA, Sabry D. Detection of macular changes by optical coherence tomography after inferior oblique muscle surgery. *J AAPOS*. 2011;15(4):334-7. [[Crossref](#)] [[PubMed](#)]
15. Mintz HR, Waisbourd M, Kessner R, Stolovitch C, Dotan G, Neudorfer M. Macular thickness following strabismus surgery as determined by optical coherence tomography. *J Pediatr Ophthalmol Strabismus*. 2016;53(1):11-5. [[Crossref](#)] [[PubMed](#)]
16. Ersan I, Oltulu R, Altunkaya O, Satirtav G, Arikan S, Donbaloglu M, et al. Relationship of inferior oblique overaction to macular and subfoveal choroidal thickness. *J AAPOS*. 2015;19(1):21-3. [[Crossref](#)] [[PubMed](#)]