

# Retropharyngeal Abscess as a Potentially Mortal Complication of Tonsillitis: Case Report

## Tonsillitin Olası Ölümcül Bir Komplikasyonu Olarak Retrofaringeal Abse

Murat GÜMÜŞSOY,<sup>a</sup>  
İbrahim ÇUKUROVA<sup>a</sup>

<sup>a</sup>Clinic of Otolaryngology and Head and Neck Surgery, İzmir Tepecik Training and Research Hospital, İzmir,

Geliş Tarihi/Received: 18.03.2013  
Kabul Tarihi/Accepted: 27.10.2013

Yazışma Adresi/Correspondence:  
Murat GÜMÜŞSOY  
İzmir Tepecik Training and Research Hospital,  
Clinic of Otolaryngology and Head and Neck Surgery, İzmir,  
TÜRKİYE/TURKEY  
mgumusoy@hotmail.com

**ABSTRACT** Retropharyngeal abscess is an uncommon, potentially fatal condition found more frequently in children than adults. Its progression may lead to sudden and fatal upper respiratory tract obstruction; it can either progress asymptotically or can mimic the signs of other conditions. In this respect, retropharyngeal abscess is an emergency condition that must be considered in the differential diagnosis in children. Early diagnosis and surgical treatment prevent the occurrence of severe complications such as mediastinal spread, pus aspiration, airway obstruction and large vessel erosion. Herein, we present a case of retropharyngeal abscess as a complication of acute tonsillitis who underwent emergency tracheotomy following acute respiratory distress.

**Key Words:** Tonsillitis; retropharyngeal abscess; tracheotomy; pneumonia

**ÖZET** Retrofaringeal apse çocukluk döneminin nadir görülen fakat ciddi komplikasyonlara yol açabilmesiyle de ölümcül olabilen bir derin boyun enfeksiyonudur. Ani ve ölümcül üst solunum yolu tıkanıklığına yol açabilir, belirti vermeksizin seyredildiği gibi farklı bulguları da taklit edebilir. Bu açıdan çocukluk döneminde ayırıcı tanıda mutlaka düşünülmesi gereken acil bir durumdur. Erken tanı ve cerrahi tedavi, mediastinal yayılım, püyo aspirasyonu, hava yolu obstrüksiyonu veya büyük damar erozyonu gibi ciddi komplikasyonların ortaya çıkmasını önler. Bu yazıda, akut tonsillit zemininde gelişen akut solunum sıkıntısı sonrasında acil trakeotomi açılan bir retrofaringeal apse, tanımlı olgudan bahsedilecektir.

**Anahtar Kelimeler:** Tonsillit; retrofaringeal apse; trakeotomi; pnömoni

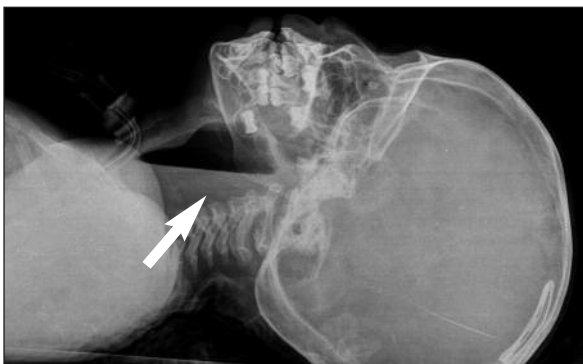**Türkiye Klinikleri J Case Rep 2013;21(4):204-7**

Retropharyngeal area is the region between medial and deep layers of deep cervical fascia extending to the posterior aspect of larynx. This potential region extends from the base of the skull to the mediastinum. Infections in the neck area may spread to the chest and mediastinum particularly through this region. Trauma to the upper esophagus or pharynx due to foreign body, and as well as upper respiratory tract infections may result in retropharyngeal abscess by suppuration of retropharyngeal lymph nodes.<sup>1,2</sup>

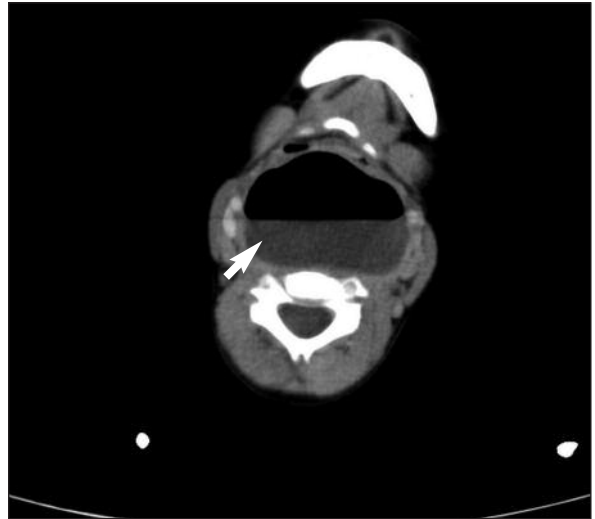
The present paper reports a 3-year-old girl who presented with fever, sore throat, and respiratory distress and underwent emergency tracheotomy followed by drainage of the retropharyngeal abscess.

## CASE REPORT

A 3-year-old girl presented to an outpatient clinic with the complaints of fever and sore throat. During the anamnesis, her family reported that she had been diagnosed with cryptic tonsillitis and treated with oral amoxicillin-clavulanate for the first three days. Then, intramuscular administration of cephalazolin was commenced as her complaints did not relieve. During the follow-up period, she was referred to our hospital due to respiratory distress. She was admitted to the emergency pediatrics clinic based on advanced respiratory distress and poor general status, and she underwent emergency tracheotomy as she could not be intubated. Airway control of the patient was maintained. The physical examination at the time of admittance revealed that her general status was poor, she was agitated, her body temperature was 38.2°C, pulse rate was 110/min, blood pressure was 90/65 mmHg, and respiratory rate was 22/min. Hematologic examination revealed white blood cell count of 23,600/mL (3,500 to 10,500 cells/mcL), hemoglobin level of 10.3 g/dL, thrombocyte count of 548,000/mL (150,000 to 450,000/mmol), CRP level of 19.3 mg/dL (less than 1.0 milligrams per liter, or mg/L), and predominance of segmented neutrophils. Inspection of the oropharynx revealed swelling on posterior pharyngeal wall and complete obliteration of pharyngeal air column. Lateral plain neck radiograph and neck computed tomography (CT) demonstrated an image consistent with retropharyngeal abscess, which seriously obliterated the upper airway (Figure 1, 2). The case was emergently

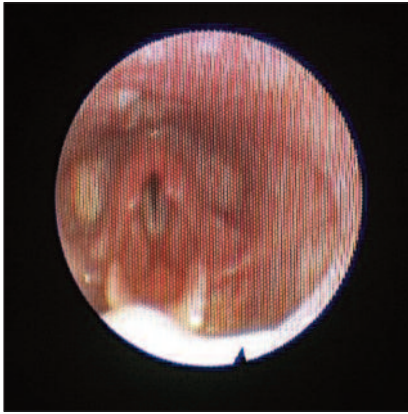


**FIGURE 1:** A view of preoperative lateral cervical radiograph (white arrow shows the retropharyngeal abscess).



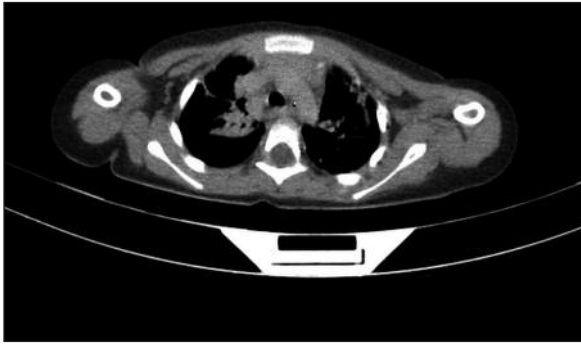
**FIGURE 2:** A preoperative computerized tomography scan of the neck (white arrow shows the retropharyngeal abscess).

admitted to the surgery room for abscess drainage. A fluctuating mass was observed in the midline extending towards to the posterior wall of hypopharynx. After the abscess was detected, it spontaneously ruptured during preparation period for drainage. The abscess, which was 4x5 cm in size arising from the posterior pharyngeal wall at the level of oropharynx and extending to the uvula and base of the tongue, was drained through vertical incision under general anesthesia as the patient was in trendelenburg position. Profuse, green-yellow colored pus with bad odor was drained. Samples were obtained from the pus and from the blood of the patient for aerobic and anaerobic cultures. *Streptococcus anginosus* was grown in both cultures. The patient was transferred to the pediatric intensive care unit after drainage. Her control CT scan of the neck taken one day later revealed that the abscess was regressed. Endoscopic inspection revealed a completely normal upper respiratory tract and an open airway (Figure 3). However, signs of aspiration pneumonia were determined on the postoperative (p.o) 2<sup>nd</sup> day (Figure 4). The patient was administered parenteral antibiotherapy from the p.o 1 day including 100 mg/kg ceftriaxone every 12 hours, 90 mg/kg vancomycin every 6 hours, and 15 mg/kg clindamycin every 12 hours. The patient was treated in the intensive care unit for 7 days and then transferred to the ward. Leuko-



**FIGURE 3:** Postoperative endoscopic view.

(See color figure at <http://www.turkiyeklinikleri.com/journal/turkiye-klinikleri-journal-of-case-reports/1300-0284/tr-index.html>)



**FIGURE 4:** A view of aspiration pneumonia on thoracic computerized tomography after surgery.

cytosis level, which regressed to 14,000/mL on the p.o 2<sup>nd</sup> day, was increased up to 19,000/mL on the p.o 9<sup>th</sup> day due to pneumonia. Leukocytosis level regressed to 9,800/mL on the p.o 16<sup>th</sup> day. CRP regressed to 9.14 mg/dL on the p.o 2<sup>nd</sup> day and to 2.33 mg/dL on the p.o 16<sup>th</sup> day. The patient received ceftriaxone and clindamycin for 16 days. Vancomycin therapy was continued for up to the p.o 24<sup>th</sup> day. The patient's clinical signs were improved and decannulated on the p.o 16<sup>th</sup> day.

## DISCUSSION

Retropharyngeal area includes two paramedial lymph node chains, into which nasal, paranasal sinuses, nasopharynx and adenoid drainage occurs. Retropharyngeal abscess can develop due to extension to the retropharyngeal area or to the involvement of retropharyngeal lymphatics in the event

of acute infection of head-neck region. Injury of oropharynx due to foreign body is an important way for the pathogens to enter directly into this area. Blunt traumas of the neck, oro-tracheal intubations and endoscopic procedures can also play important roles in etiology.<sup>3-5</sup> Although retropharyngeal abscess is a rare condition, it is common in childhood. It has been reported that more than 95% of retropharyngeal abscesses occur in the children under the age of 6 years.<sup>4,6</sup> The present patient case was a 3-year-old girl.

Suppuration in the lymph nodes following upper respiratory tract infections in the children is one of the most common causes of retropharyngeal abscesses. Retropharyngeal lymph node atrophy after 4-5 years of age has been reported as the reason for the disease being more common in childhood.<sup>5,6</sup> Consistent with the literature in terms of etiology, anamnesis of the present case revealed upper respiratory tract infection and high body temperature that had begun a week ago.

The most common symptoms of retropharyngeal abscesses include fever, neck swelling, dysphagia and respiratory distress.<sup>2</sup> Fever and advanced respiratory distress were the most significant symptoms of our case. Retropharyngeal abscesses can be diagnosed by radiologic and physical examinations. The rate of accurate diagnosis can reach up to 88% by soft tissue lateral neck radiograph, particularly in suspected cases.<sup>3,6-8</sup> Retropharyngeal soft tissue thickening, which narrows pharyngeal air column from the posterior or occasionally the air bubbles, can be seen on these radiographs. However, the definite diagnosis is made by CT and endoscopic examination. CT and endoscopic examination are the important auxiliary methods to differentiate uvulitis, tracheitis, epiglottitis and croup diseases, as well as pathological conditions, which might present with mass in the retropharyngeal region (cystic hygroma, hemangioma, neuroblastoma, rhabdomyosarcoma, retropharyngeal goiter, cervical spine traumas and osteomyelitis) from retropharyngeal abscess.<sup>6-8</sup> Emergency lateral direct neck radiograph was substantially adequate to diagnose the present patient. The diagnosis was also confirmed by CT.

Head-neck region infections have been reported to be polymicrobial and that there is a complex combination consisting of aerobic, anaerobic and microaerophilic organisms.<sup>9</sup> *Staphylococcus aureus* and *Streptococcus pyogenes* are the most common aerobic microorganisms, whereas *Bacteroides*, *Peptostreptococcus* and *Fusobacterium* species are the most common anaerobic microorganisms grown in the cultures obtained from the retropharyngeal area and other infections of head-neck region.<sup>9,10</sup> In the present case, the growth of *Streptococcus anginosus* was observed both in the abscess and blood cultures. *Streptococcus anginosus*, which is defined as the bacterium of *Streptococcus milleri* group, has the same general characteristics with classical beta-hemolytic streptococci and causes various invasive infections. They are found in the normal flora of throat, nasopharynx, gingiva, vagina and gastrointestinal system; however, they are considered pathogen when isolated from sterile material. *Streptococcus milleri* group are isolated as the pathogenic agent from many samples including brain abscess, pulmonary abscess, blood, urine and pus.<sup>9-11</sup> Abscess drainage is the most important step of treatment. While the recovery rate of retropharyngeal abscess has been reported to be just 12% by antibiotherapy alone, it has been reported to be 88% by surgical treatment.<sup>5-8</sup> The present case underwent surgical drainage together with antibiotherapy. The most serious hazard of retropharyngeal abscesses and infections is a life threatening mediastinitis and related complications that result from the transition of infection from alar fascia to hazardous area.<sup>5-7</sup>

Moreover, retropharyngeal abscesses can cause jugular vein thrombosis and internal carotid artery erosion leading to an increase in mortality rate up to 80%<sup>7,8</sup>. Other retropharyngeal abscess-related complications include acute upper respiratory tract obstruction, septicemia, aspiration pneumonia, and empyema. In the present case, aspiration pneumonia developed; however, she recovered by the treatment without sequel.

Asphyxia which is caused by spontaneous rupture of abscess or the abscess's compressing the airways or extending to the mediastinum is a rare but serious complication of retropharyngeal abscess<sup>5-8</sup>. In the present case, the abscess extended from the oropharynx level to the larynx level and obstructed the upper respiratory tract; thus, the patient underwent tracheotomy. After the abscess was detected, it spontaneously ruptured during preparation period for drainage. Although drainage was performed far from laryngeal entrance and in appropriate position in order not to cause pulmonary complication, we failed to prevent the development of aspiration pneumonia.

In conclusion, retropharyngeal abscess is a pathology that should be kept in mind in the event of acute respiratory distress and toxic pictures following upper respiratory tract infections, particularly in the children, since it can cause life threatening severe complications. In outpatient clinics, one should be alert to complications in acute tonsillitis cases with inadequate clinical response to antibiotic therapy.

## REFERENCES

- Davis WL, Harnsberger HR, Smoker WR, Watanabe AS. Retropharyngeal space: evaluation of normal anatomy and diseases with CT and MR imaging. *Radiology* 1990;174(1):59-64.
- Tannebaum RD. Adult retropharyngeal abscess: a case report and review of the literature. *J Emerg Med* 1996;14(2):147-58.
- Heath LK, Peirce TH. Retropharyngeal abscess following endotracheal intubation. *Chest* 1977;72(6):776-7.
- Duman M. [Acute infections that are caused upper airway obstruction in children]. *Türkiye Klinikleri J Surg Med Sci* 2007;3(50):16-25.
- Hartmann RW. Recognition of retropharyngeal abscess in children. *Am Fam Physician* 1992;46(1):193-6.
- Shumrick KA, Sheft SA. Deep neck infections. In: Paparella MM, Shumrick DA, eds. *Otolaryngology*. 3<sup>rd</sup> ed. Philadelphia: WB Saunders; 1991. p.2545-63.
- Craig FW, Schunk JE. Retropharyngeal abscess in children: clinical presentation, utility of imaging, and current management. *Pediatrics* 2003;111(6 Pt 1):1394-8.
- Rotta AT, Wiryawan B. Respiratory emergencies in children. *Respir Care* 2003;48(3):248-58; discussion 258-60.
- Bartlett JG, Gorbach SL. Anaerobic infections of the head and neck. *Otolaryngol Clin North Am* 1976;9(3):655-78.
- Brook I. Microbiology of retropharyngeal abscesses in children. *Am J Dis Child* 1987;141(2):202-4.
- Jacobs JA, Pietersen HG, Stobberingh EE, Soeters PB. *Streptococcus anginosus*, *Streptococcus constellatus* and *Streptococcus intermedius*. Clinical relevance, hemolytic and serologic characteristics. *Am J Clin Pathol* 1995;104(5):547-53.